SIG · SOC · OBSTET · LOND ·
1859



618.06

067
42

DOMINA RERUM SAPIENTIA

Library
of the
Academy of Medicine,
Toronto.

2419

Presented by

J. Millman. Esq. M.D.
1915

Digitized by the Internet Archive
in 2010 with funding from
University of Toronto

http://www.archive.org/details/transactions42obst

OBSTETRICAL TRANSACTIONS.

VOL. XLII.

TRANSACTIONS

OF THE

OBSTETRICAL SOCIETY

OF

LONDON.

VOL. XLII.

FOR THE YEAR 1900.

WITH A LIST OF OFFICERS, FELLOWS, ETC.



EDITED BY
HERBERT R. SPENCER, M.D., SENIOR SECRETARY,
AND
PERCY BOULTON, M.D.

LONDON:
LONGMANS, GREEN, AND CO.
1901.

LIBRARY
NOV 2 1 2001
UNIVERSITY OF TORONTO

PRINTED BY ADLARD AND SON, BARTHOLOMEW CLOSE, E.C.

OBSTETRICAL SOCIETY OF LONDON.

OFFICERS FOR 1901.

PRESIDENT.	HORROCKS, PETER, M.D.
VICE-PRESIDENTS.	BYERS, JOHN W., M.A., M.D. (Belfast). DAKIN, WILLIAM RADFORD, M.D. PHILLIPS, JOHN, M.A., M.D. MALINS, EDWARD, M.D. (Birmingham).
TREASURER.	BLACK, JAMES WATT, M.D.
CHAIRMAN OF THE BOARD FOR THE EXAMINATION OF MIDWIVES.	DAKIN, W. R., M.D.
HONORARY SECRETARIES.	SPENCER, HERBERT R., M.D. ROUTH, AMAND, M.D.
HONORARY LIBRARIAN.	HANDFIELD-JONES, MONTAGU, M.D.
EX-OFFICIO MEMBERS OF COUNCIL.	OLDHAM, HENRY, M.D. (*Trustee and Past President*). WILLIAMS, Sir JOHN, Bart., M.D. (*Trustee and Past President*. PLAYFAIR, WILLIAM S., M.D. (*Past President*). GERVIS, HENRY, M.D. (*Past President*). GALABIN, ALFRED LEWIS, M.D. (*Past President*). DORAN, ALBAN, F.R.C.S. (*Ex-President*).
OTHER MEMBERS OF COUNCIL.	ADAMS, CHARLES EDMUND. BARBOUR, A. H. FREELAND, M.D. (Edinburgh). BLACKER, GEORGE FRANCIS, M.D. BOXALL, ROBERT, M.D. BRIGGS, HENRY, M.B. (Liverpool). CHAMPNEYS, FRANCIS HENRY, M.A., M.D. DICKINSON, THOMAS VINCENT, M.D. FOWLER, CHARLES OWEN, M.D. GOW, WILLIAM JOHN, M.D. GRIFFITH, W. S. ANDERSON, M.D. HERMAN, GEORGE ERNEST, M.B. LEWERS, ARTHUR H. N., M.D. LOMBE, THOMAS ROBERT, M.D. (Torquay). REID, WILLIAM LOUDON, M.D. (Glasgow). SINCLAIR, WILLIAM JAPP, M.D. (Manchester). STABB, ARTHUR FRANCIS, M.B., B.C. TAYLOR, JOHN WILLIAM, F.R.C.S. (Birmingham). WHITE, CHARLES PERCIVAL, M.B.

3419

STANDING COMMITTEES.

BOARD FOR THE EXAMINATION OF MIDWIVES.

CHAIRMAN. DAKIN, W. R., M.D.

BLACKER, GEORGE FRANCIS, M.D.
TARGETT, JAMES HENRY, M.B., M.S.
ROBERTS, CHARLES HUBERT, M.D.
GOW, WILLIAM JOHN, M.D.

EX-OFFICIO. HORROCKS, PETER, M.D., *President.*
SPENCER, HERBERT R., M.D., } *Hon. Secs.*
ROUTH, AMAND, M.D., }

LIBRARY COMMITTEE.

CULLINGWORTH, CHARLES JAMES, M.D.
DORAN, ALBAN, F.R.C.S.
EDEN, THOMAS WATTS, M.D.
TATE, WALTER W. H., M.D.

EX-OFFICIO. HORROCKS, PETER, M.D., *President.*
BLACK, J. WATT, M.D., *Treasurer.*
SPENCER, HERBERT R., M.D., } *Hon. Secs.*
ROUTH, AMAND, M.D., }
HANDFIELD-JONES, MONTAGU, M.D., *Hon. Lib.*

PUBLICATION COMMITTEE.

CHAMPNEYS, FRANCIS HENRY, M.A., M.D.
HERMAN, GEORGE ERNEST, M.B.
McCANN, FREDERICK JOHN, M.D.
PHILLIPS, JOHN, M.A., M.D.
STABB, ARTHUR FRANCIS, M.B.

EX-OFFICIO. HORROCKS, PETER, M.D., *President.*
DORAN, ALBAN, F.R.C.S., *Editor.*
SPENCER, HERBERT R., M.D., } *Hon. Secs.*
ROUTH, AMAND, M.D., }

FINANCE COMMITTEE.

WILLIAMS, Sir JOHN, Bart., M.D.
PHILLIPS, JOHN, M.A., M.D.
BOULTON, PERCY, M.D.
CULLINGWORTH, CHARLES JAMES, M.D.

EX-OFFICIO. HORROCKS, PETER, M.D., *President.*
BLACK, J. WATT, M.D., *Treasurer.*
SPENCER, HERBERT R., M.D., } *Hon. Secs.*
ROUTH, AMAND, M.D., }

HONORARY LOCAL SECRETARIES.

Jones, Evan	Aberdare.
Goss, T. Biddulph	Bath.
Malins, Edward, M.D.	Birmingham.
Furner, Willoughby	Brighton.
Lawrence, A. E. Aust, M.D.	Clifton.
Braithwaite, James, M.D.	Leeds.
Thompson, Joseph	Nottingham.
Walker, Thomas James, M.D.	Peterborough.
Walters, James Hopkins	Reading.
Keeling, James Hurd, M.D.	Sheffield.
Burd, Edward, M.D., C.M.	Shrewsbury.
Perrigo, James, M.D.	Montreal, Canada.
Takaki, Kanaheiro	Japan.

LIST OF PAST PRESIDENTS OF THE SOCIETY.

1859 EDWARD RIGBY, M.D.
1861 WILLIAM TYLER SMITH, M.D.
1863 HENRY OLDHAM, M.D.
1865 ROBERT BARNES, M.D.
1867 JOHN HALL DAVIS, M.D.
1869 GRAILY HEWITT, M.D.
1871 JOHN BRAXTON HICKS, M.D., F.R.S.
1873 EDWARD JOHN TILT, M.D.
1875 WILLIAM OVEREND PRIESTLEY, M.D.
1877 CHARLES WEST, M.D.
1879 WILLIAM S. PLAYFAIR, M.D.
1881 J. MATTHEWS DUNCAN, M.D., F.R.S.
1883 HENRY GERVIS, M.D.
1885 JOHN BAPTISTE POTTER, M.D.
1887 JOHN WILLIAMS, M.D.
1889 ALFRED LEWIS GALABIN, M.D.
1891 JAMES WATT BLACK, M.D.
1893 G. ERNEST HERMAN, M.B.
1895 F. H. CHAMPNEYS, M.A., M.D.
1897 CHARLES JAMES CULLINGWORTH, M.D.
1899 ALBAN DORAN, F.R.C.S.

REFEREES OF PAPERS FOR THE YEAR 1901

Appointed by the Council.

BLACK, J. WATT, M.D.
BLAND-SUTTON, J.
BOXALL, ROBERT, M.D.
CHAMPNEYS, F. H., M.A., M.D.
CULLINGWORTH, CHARLES JAMES, M.D.
DAKIN, WILLIAM RADFORD, M.D.
DORAN, ALBAN, F.R.C.S
GALABIN, ALFRED LEWIS, M.A., M.D.
HANDFIELD-JONES, MONTAGU, M.D.
HERMAN, G. ERNEST, M.B.
LEWERS, ARTHUR H. N., M.D.
MEREDITH, W. A., M.B., C.M.
PHILLIPS, JOHN, M.A., M.D.
PLAYFAIR, WILLIAM S., M.D.
WILLIAMS, Sir JOHN, Bart., M.D.

OBSTETRICAL SOCIETY OF LONDON.

TRUSTEES OF THE SOCIETY'S PROPERTY.

HENRY OLDHAM, M.D.
SIR JOHN WILLIAMS, BART., M.D.

HONORARY FELLOWS.

BRITISH SUBJECTS.

Elected

1899 HUTCHINSON, JONATHAN, F.R.C.S., F.R.S., LL.D., 15, Cavendish square, W.

1892 LISTER, The Right Honorable LORD, F.R.S., LL.D., 12, Park crescent, Portland place, W.

1899 OLDHAM, HENRY, M.D., F.R.C.P., Consulting Obstetric Physician to Guy's Hospital; Cannington, Boscombe, Bournemouth. *Vice-Pres.* 1859. *Council*, 1860. 1865-6. *Treas.* 1861-2. *Pres.* 1863-4. *Trans.* 1. *Trustee.*

1892 TURNER, SIR WILLIAM, F.R.S., Professor of Anatomy, University of Edinburgh; 6, Eton terrace, Edinburgh.

FOREIGN SUBJECTS.

Elected

1899 Budin, P., M.D., Professor, 4, Avenue Hoche, Paris. *Trans.* 1.

1900 Chadwick, James R., M.A., M.D., Physician for Diseases of Women, Boston City Hospital; Clarendon street, Boston, Massachusetts, U.S.

1895 Gusserow, Professor, Berlin.

1866 Lazarewitch, J., M.D., Professor Emeritus and Physician to the Maximilian Hospital; Spaskaja, 2, St. Petersburg. *Trans.* 3.

1899 Martin, A. E., M.D., Professor of Obstetrics and Gynæcology, Greifswald. *Trans.* 1.

1899 Olshausen, R. M., Professor, N. Artilleriestrasse 19, Berlin.

1899 Pinard, A. Professor, 10, Rue Cambacérés, Paris.

1872 Thomas, T. Gaillard, M.D., Professor of Obstetrics in the College of Physicians and Surgeons; 600, Madison avenue, New York.

1862 Virchow, Rudolf, M.D., Professor of Pathological Anatomy in the University of Berlin.

1895 von Winckel, Professor, Sonnenstrasse 16a, Munich.

ORDINARY FELLOWS.

1901.

Those marked thus (*) have paid the Composition Fee in lieu of further annual subscriptions.

Those marked thus (†) reside beyond the London Postal District.

The letters O.F. are prefixed to the names of the "Original Fellows" of the Society.

Elected

1898 Aarons, S. Jervois, M.D.Edin., 14, Stratford place, W.

1900 Abbott, Horatio White, L.R.C.P.Lond., 66, Jackson road, Holloway, N.

1890† Ackerley, Richard, M.B., B.S.Oxon., Croft House, The Hill, Surbiton.

1891 Adams, Charles Edmund, 227, Gipsy road, West Norwood, S.E. *Council*, 1901.

1884*†Adams, Thomas Rutherford, M.D., 119, North End, West Croydon. *Council*, 1894-7.

1890 Addinsell, Augustus W., M.B., C.M.Edin., M.R.C.P., Pathologist to the Chelsea Hospital for Women, 7, Upper Brook street, W. *Council*, 1898-1900. *Trans.* 1.

1895† Albrecht, John Adolph, L.R.C.P. & S.Edin., 343, The Cliff, Lower Broughton road, Manchester.

1893† Alcock, Richard, M.B., Burlington crescent, Goole.

1883*†Allan, Robert John, L.R.C.P.Ed., The Bungalow, Dulwich hill, Sydney, New South Wales.

1890† Allan, Thomas S., L.R.C.P. & S.Ed.

1873† Allen, Henry Marcus, F.R.C.P.Ed., 17, Palmeira square, Hove, Brighton.

1887 Ambrose, Robert, B.A., L.R.C.P. & S.Ed., 1, Mount place, Whitechapel road, E.

Elected

1875* Anderson, John Ford, M.D., C.M., 41, Belsize park, N.W. *Council*, 1882, 1898-9.

1899 Andrews, E. Collingwood, M.A., M.D.Cantab., 110, Finchley road, South Hampstead, N.W.

1899 Andrews, Henry Russell, M.D., B.S. and M.R.C.S. Lond., London Hospital, E.

1859 Andrews, James, M.D., 1, Prince Arthur road, Hampstead N.W. *Council*, 1881.

1870*† Appleton, Robert Carlisle, The Bar House, Beverley.

1884 Appleton, Thomas A., 46, Britannia road, Fulham, S.W.

1883† Archibald, John, M.D., 2, The Avenue, Beckenham.

1871 Argles, Frank, L.R.C.P.Ed., Hermon Lodge, Wanstead, Essex, E. *Council*, 1886-7.

1886 Ashe, William Percy, L.R.C.P.Lond., 17, Alexander square, S.W

1898† Auden, George A., M.D., B.C.Cantab., 76, Bootham, York.

1887 Bailey, Henry Frederick, The Hollies, Lee terrace, Lee, S.E.

1880† Balls-Headley, Walter, M.D., F.R.C.P., Lecturer on Obstetrics and Diseases of Women, University of Melbourne, 4, Collins street east, Melbourne, Victoria.

1869* Bantock, George Granville, M.D., Consulting Surgeon to the Samaritan Free Hospital; 12, Granville place, Portman square, W. *Council*, 1874-6. *Trans.* 2.

1886*† Barbour, A. H. Freeland, M.D.Edin., Lecturer on Midwifery and Diseases of Women, Edinburgh Medical School, 4, Charlotte square, Edinburgh. *Council*, 1898-1901.

1884† Barraclough, Robert W. S., M.D., Stockholme, Linton, road, Hastings,

1896 Barrett, Sidney Edward, M.B., B.C.Cantab., 56, Manor road, Stoke Newington, N.

1886† Barrington, Fourness, M.B.Edin., F.R.C.S.Eng., 213, Macquarie street, Sydney, New South Wales.

Elected

1891 Barton, Edwin Alfred, L.R.C.P.Lond., 35, Cheniston Gardens, Kensington, W.

1887† Barton, William Edwin, L.R.C.P.Lond., Staunton-on-Wye, near Hereford.

1861*†Bartrum, John S., F.R.C.S., Surgeon to the Bath General Hospital; 13, Gay street, Bath. *Council*, 1877-9.

1893† Batchelor, Ferdinand Campion, M.D. Durh., Dunedin, New Zealand.

1873 Bate, George Paddock, M.D., 412, Bethnal Green road, N.E.; and 2, Northumberland Houses, King Edward road, Hackney. *Council*, 1882-4.

1895† Beachcroft, Francis Seward, L.R.C.P.Lond., The Chains, Petworth, Sussex.

1871 Beadles, Arthur, Park House, Dartmouth Park, Forest hill, S.E.

1892 Beauchamp, Sydney, M.B., B.C.Cantab., 95, Cromwell road, S.W.

1896 Belben, Frank, M.B., F.R.C.S., Endsleigh, Suffolk road, Bournemouth.

1866*†Belcher, Henry, M.D., 28, Cromwell road, West Brighton.

1899 Belfrage, Sydney Henning, M.B.Lond., 2, Montagu place, Montagu square, W.

1871*†Bell, Robert, M.D. Glasg., 29, Lynedoch street, Glasgow.

1889† Benson, Matthew, M.D.Brux., 35, Dicconson street, Wigan.

1894 Berkeley, Comyns, B.A., M.B., B.C.Cantab., Physician to Out-patients to Chelsea Hospital for Women; 53, Wimpole street, W.

1893† Berridge, William Alfred, Oakfield, Redhill.

1883† Bertolacci, J. Hewetson, Beaufort House, Knaphill, Surrey.

1889† Best, William James, 1, Cambridge terrace, Dover.

1893*†Betenson, William Betenson, L.R.C.P.Lond., Bungay, Suffolk.

Elected

1894* Betenson, Woodley Daniel, L.R.C.P.Lond., 26, Caversham road, N.W.

1891† Beville, Frederick Wells, L.R.C.P.Lond., 19, New Cavendish street, W.

1887*†Biden, Charles Walter, L.R.C.P.Lond., Laxfield, Framlingham.

1879 Biggs, J. M., Hillside, Child's hill, N.W.

1889† Bisshopp, Francis Robert Bryant, M.A., M.B., B.C. Cantab., Belvedere, Mount Pleasant, Tunbridge Wells.

1898 Blaber, Percy Leonard, L.R.C.P.Lond., Sunny Bank, Shoot-up hill, West Hampstead.

1890† Black, George, M.B., B.S.Lond., Hurstpierpoint, Hassocks, Sussex.

1868* Black, James Watt, M.A., M.D., F.R.C.P., Obstetric Physician to the Charing Cross Hospital; 15, Clarges street, Piccadilly, W. *Council*, 1872-4. *Vice-Pres.* 1885-6. *Chairman, Board Exam. Midwives*, 1887-90. *Pres.* 1891-2. *Treas.* 1898-1901.

1893 Blacker, George Francis, M.D., B.S.Lond., F.R.C.S., Assistant Obstetric Physician to University College Hospital; 11, Wimpole street, W. *Council*, 1898-1901. *Board Exam. Midwives*, 1900-1. *Trans.* 2.

1861*†Blake, Thomas William, M.D.St.And., Hurstbourne, Bournemouth, Hants.

1872*†Bland, George, Consulting Surgeon to the Macclesfield Infirmary; Pottergate Lodge, Lincoln.

1888* Bland-Sutton, John, F.R.C.S., Surgeon to the Middlesex Hospital; 48, Queen Anne street, Cavendish square, W. *Council*, 1894-5. *Trans.* 5.

1894 Bodilly, Reginald Thomas H., L.R.C.P.Lond., Woodbury, High road, South Woodford.

Elected

1883 Bonney, William Augustus, M.D., 100, Elm park gardens, Chelsea, S.W.

1900 Bonney, William Francis Victor, M.D., M.S.Lond., F.R.C.S.Eng., Chelsea Hospital for Women, S.W.

1894† Borcherds, Walter Meent, M.R.C.S., L.R.C.P., Cathcart, Cape Colony.

1866* Boulton, Percy, M.D., Physician to the Samaritan Free Hospital; 15, Seymour street, Portman square, W. *Council*, 1878-80, 1885, 1896. *Hon. Lib.* 1886. *Hon. Sec.* 1886-9. *Vice-Pres.* 1890-2. *Board Exam. Midwives*, 1890-1. *Chairman*, 1897-1900. *Editor*, 1894-1900. *Trans.* 4.

1886† Boustead, Robinson, M.D., B.C. Cantab., Lieutenant-Colonel, Indian Medical Service; c/o Messrs. H. S. King and Co., 45, Pall Mall, S.W.

1899 Bowie, Albert W., M.B., C.M.Edin., 41, Lauriston Place, Edinburgh.

1899† Bowring, Walter Andrew, F.R.C.S.Eng., 38, Montpelier crescent, Brighton.

1884* Boxall, Robert, M.D.Cantab., Assistant Obstetric Physician to, and Lecturer on Practical Midwifery at, the Middlesex Hospital; 40, Portland place, W. *Council*, 1888-90, 1894-5, 1899-1901. *Board Exam. Midwives*, 1891-3. *Trans.* 12.

1897 Boyd, John Stewart, L.R.C.P.Lond., Victoria House, Custom House, E.

1884† Boys, Arthur Henry, L.R.C.P.Ed., Chequer Lawn, St. Albans.

1886† Bradbury, Harvey K., 181, Horninglow street, Burton-on-Trent.

1877† Bradley, Michael McWilliams, M.B., Jarrow-on-Tyne.

1873† Braithwaite, James, M.D., Obstetric Physician to the Leeds General Infirmary; Lecturer on Diseases of Women and Children at the Leeds School of Medicine; 16, Clarendon road, Leeds. *Vice-Pres.* 1877-9. *Trans.* 6. *Hon. Loc. Sec.*

Elected

1880† Branfoot, Arthur Mudge, M.B., Rangoon, Burmah.

1887 Bridger, Adolphus Edward, M.D.Ed., 18, Portland place, W.

1888*†Briggs, Henry, M.B., F.R.C.S., Surgeon to the Hospital for Women, and Professor of Midwifery and Gynæcology, University College (Victoria University), Liverpool; 3, Rodney street, Liverpool. *Council*, 1901.

1894 Brinton, Roland Danvers, B.A., M.D.Cantab., 8, Queen's Gate terrace, S.W.

1869 Brisbane, James, M.D., 16, St. John's Wood road, N.W.

1887† Brodie, Frederick Carden, M.B., The Hutch, Sandown, Isle of Wight.

1892 Brodie, William Haig, M.D., C.M.Edin., F.R.C.S.Eng. Battle, Sussex.

1868 Brown, Andrew, M.D. St. And., 27, Lancaster road, Belsize park, N.W. *Council*, 1893-4. *Trans.* 1.

1894 Brown, David, M.D.Lond., Hamdon, Taunton.

1865* Brown, D. Dyce, M.D., 29, Seymour street, Portman square, W.

1898† Brown, Haydn, L.R.C.P.Edin., Buckhurst hill, Essex.

1896 Brown, John Lewis, M.B., C.M.Edin., 86, Windsor road, Forest gate, E.

1889*†Brown, William Carnegie, M.D.Aber., Glassaugh House, Portsoy, N.B.

1876 Brunjes, Martin, 270, Willesden lane, N.W.

1895† Buckley, Samuel, M.D.Lond., F.R.C.S.Eng., 2, Ebor villas, Broughton park, Manchester.

1883 Buksh, Rahlem, The Hall, Plaistow, E.

1885*†Bunny, J. Brice, L.R.C.P. Ed., Warre House, Bishop's Lydeard, Taunton.

Elected

1877† Burd, Edward, M.D., M.C., Senior Physician to the Salop Infirmary; Newport House, Shrewsbury. *Council*, 1886-7. *Hon. Loc. Sec.*

1894 Burt, Robert Francis, M.B., C.M.Edin., 124, Stroud Green road, N.

1888 Burton, Herbert Campbell, L.R.C.P. Lond., Lee Park Lodge, Blackheath, S.E.

1878 Butler-Smythe, Albert Charles, F.R.C.P. & S.Ed., Surgeon to Out-patients, Samaritan Free Hospital; 76, Brook street, Grosvenor square, W. *Council*, 1889-91.

1887* Buxton, Dudley W., M.D. Lond., 82, Mortimer street, Cavendish square, W.

1886† Byers, John W., M.A., M.D., M.A.O. (Hon. Causâ), Professor of Midwifery and Diseases of Women and Children at Queen's College, and Physician for Diseases of Women to the Royal Hospital, Belfast; Dreenagh House, Lower crescent, Belfast. *Vice-Pres.* 1899-1901.

1891† Calthrop, Lionel C. Everard, M.B. Durh., Gosberton House, 76, Jesmond road, Newcastle-on-Tyne.

1887† Cameron, James Chalmers, M.D., Professor of Midwifery and Diseases of Infancy, McGill University; 941, Dorchester street, Montreal.

1887† Cameron, Murdoch, M.D.Glas., Regius Professor of Midwifery in the University of Glasgow, 7, Newton terrace, Charing Cross, Glasgow.

1894† Campbell, John, M.A., M.D.Dubl., F.R.C.S., 21, Great Victoria street, Belfast.

1892 Campbell, John William, B.A., M.B., B.Ch.Cantab., Highclere, Oakleigh park, Whetstone, N. (*Winter*, Casa Rossa, Mentone.)

1888*† Campbell, William Macfie, M.D. Edin., 1, Princes gate East, Liverpool.

Elected

1886† Carpenter, Arthur Bristowe, M.A., M.B. Oxon., Wykeham House, Bedford park, Croydon.

1896 Carré, Louis G. E., M.D., The Uganda Relief Expedition, the 27th Bombay L. I. Regiment, Kampala, Uganda, Central Africa.

1887† Case, William, Denmark house, Caister-on-Sea, Norfolk.

1875† Chaffers, Edward, F.R.C.S., Broomfield, Keighley, Yorkshire.

1876* Champneys, Francis Henry, M.A., M.D. Oxon., F.R.C.P., Physician-Accoucheur to, and Lecturer on Midwifery at, St. Bartholomew's Hospital; 42, Upper Brook street, W. *Council*, 1880-1, 1900-1. *Hon. Lib.* 1882-3. *Hon. Sec.* 1884-7. *Vice-Pres.* 1888-90. *Board Exam. Midwives*, 1883, 1888-90; *Chairman*, 1891-5. *Editor*, 1888-93. *Pres.* 1895-6. *Trans.* 16.

1867*†Charles, T. Edmondston, M.D., F.R.C.P., 72, Via di San Niccolo da Tolentino, Rome. *Council*, 1882-4.

1874*†Charlesworth, James, M.D., Physician to the North Staffordshire Infirmary; 25, Birch terrace, Hanley, Staffordshire.

1890† Childe, Charles Plumley, B.A., F.R.C.S., Cranleigh, Kent road, Southsea.

1897† Chinery, Edward Fluder, F.R.C.S.Edin., Monmouth House, Lymington, Hants.

1863*†Chisholm, Edwin, M.D., Abergeldie, Ashfield, near Sydney, New South Wales. [Per Messrs. Turner and Henderson, care of Messrs. W. Dawson, 121, Cannon street, E.C.]

1896 Chittenden, T. Hillier, M.D.Durh., M.R.C.P.Lond., 32, Ovington square, S.W.

1883 Clapham, Edward, M.D., 29, Lingfield road, Wimbledon. *Council*, 1892-4.

Elected

1897 Clark, William Gladstone, M.A.Cantab., 6, Nicholas Street, Chester.

1893 Clarke, W. Bruce, F.R.C.S., Assistant Surgeon to St. Bartholomew's Hospital, 51, Harley street, W.

1899 Clayton, Charles Hollingsworth, L.R.C.P., 10, College terrace, Belsize park, N.W.

1889 Clemow, Arthur Henry Weiss, M.D., C.M. Edin., 101, Earl's Court road, Kensington, W.

1865*†Coates, Charles, M.D., Physician to the Bath General and Royal United Hospitals; 10, Circus, Bath.

1882† Coates, Frederick William, M.D., Auckland, New Zealand. *Council*, 1891-3.

1875* Coffin, Richard Jas. Maitland, F.R.C.P. Ed., 3, Westgate terrace, Redcliffe square, S.W.

1875*†Cole, Richard Beverly, M.D. Jefferson Coll. Philad., 218, Post street, San Francisco, California, U.S.

1895† Coles, Alfred Charles, M.D., C.M.Edin., Bradwardine, Branksome terrace, Bournemouth.

1897† Coles, Richard A., M.B. & C.M.Aber., Barham, near Canterbury.

1888† Collins, Edward Tenison, 12, Windsor place, Cardiff.

1866† Coombs, James, M.D., Bedford.

1888 Cooper, Peter, L.R.C.P.Lond., Stainton Lodge, 35 Shooter's Hill road, Blackheath, S.E.

1890 Copeland, William Henry Laurence, M.B.Cantab., 4, Bolton gardens, South Kensington, S.W.

1875*†Cordes, Aug., M.D., M.R.C.P., Consulting Accoucheur to the "Miséricorde;" Privat Docent for Midwifery at the University of Geneva; 12, Rue Bellot, Geneva. *Trans.* 1.

1883 Corner, Cursham, 113, Mile End road, E.

1877 Crawford, James, M.D. Durh., Grosvenor Mansions, Victoria street, S.W.

Elected

1896† Creasy, Rolf, L.R.C.P. Lond., Windlesham, Surrey.

1876† Crew, John, Manor House, Higham Ferrers, Northamptonshire.

1853 Cripps, William Harrison, F.R.C.S., Surgeon to St. Bartholomew's Hospital; 2, Stratford place, W. *Trans.* 1

1889† Croft, Edward Octavius, M.D.Durh., Hon. Surgeon to the Hospital for Women and Children; Hon. Demonstrator of Obstetrics to the Yorkshire College, Leeds; 8, Clarendon road, Leeds. *Trans.* 1.

1881*†Cronk, Herbert George, M.B. Cantab., Repton, near Burton-on-Trent.

1893 Crosby, Herbert Thomas, M.A., M.B., B.C.Cantab., 19, Gordon square, W.C.

1895 Cross, Ernest W., L.R.C.P.Lond., The Limes, Wallwood Park, Leytonstone.

1886*†Cross, William Joseph, M.B., Horsham, Victoria, Australia.

1898† Cullen, Thomas, M.D.Toronto, Johns Hopkins Hospital, Baltimore, U.S.A.

1875* Cullingworth, Charles James, M.D., D.C.L., F.R.C.P., Obstetric Physician to St. Thomas's Hospital; 14, Manchester square, W. *Council*, 1883-5, 1891-3. *Vice-Pres.* 1886-8. *Board Exam. Midwives*, 1889-91. *Chairman*, 1895-6. *Pres.* 1897-8. *Trans.* 13.

1889*†Cursetji, Jehángir J., M.D. Brux., 94, Chundunwádi, Bombay.

1894 Cutler, Lennard, L.R.C.P.Lond., 1, Kensington Gate, Kensington, W. *Trans.* 1.

1885 Dakin, William Radford, M.D., B.S., F.R.C.P., Obstetric Physician to, and Lecturer on Midwifery at, St. George's Hospital; 18, Grosvenor street, W.. *Council*, 1889-91. *Hon. Lib.* 1892-3. *Hon. Sec.* 1894-7. *Vice-Pres.* 1898-1901. *Chairman*, 1901. *Trans.* 3.

Elected

1868 Daly, Frederick Henry, M.D., 185, Amhurst road, Hackney Downs, N.E. *Council*, 1877-9. *Vice-Pres.* 1883-5. *Trans.* 2.

1893 Dauber, John Henry, M.A. Oxon., M.B., B.Ch., Physician to the Hospital for Women, Soho square; 29, Charles street, Berkeley square, W.

1901 Davies, Hughes Reid, L.R.C.P.Lond., 82, Bow road, E.

1892† Davis, Robert, Darrickwood, Orpington, Kent.

1877 Dawson, Smith Houston, M.D., Campden villa, 203, Maida vale, W. *Council*, 1889-91.

1900† Dawkin, George Mansell, L.R.C.P.Lond., Pontypridd, Glamorganshire.

1891 Dawson, Ernest, L.R.C.P.Lond., The Broadway, Leyton, E. *Trans.* 1.

1889 Des Vœux, Harold A., M.D.Brux., 8, James street, Buckingham gate, S.W. *Council*, 1896-8.

1894 Dickinson, Thomas Vincent, M.D.Lond., M.R.C.P., Assistant Physician to the Italian Hospital, Queen square; 33, Sloane street, S.W. *Council*, 1900-1.

1894 Dickson, John William, B.A., M.B., B.C. Cantab., 42, Hertford street, Mayfair, W.

1895 Dodgson, George Stanley, B.A., M.B., B.C.Cantab., Southleigh, Headingley, Leeds.

1886† Donald, Archibald, M.D. Edin., M.R.C.P., Obstetric Physician to the Royal Infirmary, Manchester; Honorary Surgeon to St. Mary's Hospital for Women, Manchester; Platt Abbey, Rusholme, Manchester. *Council*, 1893-5. *Trans.* 2.

1879* Doran, Alban H. G., F.R.C.S., Surgeon to the Samaritan Free Hospital; 9, Granville place, Portman square, W. *Council*, 1883-5. *Hon. Lib.* 1886-7. *Hon. Sec.* 1888-91. *Vice-Pres.* 1892-4. *Pres.* 1899-1900. *Trans.* 20.

1890† Douty, Edward Henry, M.A., M.B., B.C.Cantab., Davos Platz, Switzerland.

Elected

1887 Dovaston, Milward Edmund, Rosenan, St. George's road, Wimbledon.

1899† Down, Elgar, L.R.C.P.Lond., 14, Mount Edgcumbe terrace, Stoke, Devonport.

1896 Downes, J. Lockhart, M.B., C.M. Edin., 27, Romford road, E.

1884† Doyle, E. A. Gaynes, L.R.C.P., Colonial Hospital, Port of Spain, Trinidad.

1871† Drake-Brockman, Edward Forster, F.R.C.S., L.R.C.P. Lond., Brigade-Surgeon; c/o Messrs. Richardson and Co., East India Army Agency, 25, Suffolk street, Pall Mall, S.W.

1894† Drew, Henry William, F.R.C.S., Eastgate, East Croydon.

1883 Duncan, Alexander George, M.B., 25, Amhurst park, Stamford hill, N.

1882 Duncan, William, M.D., Obstetric Physician to, and Lecturer on Obstetric Medicine at, the Middlesex Hospital; 6, Harley street, W. *Council*, 1885-6, 1888-9. *Hon. Lib.* 1890-1. *Hon. Sec.* 1892-5. *Vice-Pres.* 1896-9. *Trans.* 2.

1871* Eastes, George, M.B., F.R.C.S., 35, Gloucester terrace, Hyde park, W. *Council*, 1878-80.

1896 Easton, Frank Edward, L.R.C.P. Lond., 12, Devonport street, Hyde park, W.

1883† Eccles, F. Richard, M.D., Professor of Gynæcology, Western University; 1, Ellwood place, Queen's avenue, London, Ontario, Canada.

1893 Eden, Thomas Watts, M.D.Edin., M.R.C.P.Lond., Assistant Obstetric Physician to, and Lecturer on Practical Midwifery at, Charing Cross Hospital, 26, Queen Anne street, W. *Council*, 1897-9. *Trans.* 4.

1890 Ehrmann, Albert, L.R.C.P.Lond., 6, The Terrace, Camden square, N.W.

Elected

1894 Ellis, Robert Kingdon, M.B., B.Ch.Oxon., Lowdham, Notts.

1873*†Engelmann, George Julius, A.M., M.D., 336, Beacon street, Boston, Mass., U.S.A.

1898† Evans, David J., M.D.McGill, 939, Dorchester street, Montreal.

1897 Evans, Evan Laming, M.B., B.C.Cantab., F.R.C.S., 116, Piccadilly, W.

1892† Evans, John Morgan, L.R.C.P.Lond., Llandrindod Wells, Radnorshire.

1875† Ewart, John Henry, Eastney, Devonshire place, Eastbourne.

1899 Fairbairn, John Shields, M.D., B.Ch.Oxon., 60, Wimpole street, W.

1894 Fairweather, David, M.A., M.D., C.M.Edin., Carlton Lodge, Palmerston road, Bowes Park, N.

1876† Farncombe, Richard, 183, Belgrave road, Balsall heath, Birmingham.

1869* Farquhar, William, M.D., Deputy Surgeon-General, 40, Westbourne gardens, Bayswater, W.

1882† Farrar, Joseph, M.D., Gainsborough. *Trans.* 1.

1894† Fazan, Charles Herbert, L.R.C.P. Lond., Belmont, Wadhurst, Sussex.

1868* Fegan, Richard, M.D., Westcombe park, Blackheath, S.E.

1886 Fennell, David, L.K.Q.C.P.I., "Castlebar," 116, Palace road, Tulse hill, S.W.

1883 Fenton, Hugh, M.D., Physician, Chelsea Hospital for Women; 27, George street, Hanover square, W.

1893 Ferguson, George Gunnis, M.B., C.M.Glas., Fern Combe, New West End, Finchley road, Hampstead, N.W.

Elected

1893† Finley, Harry, M.D.Lond., West Malvern, Worcestershire.

1877*†Fonmartin, Henry de, M.D., 26, Newberry terrace, Lower Bullar street, Nichols Town, Southampton.

1897† Fothergill, W. E., M.B., C.M.Edin., 10, St. John street, Manchester.

1884 Fouracre, Robert Perriman, 58, Tollington park, N.

1886† Fowler, Charles Owen, M.D., Cotford House, Thornton heath. *Council*, 1901.

1898 Frampton, Trevethan, M.R.C.S., F.R.C.P., 168, Gloucester terrace, Hyde park, W.

1875*†Fraser, Angus, M.D., Physician and Lecturer on Clinical Medicine to the Aberdeen Royal Infirmary; 232, Union street, Aberdeen. *Council*, 1897-1900.

1888† Fraser, James Alexander, L.R.C.P. Lond., Western Lodge, Romford.

1883 Fuller, Henry Roxburgh, M.D. Cantab., 45, Curzon street, Mayfair, W. *Council*, 1893. *Trans.* 1.

1886† Furner, Willoughby, F.R.C.S., 13, Brunswick square, Brighton. *Council*, 1894-6. *Hon. Loc. Sec.*

1874* Galabin, Alfred Lewis, M.A., M.D., F.R.C.P., Obstetric Physician to, and Lecturer on Midwifery at, Guy's Hospital; 49, Wimpole street, Cavendish square, W. *Council*, 1876-8. *Hon. Lib.* 1879. *Hon. Sec.* 1880-3. *Vice-Pres.* 1884. *Treas.* 1885-8. *Pres.* 1889-90. *Trans.* 12.

1888 Galloway, Arthur Wilton, L.R.C.P. Lond., 79, New North road, N.

1863* Galton, John H., M.D., Chunam, Sylvan road, Upper Norwood, S.E. *Council*, 1874-6, 1891-2. *Vice-Pres.* 1895-8.

1881 Gandy, William, Hill Top, Central hill, Norwood, S.E. *Council*, 1897-8.

Elected

1886*†Garde, Henry Croker, F.R.C.S. Edin., Maryborough, Queensland.

1887 Gardiner, Bruce H. J., L.R.C.P. Ed., Gloucester House, Barry road, East Dulwich, S.E.

1894 Gardner, H. Bellamy, M.R.C.S., L.R.C.P.Lond., 52, Beaumont street, Portland place, W.

1879† Gardner, John Twiname, Watersmeet, Ilfracombe.

1872*†Gardner, William, M.A., M.D., Professor of Gynæcology, McGill University; Gynæcologist to the Royal Victoria Hospital; 109, Union avenue, Montreal, Canada.

1876† Garner, John, 21, Easy row, Birmingham.

1891† Garrett, Arthur Edward, L.R.C.S. & L.M.Ed., Dalkeith House, Leamington.

1873*†Garton, William, M.D., F.R.C.S., Inglewood, Aughton, near Ormskirk.

1889* Gell, Henry Willingham, M.A., M.B.Oxon., 36, Hyde park square, W.

1898*†Gemmell, John Edward, M.B., C.M.Edin., Hon. Surgeon to the Hospital for Women, Liverpool; 12, Rodney street, Liverpool.

1859* Gervis, Henry, M.D., F.R.C.P., Consulting Obstetric Physician to St. Thomas's Hospital; The Towers, Hillingdon, Uxbridge. *Council*, 1864-6, 1889-91, 1893. *Hon. Sec.* 1867-70. *Vice-Pres.* 1871-3. *Treas.* 1878-81. *Pres.* 1883-4. *Trans.* 8.

1866* Gervis, Frederick Heudebourck, 1, Fellows road, Haverstock hill, N.W. *Council*, 1877-9. *Vice-Pres.* 1892. *Trans.* 1.

1899† Gervis, Henry, M.A., M.B., B.C.Cantab., 74, Dyke road, Brighton.

1883* Gibbons, Robert Alexander, M.D., Physician to the Grosvenor Hospital for Women and Children; 29, Cadogan place, S.W. *Council*, 1889-90. *Trans.* 1.

1894 Gibson, Henry Wilkes, L.R.C.P. Lond. 6, College terrace, Fitzjohn's avenue, N.W.

Elected

1874† Gibson, James Edward, Hillside, West Cowes, Isle of Wight.

1892 Giles, Arthur Edward, M.D. Lond., M.R.C.P., Physician to Out-patients, Chelsea Hospital for Women; 37, Queen Anne street, Cavendish square, W. *Council*, 1898-1900. *Trans.* 7.

1869 Gill, William, L.R.C.P. Lond., 11, Russell square, W.C.

1891 Gimblett, William Henry, M.D.Durh., Queen's road, Buckhurst hill, Essex.

1899† Glover, Thomas Anderson, M.D., C.M.Edin., 24, Hallgate, Doncaster.

1894† Goddard, Charles Ernest, L.R.C.P. Lond., Wembley, Harrow.

1871 *Godson, Clement, M.D., C.M.; 82, Brook street, W. *Council*, 1876-7. *Hon. Sec.* 1878-81. *Vice-Pres.* 1882-4. *Board Exam. Midwives*, 1877, 1882-86. *Trans.* 5.

1893† Goodman, Roger Neville, M.A., M.B.Cantab., Elmside, Kingston-on-Thames.

1893† Gordon, Frederick William, L.R.C.P.Lond., Manukau road, Auckland, New Zealand.

1883 Gordon, John, M.D., 63, Cheapside, E.C.

1869† Goss, Tregenna Biddulph, 1, The Circus, Bath. *Hon. Loc. Sec.*

1891† Gostling, William Ayton, M.D., B.S.Lond., Barningham, West Worthing.

1889 Goullet, Charles Arthur, L.R.C.P.Lond., 2, Finchley road, N.W.

1890 Gow, William John, M.D.Lond., Physician-Accoucheur in charge of Out-patients, St. Mary's Hospital; 27, Weymouth street, W. *Council*, 1893-5-1901. *Board Exam. Midwives*, 1898-1900-1. *Trans.* 2.

1893† Gowan, Bowie Campbell, L.R.C.P.Lond., Raven Dene, Great Stanmore.

Elected

1893 Grant, Leonard, M.D.Edin., 9, Western villas, New Southgate, N.

1897 Grant-Wilson, Charles Westbrooke, L.R.C.P.Lond., St. Winnows, Bromley, Kent.

1890 Green, Charles David, M.D.Lond., 16, Evelyn mansions, Carlyle place, Victoria street, S.W.

1894† Green, Charles Robert Mortimer, Captain, Indian Medical Service, The Eden Hospital, Calcutta.

1887 Greenwood, Edwin Climson, L.R.C.P., 19, St. John's wood park, N.W.

1863 *Griffith, G. de Gorrequer, 34, St. George's square, S.W. *Trans.* 2.

1879* Griffith, Walter Spencer Anderson, M.D. Cantab., F.R.C.S., F.R.C.P., Assistant Physician-Accoucheur to St. Bartholomew's Hospital; 96, Harley street, W. *Council*, 1886-8, 1893-5, 1901. *Hon. Lib.*, 1896-7. *Board Exam. Midwives*, 1887-9. *Trans.* 10.

1888*†Grimsdale, Thomas Babington, B.A., M.B. Cantab., Surgeon to the Hospital for Women, and Medical Officer to the Liverpool Lying-in Hospital; 29, Rodney street, Liverpool.

1882† Gripper, Walter, M.B. Cantab., The Poplars, Wallington, Surrey.

1880 Grogono, Walter Atkins, Berwick House, Broadway, Stratford, E.

1896† Groves, Ernest W., M.B., B.Sc., Kingswood, Bristol.

1887† Hackney, John, M.D. St. And., Oaklands, Hythe.

1881† Hair, James, M.D., Brinklow, Coventry.

1894 Hamilton, Bruce, L.R.C.P.Lond., "Falklands," 9, Frognal, N.W.

1887† Hamilton, John, F.R.C.S.Ed., Beechhurst House, Swadlincote, Burton-on-Trent.

Elected

1883 Handfield-Jones, Montagu, M.D. Lond., F.R.C.P., Physician-Accoucheur to, and Lecturer on Midwifery and Diseases of Women at, St. Mary's Hospital; 35, Cavendish square, W. *Council*, 1887-9, 1896-7. *Board Exam. Midwives*, 1894-6. *Hon. Lib.* 1900-1. *Trans.* 1.

1889† Hardwick, Arthur, M.D. Durh., Newquay, Cornwall.

1886† Hardy, Henry L. P., Stroud, Gloucestershire.

1892 Harold, John, L.R.C.P.Lond., 91, Harley street, W.

1889 Harper, Charles John, L.R.C.P. Lond., Church end, Finchley, N.

1877 Harper, Gerald S., M.B.Aber., 40, Curzon street, Mayfair, W. *Council*, 1894-5.

1898† Harper, John Robinson, L.R.C.P., 3, Union terrace, Barnstaple, Devon.

1878† Harries, Thomas Davies, F.R.C.S., Grosvenor House, Aberystwith, Cardiganshire.

1867* Harris, William H., M.D., 34, St. Charles square, North Kensington, W.

1880* Harrison, Richard Charlton, 19, Uxbridge road, Ealing, W.

1890† Hart, David Berry, M.D.Edin., Assistant Gynæcologist, Royal Infirmary, Edinburgh; 29, Charlotte square, Edinburgh.

1886† Hartley, Horace, L.R.C.P. Ed., Stone, Staffordshire.

1886 Hartley, Reginald, M.D. Durh., F.R.C.S.Ed., 63, Porchester terrace, Hyde park, W.

1891 Hartzhorne, Bernard Fred., M.R.C.S.

1893† Harvey, John Jordan, L.R.C.P. & S.Edin., 54, Barking road, Canning Town, E.

1880 Harvey, John Stephenson Selwyn, M.D.Durh., M.R.C.P., 1, Astwood road, Cromwell road, S.W.

1865*† Harvey, Robert, C.B., M.D.Aberd., Surgeon-General, I.M.S., Simla, India. *Trans.* 1.

Elected

1899† Hawes, Godfrey Charles Browne, L.R.C.P., Pangbourne.

1899*†Hawkes, Claude Somerville, L.R.C.P., Swansea place, Wickham Terrace, Brisbane, Queensland.

1892† Hawkins-Ambler, George Arthur, F.R.C.S.Ed., 67, Rodney street, Liverpool.

1893† Haydon, Thomas Horatio, M.B., B.C. Cantab., 22, High street, Marlborough.

1900 Hayford, Ernest James, M.D., Freetown, Sierra Leone, West Africa.

1880 Heath, William Lenton, M.D., 90, Cromwell road, Queen's gate, S.W. *Council*, 1891. *Trans.* 1.

1892† Hellier, John Benjamin, M.D.Lond., Lecturer on Diseases of Women and Children, Yorkshire College; Hon. Obstetric Physician to Leeds Infirmary; 27, Park square, Leeds.

1890† Helme, T. Arthur, M.D.Edin., M.R.C.P., Senior Assistant Surgeon to the Manchester Clinical Hospital for Women and Children, 3, St. Peter's square, Manchester.

1867† Hembrough, John William, M.D., The Moot Hall, Newcastle-on-Tyne.

1876* Herman, George Ernest, M.B., F.R.C.P., Obstetric Physician to, and Lecturer on Midwifery at, the London Hospital; 20, Harley street, Cavendish square, W. *Council*, 1878-9, 1898-1901. *Hon. Lib.* 1880-1. *Hon. Sec.* 1882-5. *Vice-Pres.* 1886-7. *Board Exam. Midwives*, 1886-8. *Treas.* 1889-92. *Pres.* 1893-4. *Trans.* 31.

1892† Hills, Thomas Hyde, L.R.C.P.Lond., 7, St. Peter's terrace, Cambridge.

1898 Hindley, Godfrey D., L.R.C.P.Lond., 31, Woburn place, Russell square, W.C.

1886† Hodges, Herbert Chamney, L.R.C.P.Lond., Watton-at-Stone, Herts. *Trans.* 1.

Elected

1886† Holberton, Henry Nelson, L.R.C.P.Lond., East Molesey.

1875 Hollings, Edwin, M.D., 22, Endsleigh gardens, N.W. *Council*, 1888-90. *Vice-Pres.* 1893-4.

1897 Hollings, Guy Bertram, M.D., B.S., 22, Endsleigh gardens, N.W.

1859 Holman, Constantine, M.D., 26, Gloucester place, Portman square, W. *Council*, 1867-9, 1895-6. *Vice-Pres.* 1870-1.

1891† Holman, Robert Colgate, Whithorne House, Midhurst, Sussex.

1864* Hood, Wharton Peter, M.D., 11, Seymour street, Portman square, W.

1896† Hopkins, George Herbert, F.R.C.S., 3, North Quay, Brisbane, Queensland.

1884 Hopkins, John, L.R.C.P.Ed., Hamlet Court road, West Cliff, Southend-on-Sea.

1883* Horrocks, Peter, M.D., F.R.C.P. Lond., Assistant Obstetric Physician to Guy's Hospital ; 42, Brook street, W. *Council*, 1886-7. *Hon. Lib.* 1888-9. *Hon. Sec.* 1890-3. *Vice-Pres.* 1894-6. *Pres.* 1901. *Trans.* 2.

1876 Horsman, Godfrey Charles, 22, King street, Portman square, W.

1883 Hoskin, Theophilus, L.R.C.P. Lond., 1, Amhurst park, N.

1883 Houchin, Edmund King, L.R.C.P. Ed., Ravensworth, Ilford, Essex.

1884† Hough, Charles Henry, Full street, Derby.

1879† Hubbard, Thomas Wells, Barming place, Maidstone.

884*†Hurry, Jamieson Boyd, M.D. Cantab., 43, Castle street, Reading. *Council*, 1887-9. *Vice.-Pres.* 1897-1900. *Trans.* 2.

1878* Husband, Walter Edward, Grove Lea, Lansdown, Bath.

Elected

1895 Huxley, Henry, L.R.C.P.Lond., 39, Leinster gardens, Hyde park, W.

1894† Ilott, Herbert James, M.D. Aber., 57, High street, Bromley, Kent.

1883† Inman, Robert Edward, Gadshill Cottage, Higham, Kent.

1884*†Irwin, John Arthur, M.A., M.D., 14, West Twenty-ninth street, New York.

1883† Jackson, George Henry, Ashburton, Carew road, Eastbourne.

1897 Jäger, Harold, M.B. Lond., 6, Darnley road, Royal crescent, W.

1873† Jakins, William Vosper, L.R.C.P. Ed., 14, Collins street East, Melbourne.

1890† James, Charles Henry, L.R.C.P.Lond., Captain, Indian Medical Service; Lahore, Punjab, India.

1895† James, Stanlake, Violet hill, Simla, India.

1883*†Jenkins, Edward Johnstone, M.D. Oxon., 213, Macquarie street, Sydney.

1877† Jenks, Edward W., M.D., 84, Lafayette avenue, Detroit, Michigan, U.S.

1882* Jennings, Charles Egerton, M.D. Durh., F.R.C.S. Eng., Assistant Surgeon to the North-West London Hospital; 48, Seymour street, Portman square, W.

1900 Johnson, Henry Heath Pochin, L.R.C.P., Charing Cross Hospital, W.C.

1868† Jones, Evan, Ty-Mawr, Aberdare, Glamorganshire. *Council*, 1886-8. *Vice.-Pres.* 1890-1. *Hon. Loc. Sec.*

1894 Jones, Evan, L.R.C.P. Lond., 89, Goswell road, E.C.

1895† Jones, George Horatio, Deddington, Oxon.

1881† Jones, James Robert, M.B., 247, Donald street, Winnipeg, Manitoba, Canada.

1894† Jones, John Arnallt, L.R.C.P. Lond., Heathmont, Aberavon, Port Talbot, Glamorganshire.

Elected

1887† Jones, J. Talfourd, M.B. Lond., Consulting Physician to the Breconshire Infirmary, Rose Bank, South terrace, Eastbourne.

1886 Jones, Lewis, M.D., Oakmead, Balham, S.W.

1873† Jones, Philip W., River House, Enfield.

1886† Jones, William Owen, The Downs, Bowdon, Cheshire.

1879† Joubert, Charles Henry, M.B. Lond., F.R.C.S. Eng. Lieut.-Col., Indian Medical Service, Bengal; Obstetric Physician to Eden Hospital, and Professor of Midwifery and Diseases of Women and Children, Calcutta Medical College; 6, Harington street, Calcutta.

1884 Keates, William Cooper, L.R.C.P., 20, East Dulwich road, S.E.

1883† Keeling, James Hurd, M.D., 267, Glossop road, Sheffield. *Hon. Loc. Sec.*

1896 Keep, Arthur Corrie, M.D., C.M.Edin., Surgeon to Outpatients to the Samaritan Free Hospital; 14, Gloucester place, Portman square, W.

1894 Kellett, Alfred Featherstone, M.B., B.C.Cantab., 142, Lewisham road, S.E.

1874* Kempster, William Henry, M.D., Chesterfield, Clapham common, North side, S.W.

1886 Kennedy, Alfred Edmund, L.R.C.P. Ed., Chesterton House, Plaistow, E.

1879 Ker, Hugh Richard, L.R.C.P.Ed., Tintern, 2, Balham hill, S.W.

1895† Kerr, John Martin Munro, M.B., C.M.Glasg.; Obstetric Physician to the Glasgow Maternity Hospital; 28, Berkeley terrace, Glasgow. *Trans.* 1.

1877*†Kerswill, John Bedford, M.R.C.P. Ed., Fairfield, St. German's, Cornwall.

1878† Khory, Rustonjee Naserwanjee, M.D., M.R.C.P., Medical Syndic, Bombay University; Honorary Physician, Bai Motlibai Obstetric and Gynæcological Hospital; Hormazd Villa, Khumballa hill, Bombay.

Elected

O.F.* Kiallmark, Henry Walter, 5, Pembridge gardens, Bayswater. *Council*, 1879-80.

1872* Kisch, Albert, 61, Portsdown road, W. *Council*, 1896-7.

1876*†Knott, Charles, M.R.C.P. Ed., Liz Ville, Elm grove, Southsea.

1889 Lake, George Robert, 177, Gloucester terrace, Hyde park, W.

1867* Langford, Charles P., Sunnyside, Hornsey lane, N.

1875† Lawrence, Alfred Edward Aust, M.D., Consulting Professor of Midwifery and Diseases of Women, University College, Bristol; Physician-Accoucheur to the Bristol General Hospital; 19, Richmond hill, Clifton, Bristol. *Council*, 1885-6, 1888. *Vice-Pres.*, 1889-90. *Hon. Loc. Sec. Trans.* 1.

1894† Lea, Arnold W. W., M.D., B.S.Lond., F.R.C.S., Lecturer on Midwifery and Diseases of Women, Owens College; 274, Oxford road, Manchester. *Trans.* 2.

1884*†Lediard, Henry Ambrose, M.D., 35, Lowther street, Carlisle. *Council*, 1890-2. *Trans.* 1.

1897 Leslie, William Murray, M.D. Edin., 74, Cadogan place, Belgrave square, S.W.

1900* Levison, Hugo Adolf, M.D.(Columbia Univ.), L.R.C.P. Lond., 44, West 35th street, New York.

1885 Lewers, Arthur H. N., M.D. Lond., M.R.C.P., Obstetric Physician to the London Hospital; 72, Harley street, W. *Council*, 1887-9, 1893, 1901. *Board Exam. Midwives*, 1895-7. *Trans.* 12.

1901† Littlewood, Harry, F.R.C.S., 40, Park square, Leeds.

1894 Livermore, William Leppingwell, L.R.C.P. Lond., 52, Stapleton Hall road, Stroud green, N.

1872*†Lock, John Griffith, M.A., 2, Rock terrace, Tenby.

1899 Lockyer, Cuthbert, M.D., B.S.Lond., F.R.C.S., 117a, Harley street, W.

Elected

1893† Logan, Roderic Robert Walter, Church street, Ashby-de-la-Zouch.

1859† Lombe, Thomas Robert, M.D., Bemerton, Torquay. *Council*, 1900-1.

1894† Loos, William Christopher, L.R.C.P. Lond.

1893† Lowe, Walter George, M.D. Lond., F.R.C.S., Burton-on-Trent.

1878*†Lycett, John Allan, M.D., Gatcombe, Surgeon to the Wolverhampton and District Hospital for Women, Wolverhampton.

1896† Lyons, A., M.B., Thames Ditton.

1871† McCallum, Duncan Campbell, M.D., Emeritus Professor McGill University; 45, Union avenue, Montreal, Canada. *Trans.* 4.

1890 McCann, Frederick John, M.D., C.M.Edin., M.R.C.P., Physician to Out-patients at the Samaritan Hospital; 5, Curzon street, Mayfair, W. *Council*, 1897-8. *Trans.* 3.

1894† McCausland, Albert Stanley, M.D. Brux., Churchill House, Swanage.

1890 McCaw, J. Dysart, M.D., F.R.C.S., Coolard Lodge, Great North road, East Finchley, N. *Council*, 1898-1900.

1894† McDonnell, Æneas John, M.D., Ch.M. Sydney, Toowoomba, Queensland.

1896 M'Donnell, W. Campbell, L.R.C.P. Lond., Park House, Park lane, Stoke Newington, N.

1892† McKay, W. J. Stewart, M.B., M.Ch.Sydney, Australian Club, Macquarie street, Sydney, N.S.W.

1897† McKerron, Robert Gordon, M.B. Aberd., 1, Albyn place, Aberdeen. *Trans.* 1.

1894† McKisack, Henry Lawrence, M.D.Dubl., 15, College square east, Belfast.

Elected

1900† Macan, Jameson John, M.A., M.D.Cantab., Crossgates, Cheam, Surrey.

1893 Maclean, Ewen John, M.D., C.M.Edin., M.R.C.P.Lond., Physician to Out-patients, Chelsea Hospital for Women; 51, Linden Gardens, W. *Council*, 1900.

1899 Macleod, William Aitken, M.B., C.M.Edin., 9, Pembridge villas, Bayswater, W.

1886 McMullen, William, L.K.Q.C.P.I., 319A, Brixton road, S.W.

1878 Macnaughton-Jones, H., M.D., M.A.O. (Hon. Causâ), F.R.C.S.I. & Edin., 131, Harley street, Cavendish square, W. *Trans.* 1.

1898 Macnaughton-Jones, Henry, M.B., B.Ch., 12, Sandwell mansions, West End lane, N.W.

1894† McOscar, John, L.R.C.P.Lond., Hazeldene, Kingston road, New Malden, Surrey.

1899† Maguire, George J., M.B., B.Ch., Kew road, Richmond.

1895† Maidlow, William Harvey, M.D.Durh., F.R.C.S.Eng., Ilminster, Somerset.

1884 Malcolm, John D., M.B., C.M., Surgeon to the Samaritan Free Hospital; 13, Portman street, W. *Council*, 1894-6.

1871† Malins, Edward, M.D., Obstetric Physician to the General Hospital, Professor of Midwifery at Mason College, Birmingham; 50, Newhall street, Birmingham. *Council*, 1881-3. *Vice-Pres.* 1884-6, 1901. *Hon. Loc. Sec.*

1868*†March, Henry Colley, M.D., Portisham, Dorchester. *Council*, 1890-2.

1887 Mark, Leonard P., M.D.Durh., 61, Cambridge street, Hyde-park square, W.

1860† Marley, Henry Frederick, The Nook, Padstow, Cornwall.

1862*†Marriott, Robert Buchanan, Swaffham, Norfolk.

1887† Marsh, O. E. Bulwer, L.R.C.P. Ed., Parkdale, Clytha park, Newport, Monmouthshire.

Elected

1890† Martin, Christopher, M.B., C.M.Edin., F.R.C.S.Eng., Surgeon to the Birmingham and Midland Hospital for Women; 35, George road, Edgbaston, Birmingham. *Trans.* 1.

1883† Maurice, Oliver Calley, 75, London street, Reading. *Council*, 1888-90.

1899† Maxwell, John Preston, M.B.Lond., F.R.C.S., Changhoo, c/o E. P. Mission, Amoy, China.

1890 May, Chichester Gould, M.A., M.D.Cantab., Assistant Physician to the Grosvenor Hospital for Women and Children; 59, Cadogan place, S.W.

1884† Maynard, Edward Charles, L.R.C.P.Ed., Arundel lodge, Worthing.

1885† Meller, Charles Booth, L.R.C.P. Ed., Cowbridge, Glamorganshire.

1886 Mennell, Zebulon, 1, Royal crescent, Notting hill, W.

1898 Menzies, Henry, M.B.Cantab., 4, Ashley gardens, S.W.

1882 Meredith, William Appleton, M.B., C.M., F.R.C.S.Eng., Surgeon to the Samaritan Free Hospital for Women and Children; 21, Manchester Square, W. *Council*, 1886-8. *Vice-Pres.* 1891-3. *Trans.* 3.

1893† Michie, Harry, M.B.Aber., 27, Regent street, Nottingham.

1875*† Miles, Abijah J., M.D., Professor of Diseases of Women and Children in the Cincinnati College of Medicine, Cincinnati, Ohio, U.S.

1895† Miller, James Thomas Roger, Castlegate House, Malton, Yorkshire.

1876* Millman, Thomas, M.D., 59, Yonge street, Toronto, Ontario, Canada.

1880† Mills, Robert James, M.B., M.C., 35, Surrey street, Norwich.

1892† Milton, Herbert M. Nelson, Kasr-el-Aini Hospital, Cairo, Egypt.

Elected

1869*†Minns, Pembroke R. J. B., M.D., Thetford, Norfolk.

1867* Mitchell, Robert Nathal, M.D., Brookwood, Hollington, St. Leonard's-on-Sea.

1894† Mondelet, William Henry, M.D., 1, Gladstone terrace, Brighton.

1893† Montbrun, D. Antonio de, L.R.C.P. Lond., Port of Spain, Trinidad, W.I.

1877 Moon, Frederick, M.B., 26, St. Thomas's Street, London Bridge, S.E.

1859† Moorhead, John, M.D., Surgeon to the Weymouth Infirmary and Dispensary; Weymouth, Dorset.

1895 Morison, Henry Bannermann, M.B. Durh., Lindley Lodge, Mottingham, Eltham, S.E.

1890 Morris, Charles Arthur, M.A., M.B., B.C.Cantab., F.R.C.S., 29, Eccleston street, Eaton square, S.W.

1883 Morris, Clarke Kelly, Gordon Lodge, Charlton road, Blackheath, S.E.

1899 Morris, Edwin Hugh Grant, M.B., B.C.Cantab., 8, Gloucester terrace, Onslow gardens, S.W.

1893 Morrison, James, L.R.C.P. Lond., Camden House, Wylde green, Birmingham.

1893† Morse, Thomas Herbert, F.R.C.S., All Saints' green, Norwich. *Trans.* 1.

1891 Mortlock, Charles, L.R.C.P. Lond., 27, Oxford square, Hyde park, W.

1886† Morton, Shadforth, M.D. Durham, 24, Wellesley road, Croydon.

1896 Mugford, Sidney Arthur, L.R.C.P., 135, Kennington park road, S.E.

1893 Muir, Robert Douglas, M.D., The Limes, New Cross road, S.E.

1896† Murphy, James Keogh, M.A., M.D., B.C.Cantab., 35, Princes square, Bayswater, W.

Elected

1885 Murray, Charles Stormont, L.R.C.S. and L.M. Ed., 85, Gloucester place, Portman square, W.

1893† Murray, Robert Milne, M.B. Edin., 11, Chester street, Edinburgh.

1893† Nairne, John Stuart, F.R.C.S. Ed., 141, Hill street, Garnethill, Glasgow.

1897† Nanavatty, Byramgi Hormayi, M.D., F.R.C.S.Ed., B. J. School of Medicine, Ahmedabad, Bombay Presidency.

1887 Napier, A. D. Leith, M.D. Aber., M.R.C.P. Lond., F.R.S.Edin., North terrace, East Adelaide, South Australia. *Trans.* 2.

1896† Nariman, R. T., M.D. Brux., Parsi Lying-in Hospital, Bombay.

1892† Nash, W. Gifford, F.R.C.S., Clavering House, De Parys avenue, Bedford.

1859† Neal, James, M.D., Parterre, Sandown, Isle of Wight.

1859*†Newman, William, M.D., Surgeon to the Stamford and Rutland Infirmary; Barn Hill House, Stamford, Lincolnshire. *Council*, 1873-5. *Vice-Pres.* 1876-7. *Trans.* 5.

1889† Newnham, William Harry Christopher, M.A., M.B. Cantab., Physician-Accoucheur to the Bristol General Hospital; Chandos Villa, Queen's road, Clifton, Bristol.

1895† Newstead, James, 9, York place, Clifton, Bristol.

1893† Nichol, Frank Edward, M.A., M.B., B.C. Cantab., 11, Ethelbert Terrace, Margate.

1873† Nicholson, Arthur, M.B. Lond., 30, Brunswick square, Brighton. *Council*, 1897-9.

1894 Nicholson, Edgar, M.R.C.S., The Laurels, High street, Fenny Stratford, Bucks.

1876* Nix, Edward James, M.D., 11, Weymouth street, W. *Council*, 1889-90.

1882† Norman, John Edward, Lismore House, Hebburn-on-Tyne.

1895† Ogle, John Gilbert, M.D.Oxon., Reigate, Surrey.

Elected

1888 Oliver, Franklin Hewitt, L.R.C.P. Lond., 2, Kingsland road, N.E.

1899† Osborn, Francis Arthur, L.R.C.P.Lond., The Chalet, Dover.

1890† Osburn, Harold Burgess, L.R.C.P., Bagshot, Surrey.

1877† Osterloh, Paul Rudolph, M.D. Leipzic, Physician for Diseases of Women, Diaconissen Hospital; 16, Sidonienstr., Dresden.

1892 Owen, Samuel Walshe, L.R.C.P.Lond., 10, Shepherd's Bush road, W.

1889* Page, Harry Marmaduke, M.D.Brux., F.R.C.S., 26, Ashley gardens, Victoria street, S.W.

1891† Page, Herbert Markant, M.D.Brux., 16, Prospect hill, Redditch.

1877* Paramore, Richard, M.D., 2, Gordon square, W.C.

1867*†Parks, John, Bank House, Manchester road, Bury, Lancashire.

1887 Parsons, John Inglis, M.D.Durh., M.R.C.P., Physician to Out Patients, Chelsea Hospital for Women, 3, Queen street, Mayfair, W. *Trans.* 2.

1880 Parsons, Sidney, 78, Kensington Park road, W.

1865*†Paterson, James, M.D., Hayburn Bank, Partick, Glasgow.

1899 Paul, J. E., M.D., 26, Queensborough terrace, Bayswater, W.

1882* Peacey, William, M.D., Rydal Mount, St. John's road, Eastbourne.

1894 Peake, Solomon, M.R.C.S., 118, Percy road, Shepherd's Bush, W.

1899 Peck, Francis Samuel, M.R.C.S.Eng., Major, Indian Medical Service; 6, Harrington street, Calcutta.

1871* Pedler, George Henry, 6, Trevor terrace, Rutland gate, S.W. *Council*, 1897-8.

Elected

1880*†Pedley, Thomas Franklin, M.D., Rangoon, India. *Trans.* 1.

1898 Penny, Alfred Gervase, M.A., M.B., B.C.Cantab., Queen's Avenue, Muswell Hill, N.

1881† Perigal, Arthur, M.D., New Barnet, Herts. *Council*, 1892–3.

1893 Perkins, George C. Steele, M.D., 85, Wimpole street, W.

1871† Perrigo, James, M.D., 826, Sherbrooke street, Montreal, Canada. *Hon. Loc. Sec.*

1879*†Pesikaka, Hormasji Dosabhai, 23, Hornby row, Bombay.

1894 Petty, David, M.B., C.M.Edin., 6, High road, South Tottenham, N.E.

1879 Phillips, George Richard Turner, 28, Palace court, Bayswater hill, W. *Council*, 1891.

1882 Phillips, John, M.A., M.D. Cantab., F.R.C.P., Obstetric Physician to King's College Hospital, and Lecturer on Practical Obstetrics in King's College; 68, Brook street, W. *Council*, 1887-9, 1893. *Hon. Lib.* 1894-5. *Hon. Sec.* 1896-9. *Board Exam. Midwives*, 1892-4. *Vice-Pres.* 1900-1. *Trans.* 11.

1897 Phillips, Llewellyn C. P., M.B., B.C. Cantab., St. Bartholomew's Hospital, E.C.

1878* Philpot, Joseph Henry, M.D., 61, Chester square, S.W. *Council*, 1891.

1889† Pinhorn, Richard, L.R.C.P. Lond., 5, Cambridge terrace, Dover. *Council*, 1897-9.

1889† Playfair, David Thomson, M.D., C.M. Edin., Redwood House, Bromley, Kent.

1893 Playfair, Hugh James Moon, M.D.Lond., Assistant Physician, Hospital for Women and Children, Waterloo road; 7, Upper Brook street, Grosvenor square, W. *Council*, 1900.

Elected

1864* Playfair, W. S., M.D., LL.D., F.R.C.P., Physician-Accoucheur to H.I. & R.H. the Duchess of Edinburgh; Consulting Obstetric Physician to King's College Hospital, 38, Grosvenor street, W. *Council*, 1867, 1883-5. *Hon. Librarian*, 1868-9. *Hon. Sec.* 1870-72. *Vice-Pres.* 1873-5. *Pres.* 1879-80. *Trans.* 15.

1891 Pollock, William Rivers, M.B., B.C.Cantab., Assistant Obstetric Physician to the Westminster Hospital, 56, Park street, Grosvenor square, W. *Council*, 1895-7. *Board Exam. Midwives*, 1898-9.

1876* Pope, H. Campbell, M.D., F.R.C.S., Broomsgrove Villa, 280, Goldhawk road, Shepherd's Bush, W.

1891† Pope, Henry Sharland, M.B., B.C.Cantab., Castle Bailey Bridgwater.

1888* Popham, Robert Brooks, M.R.C.P. Edin., L.R.C.P.Lond., care of Dr. MacVine, 350, Camden road, N.W.

1893 Powell, Herbert Edward, Glenarm House, Upper Clapton, N.E.

1886 Prangley, Henry John, L.R.C.P. Lond., Tudor House, 197, Anerley road, Anerley, S.E.

1880* Prickett, Marmaduke, M.A.Cantab., M.D., Physician to the Samaritan Hospital; 27, Oxford square, W. *Council*, 1892.

1895 Priestley, R. C., M.A., M.B.Cantab., 81, Linden gardens, Bayswater, W.

1898† Purslow, Charles Edwin, M.D., M.R.C.P.Lond., Honorary Obstetric Officer, Queen's Hospital, Birmingham; 192, Broad street, Birmingham.

1876*†Quirke, Joseph, M.R.C.P. Ed., The Oaklands, Hunter's road, Handsworth, Birmingham.

1878† Rawlings, John Adams, M.R.C.P.Ed., Preswylfa, Swansea.

Elected

1897 Rawlings, J. D., M.B.Lond., Rose Hill House, Dorking.

1870* Ray, Edward Reynolds, 15a, Upper Brook street, W.

1894† Rayner, Herbert Edward, F.R.C.S., Harcourt House, Camberley, Surrey.

1899† Rayner, David Charles, F.R.C.S.Eng., Oriel villa, 45, Cotham road, Bristol.

1860* Rayner, John, M.D., Swaledale House, Highbury quadrant, N.

1879 Read, Thomas Laurence, 11, Petersham terrace, Queen's gate, S.W. *Council*, 1892.

1879† Reid, William Loudon, M.D., Professor of Midwifery and Diseases of Women and Children, Anderson's College; Physician to the Glasgow Maternity Hospital; 7, Royal crescent, Glasgow. *Council*, 1899-1901.

1893† Renshaw, Israel James Edward, F.R.C.S.Edin., Ashton Grange, Cross street, Ashton-upon-Mersey.

1875*† Rey, Eugenio, M.D., 39, Via Cavour, Turin.

1890 Reynolds, John, M.D.Brux., 11, Brixton hill, S.W.

1872† Richardson, William L., M.D., A.M., Professor of Obstetrics in Harvard University; Physician to the Boston Lying-in Hospital; 225, Commonwealth avenue, Boston, Massachusetts, U.S.

1889† Richmond, Thomas, L.R.C.P. Ed., 22, Holyrood crescent, Glasgow.

1871* Rigden, Walter, M.D. St. And., 16, Thurloe place, S.W. *Council*, 1882-3. *Trans.* 1.

1892 Roberts, Charles Hubert, M.D.Lond., F.R.C.S.Eng., M.R.C.P., Physician to Out-patients to Queen Charlotte's Hospital; Demonstrator of Practical Midwifery and Diseases of Women, St. Bartholomew's Hospital; 21, Welbeck street, Cavendish square. *Council*, 1897-9. *Board Exam. Midwives*, 1901. *Trans.* 4.

Elected

O.F.*† Roberts, David Lloyd, M.D., F.R.C.P., F.R.S. Edin., Consulting Obstetric Physician to the Manchester Royal Infirmary; and Lecturer on Clinical Midwifery and the Diseases of Women in Owens College; 11, St. John street, Deansgate, Manchester. *Council*, 1868-70, 1880-2. *Vice-Pres.* 1871-2. *Trans.* 5.

1867* Roberts, David W., M.D., 56, Manchester street, Manchester square, W.

1890† Roberts, Hugh Jones, Gwyddfor, Penygroes, R.S.O., N. Wales.

1893 Roberts, Thomas, 2, Selborne gardens, York road, Ilford, Essex.

1874* Robertson, William Borwick, M.D., St. Anne's, Thurlow park road, West Dulwich, S.E.

1892 Robinson, George H. Drummond, M.D., B.S. Lond. Assistant Obstetric Physician, West London Hospital; 84, Park street, Grosvenor square, W. *Council*, 1899-1900. *Board Exam. Midwives*, 1898-1900. *Trans.* 2.

1887 Robinson, Hugh Shapter, L.R.C.P. Ed., Talfourd House, Camberwell, S.E.

1895† Robson, Alfred William, M.D. Brux., Kempstow House, 111, Park road, Aston, Birmingham.

1890† Robson, A. W. Mayo, F.R.C.S., 7, Park square, Leeds.

1876†*Roe, John Withington, M.D., Ellesmere, Salop.

1874*†Roots, William Henry, Canbury House, Kingston-on-Thames.

1874 Roper, Arthur, M.D. St. And., Colby, Lewisham hill, S.E. *Council*, 1886-8.

1859 Rose, Henry Cooper, M.D., 16, Warwick road, Maida hill, W. *Council*, 1875-7. *Trans.* 4.

1893† Rosenau, Albert, M.D., Hôtel Victoria, Kissingen, Bavaria. (*Winter*, Avenue la Costa, Monte Carlo.)

Elected

1884† Rossiter, George Frederick, M.B., Surgeon to the Weston-super-Mare Hospital; Cairo Lodge, Weston-super-Mare.

1884† Roughton, Walter, F.R.C.S., Cranborne House, New Barnet.

1882* Routh, Amand, M.D., B.S., F.R.C.P., Obstetric Physician and Lecturer on Midwifery at Charing Cross Hospital; 14a, Manchester square, W. *Council*, 1886-8, 1896-7. *Board Exam. Midwives*, 1893-5. *Hon. Lib.* 1898-9. *Hon. Sec.* 1900-1. *Trans.* 5.

O.F.* Routh, Charles Henry Felix, M.D., Consulting Physician to the Samaritan Free Hospital for Women and Children; 52, Montagu square, W. *Council*, 1859-61. *Vice-Pres.* 1874-6. *Trans.* 13.

1887*†Rowe, Arthur Walton, M.D. Dur., 1, Cecil street, Margate.

1886 Rushworth, Frank, M.D. Lond., 1a, Goldhurst terrace, South Hampstead, N.W.

1888† Rushworth, Norman, L.R.C.P. Lond., Beechfield, Walton-on-Thames.

1886† Rutherfoord, Henry Trotter, M.A., M.D. Cantab., Salisbury House, Taunton. *Council*, 1892-3. *Trans.* 1.

1895† Rutherford, George James, L.R.C.P.Lond.; A.C.S., Accra, West Africa.

1866*†Saboia, Baron V. de, M.D., Director of the School of Medicine, Rio de Janeiro; 7, Rua dom Affonso, Petropolis, Rio Janeiro. *Trans.* 2.

1864*†Salter, John H., D'Arcy House, Tolleshunt d'Arcy, Kelvedon, Essex. *Council*, 1894-6.

1868* Sams, John Sutton, St. Peter's Lodge, Eltham road, Lee, S.E. *Council*, 1892.

1886† Sanderson, Robert, M.B. Oxon., 56, Brunswick square, Brighton.

1872 Sangster, Charles, 148, Lambeth road, S.E.

Elected

1877 Savory, Charles Tozer, M.D., 25, Grange road, Canonbury, N. *Trans.* 1.

1894† Savory, Horace, M.A., M.B., B.C.Cantab., 45, Harpur street, Bedford. *Trans.* 1.

1890 Schacht, Frank Frederick, B.A., M.D.Cantab., 153, Cromwell road, S.W.

1888 Scott, Patrick Cumin, B.A., M.B. Cantab., 38, Shooter's Hill road, Blackheath, S.E.

1882 Serjeant, David Maurice, M.D., 27, Peckham road, S.E.

1875 Seton, David Elphinstone, M.D., 1, Emperor's gate, S.W. *Council*, 1884.

1896† Sharman, Mark, M.B., C.M.Glas., Rickmansworth.

1894† Sharpin, Archdale Lloyd, L.R.C.P. Lond., 23, Kimbolton road, Bedford.

1887 Shaw, John, M.D. Lond., Obstetric Physician to the North-West London Hospital; 32, New Cavendish street, Cavendish square, W. *Trans.* 3.

1891 Shaw-Mackenzie, John Alexander, M.D. Lond., 31, Grosvenor street, W.

1900† Shepherd, Thomas William, L.R.C.S.Edin., Castle Hill House, Launceston.

1900 Sherren, James, L.R.C.P.Lond., F.R.C.S.Eng., London Hospital, E.

1888† Sinclair, William Japp, M.D. Aber., Honorary Physician to the Southern Hospital for Women and Children and Maternity Hospital, Manchester; and Professor of Obstetrics and Gynæcology, Owens College, Manchester; 250, Oxford road, Manchester. *Council*, 1899-1901. *Trans.* 1.

1881† Sloan, Archibald, M.B., 21, Elmbank street, Glasgow.

1876† Sloan, Samuel, M.D., C.M., 5, Somerset place, Sauchiehall street west, Glasgow.

1890† Sloman, Frederick, 18, Montpellier road, Brighton.

1861 Slyman, William Daniel, 26, Caversham road, Kentish Town, N.W. *Council*, 1881.

Elected

1867* Smith, Heywood, M.D., 18, Harley street, Cavendish square, W. *Council*, 1872-5. *Board Exam. Midwives*, 1874-6. *Trans.* 6.

1875 Smith, Richard Thomas, M.D., Physician to the Hospital for Women, Soho square; 117, Haverstock hill, N.W.

1886† Smith, Samuel Parsons, L.K.Q.C.P.I., Park Hyrst, Addiscombe road, Croydon.

1899† Smyly, William Josiah, M.D., F.R.C.P.I., 58, Merrion square, Dublin.

1899† Smithson, Oliver, L.R.C.P., Gas street, Kettering.

1895 Soden, Wilfred Newell, M.B.Lond., 186, Amhurst road, Hackney, N.E.

1895 Sparks, Charles Edward, M.B., B.C., B.A.Cantab., Netherdale, Church End, Finchley, N.

1868* Spaull, Barnard E., 1, Stanwick road, West Kensington, W.

1888* Spencer, Herbert R., M.D., B.S.Lond., F.R.C.P., Professor of Midwifery in University College, London, and Obstetric Physician to University College Hospital; 104, Harley street, W. *Council*, 1890-92. *Board Exam. Midwives*, 1896-7. *Hon. Sec.* 1898-1901. *Trans.* 8.

1876† Spencer, Lionel Dixon, M.D., Brigade-Surgeon, I.M.S., Bengal Establishment [care of Messrs. Grindlay and Co., 55, Parliament street, S.W.].

1882 Spooner, Frederick Henry, M.D., Maitland Lodge, Maitland place, Clapton, N.E.

1876† Spurgin, Herbert Branwhite, 82, Abington street, Northampton.

1897 Stabb, Arthur Francis, M.B., B.C. Cantab., Assistant Obstetric Physician to St. George's Hospital, and Lecturer in Midwifery in the University of Cambridge; 109, Harley street, W. *Council*, 1899-1901.

1893 Stack, E. H. Edwards, M.B., B.C. Cantab., Royal Infirmary, Bristol.

1894 Stevens, Thomas George, M.D., B.S. Lond., 8, St. Thomas's street, S.E. *Trans.* 2.

Elected

1884† Stevenson, Edmond Sinclair, F.R.C.S. Ed., Strathallan House, Rondebosch, Cape of Good Hope. *Trans.* 2.

1877† Stephenson, William, M.D., Professor of Midwifery, University of Aberdeen; 3, Rubislaw terrace, Aberdeen. *Council*, 1881-3. *Vice-Pres.*, 1887-9. *Trans.* 2.

1875*†Stewart, William, F.R.C.P. Ed., 26, Lethbridge road, Southport.

1884† Stiven, Edward W. F., M.D., The Manor Lodge, Harrow-on-the-Hill.

1884 Stivens, Bertram H. Lyne, M.D.Brux., 107, Park street, Grosvenor square, W.

1883 Stocks, Frederick, 421, Wandsworth road, S.W.

1894† Stott, William Atkinson, M.R.C.S., L.R.C.P. Lond., 1, Grove terrace, Leeds.

1866* Strange, William Heath, M.D., 2, Belsize avenue, Belsize park, N.W. *Council*, 1882-4.

1895 Stuck, Sidney Joseph, M.D., Whitechapel Infirmary, E.

1898† Sturmer, Arthur James, Lieut.-Col., Indian Medical Service, Madras.

1884 Sunderland, Septimus, M.D., Physician to the Royal Hospital for Children and Women; 11, Cavendish place, Cavendish square, W.

1883* Sutherland, Henry, M.A., M.D. Oxon., M.R.C.P., 21, New Cavendish street, W.

1894 Swallow, Allan James, M.B., B.S. Durh., 5, Mount Edgecumbe gardens, Clapham rise, S.W.

1896 Swan, Charles Atkin, M.B., B.Ch.Oxon., 4, Devonport street, Hyde Park, W.

1893 Swayne, Francis Griffiths, M.A., M.B., B.C.Cantab., 15, Church road, Norwood, S.E.

1859*†Swayne, Joseph Griffiths, M.D., Consulting Physician-Accoucheur to the Bristol General Hospital; Emeritus Professor of Midwifery in University College, Bristol; Harewood House, 74, Pembroke road, Clifton, Bristol. *Council*, 1860-1. *Vice-Pres.* 1862-4. *Trans.* 9.

Elected

1892† Swayne, Walter Carless, M.D.Lond., Obstetric Physician, Bristol Royal Infirmary; Lecturer on Practical Midwifery in University College, Bristol; 8, Leicester place, St. Paul's road, Clifton.

1888* Sworn, Henry George, L.K.Q.C.P. & L.M., 5, Highbury crescent, N.

1883 Tait, Edward Sabine, M.D., 48, Highbury park, N. *Council*, 1892-4. *Trans.* 1.

1879 Tait, Edward W., 10, Ellerdale road, Hampstead, N.W. *Council*, 1886-7.

1880*†Takaki, Kanaheiro, F.R.C.S., 10, Nishi-Konyachō, Kiōbashika, Tokio, Japan. *Hon. Loc. Sec.*

1859 Tapson, Alfred Joseph, M.B. Lond., Heath Lodge, Hillingdon, Uxbridge. *Council*, 1862-4. *Vice-Pres.* 1891.

1891 Targett, James Henry, M.B., M.S. Lond., F.R.C.S., Assistant Obstetric Surgeon to Guy's Hospital, 6, St. Thomas's street, S.E. *Council*, 1895. *Board Exam. Midwives*, 1900-1.

1892 Tate, Walter William Hunt, M.D.Lond., Assistant Obstetric Physician to, and Lecturer on Midwifery and the Diseases of Women at, St. Thomas's Hospital; 57, Queen Anne street, Cavendish square, W. *Council*, 1895-7. *Board Exam. Midwives*, 1898-9. *Trans.* 1.

1871 Tayler, Francis T., B.A. Lond., M.B., Claremont villa, 224, Lewisham High road, S.E.

1900 Taylor, Frank Edward, M.A., M.B., Queen Charlotte's Hospital, N.W.

1869† Taylor, John, Earl's Colne, Halstead, Essex.

1890*†Taylor, John William, F.R.C.S., Surgeon to the Birmingham and Midland Hospital for Women; Professor of Gynæcology, Birmingham University 22, Newhall street, Birmingham. *Trans.* 2. *Council*, 1900-1.

1892 Taylor, William Bramley, 145, Denmark hill, S.E.

Elected

1885† Taylor, William Charles Everley, M.R.C.P. Edin., 34, Queen street, Scarborough.

1894† Tench, Montague, M.D. Brux., L.R.C.P. Lond., Great Dunmow, Essex.

1890† Thomas, Benjamin Wilfred, L.R.C.P. Lond., Welwyn.

1899† Thomas, J. Raglan, M.D., 13, West Southernhay, Exeter.

1887† Thomas, William Edmund, L.R.C.P.Ed., Pentwyn, Bridgend, Glamorganshire.

1867*†Thompson, Joseph, L.R.C.P. Lond., Surgeon to the General Hospital and Hospital for Women, Nottingham; 1, Oxford street, Nottingham. *Trans.* 1. *Hon. Loc. Sec. Council*, 1896-8.

1878 Thomson, David, M.D., 33, Lowndes street, Belgrave square, S.W.

1873* Ticehurst, Charles Sage, Petersfield, Hants.

1895† Tinley, William Edwin Falkingridge, M.B., B.S.Durh., Thorsgrit, Whitby.

1879† Tivy, William James, F.R.C.S. Ed., 8, Lansdown place, Clifton, Bristol.

1872† Tototschinoff, N., M.D., Charkoff, Russia.

1884 Travers, William, M.D., 2, Phillimore gardens, W.

1893† Trethowan, William, M.B., C.M. Aber., care of Dr. Mac-Williams, Perth, Western Australia.

1886† Tuckett, Walter Reginald, Woodhouse Eaves, near Loughborough.

1898 Turner, Arthur Scott, L.R.C.P.Lond., Stanton, Anerley, S.E.

1865* Turner, John Sidney, Stanton House, 81, Anerley road, Upper Norwood, S.E. *Council*, 1893-4.

1891 Turner, Philip Dymock, M.D.Lond., Sudbury villa, Ryde, Isle of Wight. *Trans.* 1.

1861 Tweed, John James, F.R.C.S., 14, Upper Brook street, W. *Council*, 1896.

1897 Twynam, George Edward, L.R.C.P.Lond., 31, Gledhow gardens, S.W.

Elected

1890 Tyrrell, Walter, L.R.C.P.Lond., 104, Cromwell road, S.W.

1893 Umney, William Francis, M.D.Lond., Heatherbell, 15, Crystal Palace park road, Sydenham, S.E.

1874* Venn, Albert John, M.D., 63, Grosvenor street, W.

1873* Verley, Reginald Louis, F.R.C.P. Ed., Constitutional Club, W.C.

1892† Verrall, Thomas Jenner, L.R.C.P.Lond., 97, Montpellier road, Brighton.

1900* Vincent, Ralph Henry, M.B., B.S.Durh., Queen Charlotte's Hospital, N.W.

1879† Wade, George Herbert, Ivy Lodge, Chislehurst, Kent. *Council*, 1892-3.

1894† Wagstaff, Frank Alex., L.R.C.P. Lond., Saffron Walden, Essex.

1860† Wales, Thomas Garneys, Downham Market, Norfolk.

1898† Walker, Alfred, M.D., B.C., M.A.Cantab., 12, Lingfield road, Wimbledon.

1866*†Walker, Thomas James, M.D., Surgeon to the General Infirmary, Peterborough; 33, Westgate, Peterborough. *Council*, 1878-80. *Hon. Loc. Sec.*

1889 Wallace, Abraham, M.D. Edin., 39, Harley street, W.

1870 Wallace, Frederick, Foulden Lodge, Upper Clapton, N.E. *Council*, 1880-2.

1897† Wallace, James Robert, M.D.Brux., F.R.C.S.I., 50, Park street, Calcutta.

1883 Wallace, Richard Unthank, M.B., Cravenhurst, Craven park, Stamford hill, N.

1893† Walls, William Kay, M.B. Lond., 14, St. John street, Manchester.

1879*†Walter, William, M.A., M.D., Surgeon to St. Mary's Hospital, Manchester; 20, St. John street, Manchester.

1867*†Walters, James Hopkins, Surgeon to the Royal Berkshire Hospital; 15, Friar street, Reading, Berks. *Council*, 1884-6. *Trans.* 1. *Hon. Loc. Sec.*

Elected

1873† Walters, John, M.B., Church street, Reigate, Surrey. *Council*, 1896-8. *Trans.* 1.

1898*†Ward, Charles, F.R.C.S.I., M.R.C.S.Eng., Pietermaritzburg, Natal, S. Africa.

1895 Warner, Frederick Ashton, L.R.C.P., 10, Brechin place, South Kensington, S.W.

1898† Watson, C. R., M.D.Brux., 3, Mount Ephraim road, Tunbridge Wells.

1899† Watson, Harry Jackson, M.D., C.M. Toronto, c/o. Chief Surgeon, Department of Southern Lugon, Manila, Philippine Islands.

1884† Waugh, Alexander, L.R.C.P. Lond., Midsomer-Norton, Bath.

1894† Webb, John Curtis, M.A., M.B., B.C.Cantab., 6, Collingham place, Earl's Court.

1886† Webber, William W., L.R.C.P. Ed., Crewkerne.

1893† Webster, Thomas James, Brynglâs, Merthyr Tydvil.

1897† Weeks, Courtenay Charles, L.R.C.P.Lond., 9, Lewisham park, Lewisham, S.E.

1886† West, Charles J., L.R.C.P. Lond., The Grove, Fulbeck, Grantham.

1888* Weston, Joseph Theophilus, M.D.Brux., Civil Surgeon, Hissar, Punjab (care of Messrs. Thacker, Spink, and Co., booksellers and publishers, Government place, Calcutta).

1890 Wheaton, Samuel W., M.D.Lond., Physician to the Royal Hospital for Children and Women; 76, The Chase, Clapham common, S.W.

1889† Whitcombe, Charles Henry, F.R.C.S. Edin., 281, Queen's road, Halifax.

1890 White, Charles Percival, M.A., M.B., B.C.Cantab., 22, Cadogan gardens, S.W. *Council*, 1901.

1882 Wholey, Thomas, M.B. Durh., Winchester House, 50, Old Broad street, E.C.

Elected

1901† Wigg, Henry Higham, M.D.Brux., L.R.C.P.Adelaide.

1901 Willey, F. J. I., M.B., B.S., The Wych, Avenue road, Highgate.

1894† Williams, John D., M.D. Ed., B.Sc., 20, Windsor place, Cardiff.

1872 Williams, Sir John, Bart., M.D., F.R.C.P., Physician-Accoucheur to H.R.H. Princess Beatrice, Princess Henry of Battenberg; Consulting Obstetric Physician to University College Hospital; 63, Brook street, Grosvenor square, W. *Council*, 1875-6, 1892, 1894. *Hon. Sec.* 1877-9. *Vice-Pres.* 1880-2. *Board Exam. Midwives*, 1881-2; *Chairman*, 1884-6. *Pres.* 1887-8. *Trans.* 12. *Trustee.*

1897 Williams, Joseph William, L.R.C.P., 128, Mansfield road, Gospel Oak, N.W.

1890 Williams, Reginald Muzio, M.D.Lond., 35, Kensington park gardens, W.

1899 Williamson, Herbert, M.A., M.B., B.C.Cantab., 10, Bentinck street, Manchester square, W. *Trans.* 1.

1881 Willis, Julian, M.R.C.P. Ed., care of Walter Willis, Esq., 20, Nottingham place, York gate, W.

1898† Wilson, Claude, M.D.Edin., Belmont, Church road, Tunbridge Wells.

1892† Wilson, Thomas, M.D., B.S.Lond., F.R.C.S., Assistant Obstetric Physician at the General Hospital, Birmingham; 87, Cornwall street, Newhall street, Birmingham. *Trans.* 3.

1900† Wingate, William Warburton, M.B., B.C.Cantab., 60, St. Andrew's street, Cambridge.

1886† Winterbottom, Arthur Thomas, L.R.C.P. Ed., Lark hill, Swinton, Manchester.

1896† Winter, John Bradbury, L.R.C.P, 28, Montpelier road, Brighton.

1877* Wintle, Henry, M.B., Elmsleigh, High street, Staines.

Elected

1893 Wise, Robert, M.D.Edin., 5, Weston park, Crouch End, N.

1887† Withers, Robert, Stenteford Lodge, Spencer terrace, Lipson road, Plymouth.

1890 Wornum, George Porter, 58, Belsize park, Hampstead, N.W.

1876† Worts, Edwin, 6, Trinity street, Colchester.

1887† Wright, Charles James, Senior Surgeon to the Hospital for Women and Children, Leeds; Professor of Midwifery to the Yorkshire College; Lynton Villa, Virginia road, Leeds.

1888*†Wyatt-Smith, Frank, M.B., B.C.Cantab., British Hospital, Buenos Ayres.

1871 Yarrow, George Eugene, M.D., 26, Duncan terrace, Islington, N. *Council*, 1881-3.

1882*†Young, Charles Grove, M.D., Berbice, Sea road, Bexhill-on-Sea.

Number of Fellows . . . . 655.

CONTENTS.

	PAGE
List of Officers for 1901	v
Standing Committees	vii
List of Honorary Local Secretaries	viii
List of Past Presidents	ix
List of Referees of Papers for 1901	x
Trustees of the Society's Property	xi
List of Honorary Fellows	xi, xii
List of Ordinary Fellows	xiii
Contents	lvii
List of Plates	lxiii
List of Illustrations	lxv
Advertisement	lxvi
Hours of Attendance at Library	lxvi

January 3rd, 1900—

Specimen of Adenoma of the Uterus, shown by Dr. EDEN	2
Specimen of Cast of the Uterus, shown by Dr. EDEN	5
Photographs from a case of Primary Cancer of the Fallopian Tube, shown by the PRESIDENT for Professor PAWLIK, of Prague	6
Macerated Fœtus removed from the Abdominal Cavity two months after Spurious Labour, shown by Mr. ALBAN DORAN	8
Case of Double Pyosalpinx in which the Tubal Sacs communicated, shown by Mr. MALCOLM	10

PAGE

I. Four Cases of Rupture of the Uterus successfully treated by Packing the Tear *per vaginam* with Iodoform Gauze, by Dr. HERBERT R. SPENCER . 14

February 7th, 1900—

Annual Meeting 29

Specimen of Fœtus Thoracopagus, shown by Dr. AMAND ROUTH 29

Report on Specimen of Fœtus Thoracopagus, shown by Dr. AMAND ROUTH . . . 31

Specimen of Primary Solid Carcinoma of the Ovary, shown by Dr. GRIFFITH . . . 34

Multilocular Cyst of the Oöphoron, shown by Mr. CUTHBERT LOCKYER 37

Annual Meeting—the Audited Report of the Treasurer (Dr. J. WATT BLACK) . . 37, 38

—— Report of the Honorary Librarian (Dr. AMAND ROUTH) 39

—— Report of the Chairman of the Board for the Examination of Midwives (Dr. BOULTON) . 39

—— Election of Officers and Council for the year 1900 41

—— Annual Address of the President (Mr. ALBAN DORAN) 43

March 7th, 1900—

Redescription of the Specimen of Spondylolisthesis in the Museum of University College, shown by Mr. T. W. P. LAWRENCE . . . 75

Spinal Column exhibiting want of Ossification in the Interarticular Portion of the Lumbar Vertebræ, etc., shown by Dr. BLACKER . . . 90

Two cases of Congenital Malformation of the Genital Organs, shown by Dr. MACNAUGHTON-JONES . 92

Uterus with Fibroid Tumour undergoing Mucoid Change, successfully removed by Abdominal Hysterectomy with Intra-peritoneal Treatment of the Stump, shown by Dr. LEWERS . . . 94

Ruptured Uterus with Dermoid Ovarian Cyst the Size of a Child's Head, shown by Dr. LEWERS . 95

Large Inflamed Cyst (? Ovarian) communicating with an Inflamed Fallopian Tube, shown by Drs. CULLINGWORTH and FAIRBAIRN . . 96

PAGE

Fœtus with Anasarca and Large Placenta, shown by Dr. Boxall 98

II. The Anatomy and Nature of Two Acardiac Acephalic Fœtuses, by Dr. A. Keith 99

III. A case of Extra-uterine Gestation in which Fœtal Death occurred at Term after Spurious Labour, and Abdominal Section was performed four to five Months later, by Dr. John Phillips . . 121

April 4th, 1900—

Letters from Sir William O. Priestley and Dr. J. R. Chadwick . . . 131, 132

Incarcerated Fibro-myoma of Uterus in an Unusually Young Subject, shown by Dr. Cullingworth 132

Pedunculated Subserous Fibro-myoma of Uterus which had undergone Myxomatous and Cystic Degeneration, shown by Dr. Stabb . . 133

Tubal Mole; Fœtus three quarters of an inch in length, in perfect preservation, shown by the President (Mr. Alban Doran) . . . 134

Solid Tumour of the Ovary removed from a woman aged thirty-six, shown by Dr. Addinsell . 139

Ovarian Cystoma complicating Pregnancy; Infection of the Cyst five days after Labour; Operation on the forty-third day; extensive Peritoneal and Bowel Adhesions; Recovery; shown by Dr. Macnaughton-Jones 140

Case of Myxo-sarcoma of the Vagina in a child aged two and a half years, shown by Dr. A. W. W. Lea 143

IV. Three cases of Incarceration of the Retro-displaced Gravid Uterus and one of Extra-uterine Pregnancy simulating that condition, by Dr. J. Munro-Kerr 146

May 2nd, 1900—

Large Fibro-myoma of the Cervix removed by Enucleation, followed by Vaginal Hysterectomy, shown by Dr. Walter Tate 161

Case of Suppurating Ovarian Cyst obstructing Labour, removed by Abdominal Section eighteen months later, shown by Dr. Walter Tate . 164

PAGE

Fibroid Tumours of the Uterus with great Distension of the Fallopian Tubes from Tubercle, shown by Dr. Horrocks 166

Case of Myxoma of Chorion not discharged till the seventh month, shown by Dr. C. Hubert Roberts 168

Imperforate Rectum and Congenital Prolapse of the Uterus, shown by Dr. H. R. Andrews . . 169

Double Tuberculous Pyosalpinx with Intercommunication of the Tubes, shown by Dr. Galabin . 173

V. The Relations of Organic Affections of the Heart to Fibro-myoma of the Uterus, by Thomas Wilson . 176

June 6th, 1900—

Report on Dr. Stabb's Specimen of Myxo-fibroma (? Sarcoma) of Uterus 209

Squamous-celled Epithelioma of the Cervix Uteri in a very early stage, shown by Dr. W. S. A. Griffith 210

Squamous-celled Epithelioma invading surrounding tissues like a columnar-celled variety, shown by Dr. W. S. A. Griffith . . . 210

Sarcoma of the Uterus, with a microscopic section, shown by Dr. H. R. Andrews . . . 210

Cystic Fibro-myoma of the Cervix Uteri, shown by Dr. Roberts 211

VI. A case of Extra-uterine Gestation in which Fœtal Death occurred at the eighth month after Spurious Labour; Abdominal Section two months later; by the President (Mr. Alban Doran) . . 213

July 4th, 1900—

Frozen Sections of a Uterus at the tenth week of Pregnancy, showing Hæmorrhages into the Placenta, Decidua reflexa, and Decidua vera, from a patient who died of Heart Disease, shown by Dr. Blacker 235

Pregnant Uterus and Fibroid Tumour removed by Abdominal Hysterectomy, shown by Dr. Horrocks 242

Ruptured Uterus at term through Scar of old Cæsarean Section, Abdominal Hysterectomy, shown by Mr. J. H. Targett 242

PAGE

Multiple Myxomatous Polypi from Cervix Uteri, shown by Dr. WILLIAM DUNCAN . . . 243

VII. Porro-Cæsarean Hysterectomy with Retro-peritoneal Treatment of the Stump in a case of Fibroids obstructing Labour, with remarks upon the relative advantages of the modern Porro operation over the Sänger-Cæsarean in most other cases requiring abdominal section, by Dr. AMAND ROUTH . 244

October 3rd, 1900—

Report of Committee on Dr. H. R. Andrews' Specimen of Sarcoma of Uterus 265

Rudimentary Supernumerary Digits, shown by Dr. H. RUSSELL ANDREWS 266

Cancer of the Cervix associated with an adenomatous growth in the Fundus, shown by Dr. C. HUBERT ROBERTS 267

Full-term Pregnancy in a Rudimentary Horn of Uterus; missed labour (five months); abdominal section and removal of sac; recovery, shown by Mr. TARGETT 276

Carcinoma of the Body of the Uterus, shown by Mr. TARGETT 281

VIII. On Subcutaneous Symphysiotomy, by Dr. G. ERNEST HERMAN 282

November 7th, 1900—

Fibro-myoma of the Uterus in a patient aged twenty-three, with remarks on Enucleation and Myomectomy, shown by Dr. GILES 299

Fatal Rupture of an Aneurysm of the Splenic Artery immediately after Labour, shown by Mr. NODES and Dr. HINDS 305

Tubal Abortion in which the "Mole" was in process of Extrusion at the time of Operation, shown by Mr. BLAND-SUTTON 311

IX. An Anomalous Case of Ectopic Pregnancy, probably Ovarian, by Dr. E. OCTAVIUS CROFT . . . 316

X. A case of Repeated Ectopic Gestation in the same patient; laparotomy on each occasion, by Dr. LEWERS 324

PAGE

December 5th, 1900—

Two Cases of Parovarian Cyst with Twisted Pedicle, in which the ovary only (and not the cyst) was congested and inflamed, shown by Dr. HERBERT R. SPENCER 333

XI. A Contribution to the Diagnosis and Treatment of Retroflexio-versio Uteri Gravidi, by Dr. W. J. SINCLAIR 338

XII. The Essential Factor in the Causation of Sex, by Mr. E. RUMLEY DAWSON 356

INDEX 399

ADDITIONS TO THE LIBRARY 421

PLATES.

PLATE — PAGE

I.—Specimen of Adenoma of the Uterus (Dr. T. W. Eden).
Fig. 1.—Section of tissue removed by the curette, showing regular gland tubules and abundant fibro-muscular stroma.
Fig. 2.—Section through uterine wall at site of growth, showing penetration of gland tubules between the fibro-muscular bundles . . 3

II—IV.—Specimen of Fœtus Thoracopagus (Dr. Amand Routh) 31

V.—Specimen of Primary Solid Carcinoma of the Ovary (Dr. W. S. A. Griffith).
Fig. 1.—(*a*) Columnar-celled growth invading Ovarian Stroma.
Fig. 2.—(*a*) Ovarian Stroma, (*b*) Acini lined by Columnar Epithelium . 35

VI, VII.—Re-description of the specimen of Spondylolisthesis in the museum of University College (Mr. T. W. P. Lawrence, introduced by Dr. Blacker) 77

VIII—XI.—Anatomy and Nature of Two Acardiac Acephalic Fœtuses (Dr. A. Keith, introduced by Dr. Lewers):
VIII.—The larger Fœtus, with the skin and subcutaneous tissue dissected away on the right side to show the Cerebral and Osseous Systems 101
IX.—A Mesial Section of the smaller Fœtus 101
X.—Dissection of the larger Fœtus to show the position of the Heart and arrangement of vessels. The Cerebral Vesicle is shown in section 101
XI.—The Vascular System of the larger Fœtus. In the right hand lower corner the probable connection between the placental circulations of the "host" and "parasite" is shown 101

PLATE PAGE

XII.—Tubal Mole; fœtus three quarters of an inch in length, in perfect preservation (Mr. Alban Doran) 137

XIII.—Double Tuberculous Pyosalpinx, with intercommunication of the Tubes (Dr. Galabin) 175

XIV—XIX.—Frozen Sections of a Uterus at the Tenth Week of Pregnancy, showing Hæmorrhages into the Placenta, Decidua Reflexa, and Decidua Vera from a patient who died of Heart Disease (Dr. Blacker) . . 239

XX.—Cancer of the Cervix associated with an Adenomatous Growth in the Fundus (Dr. C. Hubert Roberts) . . . 269

XXI, XXII.—Full-term Pregnancy in a Rudimentary Horn of Uterus; missed labour (five months). Abdominal section and removal of sac; recovery (Mr. J. H. Targett) . . 280

XXIII.—Fatal Rupture of an Aneurysm of the Splenic Artery immediately after Labour (Mr. Nodes and Dr. Hinds) 306

XXIV.—An Anomalous Case of Ectopic Pregnancy, probably Ovarian (Dr. E. O. Croft) . . 319

XXV.—A Case of Repeated Ectopic Gestation in the same patient; laparotomy on each occasion . 328

XXVI.—Two Cases of Parovarian Cyst with Twisted Pedicle, in which the ovary only (and not the cyst) was congested and inflamed (Dr. Herbert R. Spencer) . 334

ILLUSTRATIONS.

PAGE

Imperforate Rectum and Congenital Prolapse of the Uterus (Dr. H. R. Andrews) 170

Frozen Sections of a Uterus at the Tenth Week of Pregnancy, showing Hæmorrhages into the Placenta, Decidua Reflexa, and Decidua Vera from a patient who died of Heart Disease (Dr. Blacker).

Diagram illustrating direction and position of Sections made through Uterus . . . 237

Tubal Abortion, in which the "Mole" was in Process of Extrusion at the time of Operation (Mr. Bland-Sutton).

A gravid Fallopian Tube and Ovary. A mole is in process of extrusion from the Cœlomic Ostium . 312

ADVERTISEMENT.

The Society is not as a body responsible for the facts and opinions which are advanced in the following papers and communications read, nor for those contained in the abstracts of the discussions which have occurred at the meetings during the Session.

20, Hanover Square, W.

LIBRARY AND MUSEUM,

20, Hanover Square, W.

Hours of Attendance: Monday to Friday, 1.30 p.m. to 6 p.m.; Saturday, 9 30 a.m. to 2 p.m.; and in the evenings on which the Society meets, from 7.15 p.m. to 7.45 p.m.

AGNES HANNAM, F.R.S.L.,
Secretary and Librarian

OBSTETRICAL SOCIETY

OF

LONDON.

SESSION 1900.

JANUARY 3RD, 1900.

ALBAN DORAN, F.R.C.S., President, in the Chair.

Present—26 Fellows and 1 Visitor.

Books were presented by the Clinical Society, the Société de Médecine de Rouen, Dr. Peter Thompson, Dr. Frommel, Prof. Varnier, Dr. J. Whitridge Williams, and Prof. Kleinwächter.

Oliver Smithson, L.R.C.P. (Grays), and Godfrey C. B. Hawes, L.R.C.P. (Pangbourne), were declared admitted.

The following gentlemen were elected Fellows of the Society :—Ernest James Hayford, M.D. (Freetown, Sierra Leone), and William Warburton Wingate, M.B., B.C. Cantab. (Cambridge).

SPECIMEN OF ADENOMA OF THE UTERUS.

(See Plate I, figs. 1 and 2.)

Shown by T. W. Eden, M.D., M.R.C.P.

Dr. Eden said the history of the patient whose uterus he now showed to the Society was as follows:—She was a widow, aged 49, nulliparous, and she had suffered from metrorrhagia for six months. On June 6th, 1899, she was seen by Dr. Amand Routh in consultation with Dr. Walker, of Hamilton Terrace, and the presence of a growth of the size of a billiard ball was detected in the cervical canal, which was considerably dilated. On June 13th this growth was removed by Dr. Routh, and it appeared so friable that he formed the opinion that it was malignant. The portions of growth removed were then sent to him (Dr. Eden) for microscopic examination. He found that the growth consisted of gland tubules embedded in an abundant stroma. The epithelium of the tubules was columnar in shape, and the cells were regular in distribution and showed little or no tendency to proliferate. The stroma consisted of well-formed fibro-muscular tissue, very like the tissue of the uterine wall, and in proportion to the tubules was very abundant. He therefore formed the opinion that the growth was a fibro-adenoma, non-malignant in character, and reported to Dr. Routh to that effect. Subsequently a consultation was held with Sir John Williams, to whom the microscopic sections were also submitted, and he, while agreeing in calling the growth an adenoma, expressed the view that adenoma of the body of the uterus occurring about the climacteric period was always malignant in character, and therefore advised the removal of the uterus. This was done by Dr. Routh on June 27th, and the uterus was handed to him (Dr. Eden) for further examination. On slitting the organ open no trace of new growth was to be seen in any part with the naked eye. A circular

DESCRIPTION OF PLATE I.

Illustrating Dr. Eden's specimen of Adenoma of the Uterus.

Fig. 1.—Section of tissue removed by the curette, showing regular gland tubules and abundant fibro-muscular stroma.

Fig. 2.—Section through uterine wall at site of growth, showing penetration of gland tubules between the fibro-muscular bundles.

Fig. 1.

Fig. 2.

Illustrating Dr. Eden's Case of Adenoma of the Uterus.

Drawn, Engraved and Printed by Bale & Danielsson.

depression, rather larger than a sixpence, was seen a little above the level of the internal os, which represented the site of attachment of the growth which had been previously removed; otherwise the uterus appeared to be normal. A small piece of the uterine wall was cut from the base of this depression, and microscopic sections were taken with great care in a plane vertical to the surface. The microscope showed that a thin superficial layer of tissue remained, exactly similar to the growth previously removed. The deeper tubules, however, showed marked epithelial proliferation, leading to the formation of spaces packed with irregular round and oval cells. Some of the neighbouring tubules fused with one another; and further, a chain of gland tubules, very like normal uterine glands, could be seen passing deeply among the fibro-muscular bundles for nearly half an inch from the surface. The tubules buried in the uterine wall were, however, regular in size and shape, and showed no epithelial proliferation; only the tubules on the surface showed the latter changes.

On the whole the case seemed to be an example of a growth the nature of which was open to doubt. In its general characters it was certainly non-malignant; but the two points mentioned, viz. the epithelial proliferation, and the penetration of the tubules into the uterine wall, were points in favour of malignancy. It must be remembered, however, that under normal conditions the uterine gland tubules often penetrated the muscular wall to some extent. Unfortunately the patient died suddenly of pulmonary embolism on the fourteenth day after the operation, and no light could therefore be thrown upon the question by the subsequent history of the case.

The PRESIDENT alluded to the recent death of Sir James Paget, whom the whole profession deplored. In his Bradshawe Lecture "On some Rare and New Diseases" and in his Morton Lecture "On Cancer" the great surgeon had urged us to be very careful about all exceptions to rule in clinical and pathological research. Hence the value of good reports of a disease like adenoma of the uterus, about which we had much to learn.

Dr. Lewers referred to a case of cancer of the cervix he had met with some years ago in which the clinical evidence of cancer was complete, and in which he therefore performed supra-vaginal amputation of the cervix. Sections of the cervix, however, when examined under the microscope, showed only glandular cavities lined by a single layer of columnar epithelium. Unfortunately the malignant nature of the growth was proved by recurrence, which took place about a year later, and of which the patient died.

Dr. Herbert Spencer was inclined to agree with Dr. Eden's description of the tumour as a fibro-adenoma and not malignant. The diagnosis of malignancy with the microscope was in these cases very difficult. Cases of adenoma which he had seen, which were undoubtedly malignant, had the glandular structures closer together, with less interglandular tissue than in the part of Dr. Eden's specimen he had examined.

Dr. Amand Routh had to thank Dr. Eden for his kindness in reporting on this specimen. Dr. Routh had some anxiety as regards the case, which he saw in consultation with Dr. Walker, of Hamilton Terrace. The lady was at or about the age of the menopause (forty-nine), and had had severe metrorrhagia for six months. A polypoid growth was found protruding from the cervix, and when subsequently removed was found to consist of a hard yet very friable growth, which he felt sure was malignant, and was very much surprised to get Dr. Eden's report that microscopically it was a simple adenoma. On reading the literature on the subject he found that most foreign observers considered that adenoma of the body of the uterus at or after the menopause was almost certainly malignant, and should be dealt with as such. Sir John Williams's views, as stated in his Harveian Lectures on "Uterine Cancer," were practically identical, and in consultation with Sir John he considered that both clinically and pathologically the adenoma was so surely malignant that hysterectomy should be performed. Dr. Routh has shown a case of malignant papilloma at this Society ('Obstet. Soc. Trans.,' 1897, p. 5), where after several curettings, the scrapings of which were always declared to be simple papilloma, he had finally removed the uterus, and it was then found that the papilloma, although still microscopically benign, had invaded the uterine tissues till it had reached the peritoneal investment. This and other similar cases seemed to show that at and after the menopause ordinarily benign tumours of the uterine body readily become malignant, and should be treated as such.

SPECIMEN OF CAST OF THE UTERUS.*

By T. W. Eden, M.D., M.R.C.P.

The patient was 22 years of age and had been married two years; seven months after marriage she had a premature labour; the fœtus, it was said, had been partly decomposed. She had also, apparently, contracted gonorrhœa soon after marriage. Menstruation was usually somewhat irregular, recurring every five or six weeks. She menstruated in August, September, and October, 1899, but from October 20th to December 7th, an interval of forty-seven days, no period occurred. On the latter date she passed the cast now shown, and she states that only slight bleeding and pain accompanied it. The case came under the observation of Dr. Amand Routh in consultation with Dr. Rozelaar, of Brondesbury, and the specimen was sent to me for examination. Dr. Routh found the pelvic organs to be normal.

When floated out in water the cast was seen to be nearly complete, and of the typical triangular shape. It measured $3\frac{1}{4}$ inches in length, by $1\frac{1}{2}$ inches in breadth, and rather less than a line in maximum thickness. It was pale in colour, except at the lower part, which was rather thicker and more vascular. Attached to the outer surface at the fundus was a short tag, which appeared to represent a cast of the interstitial portion of the Fallopian tube. It was thus apparent that in its naked-eye characters this cast differed very much from the decidual casts which were well known in connection with extra-uterine gestation. The latter were much thicker and more vascular, and frequently contained a considerable number of interstitial hæmorrhages, of which there were none in the cast now shown.

Microscopically it consisted almost entirely of inflam-

* Naked-eye and microscopic preparations shown.

matory tissue. There was no epithelium covering its surface, and no trace of glands could be detected in any part. Here and there patches of tissue closely resembling the normal stroma of the endometrium were found, and isolated clusters of large decidual cells were also present. It was therefore obvious that this cast differed as much in its microscopic as in its naked-eye appearances from a decidual membrane. The presence of a few isolated decidual cells was of no account in the case of a woman who had previously borne children or been pregnant. The patient had never suffered from dysmenorrhœa, and she stated that the passage of this cast had caused her little or no pain; the case could therefore not be regarded as one of membranous dysmenorrhœa. Probably it was inflammatory in origin, the result of some form of exfoliative endometritis.

The PRESIDENT noted that so careful an observer as Mr. J. W. Taylor had failed to discover any essential difference between a cast in membranous dysmenorrhœa and the decidua expelled in extra-uterine pregnancy.

Dr. ROBERTS asked Dr. Eden if there was any definite history of membranous dysmenorrhœa in the case. The cast was unlike that of most cases he had seen, as decidual cells were practically absent. He suggested it might be inflammatory in origin; in fact, he thought that in some cases of membranous dysmenorrhœa, not essentially primary, an attack of uterine or pelvic inflammation had subsequently been followed by membranous dysmenorrhœa.

PHOTOGRAPHS FROM A CASE OF PRIMARY CANCER OF THE FALLOPIAN TUBE.

By the PRESIDENT for Professor PAWLIK, of Prague.

IN relation to twenty-three cases of primary cancer of the Fallopian tube which I tabulated and reported before the Society two years ago ('Transactions,' vol. xl, p. 197) Professor Pawlik kindly sends me these photographs from

an unpublished case. The patient was a widow seventy years of age, so that in this case the age was the highest on record. Recurrence occurred two years after the removal of the diseased tube with the uterus, death following five months after the appearance of secondary disease. The removal of the uterus certainly insured the patient two years' immunity, as it was already infected.

Professor Pawlik furnishes the following short notes drawn up so as to correspond with my tables :

"*Age, married or single.*—70 years, widow.

"*Children.*—Ten.

"*Side of tumour.*—Right.

"*Chief symptoms.*—Hypogastric pains, sanious, serous discharge. Colpitis granulosa. Uterus enlarged. Curette, applied for diagnosis, brought away tissue of a malignant adenomatous type from one point, elsewhere the scrapings showed endometritis interstitialis.

"*Result of operation.*—Laparotomy, right salpingo-oöphorectomy, hysterectomy ; recovery ; recurrence after two years ; death two years and five months after operation.

"*Character of tumour.*—Right Fallopian tube in its external half enlarged to the size of a thick finger and filled with papillary carcinomatous growth. External wall presented a smooth surface. Ostium closed.

"*Other parts involved.*—Both ovaries atrophied ; left tube normal. Uterus enlarged ; the endometrium showed a polypoid hypertrophy. Microscopically only endometritis and metritis interstitialis was detected, without any traces of cancer. Thus the cancer found when the curette was used had been confined to a limited area of the endometrium now indeterminable, it did not extend into the deeper tissues, and was a secondary polypous cancer of the body of the uterus. The ligament of the ovary on the right (affected) side was enlarged to the size of a small finger, and microscopically disclosed also a similar inflammatory process."

The photographs represent the extirpated tube and

uterus, also a microscopic section of the growth in the tube, and the malignant tissue removed by the curette from the uterine mucosa. This very limited secondary deposit was a remarkable feature in the case.

Since my own tables were issued two new cases of primary cancer of the tube have been published in Danel's "Essai sur les Tumeurs malignes primitives de la trompe utérine," and two more by Fabricius in the 'Wiener klinische Wochenschrift,' No. 49, 1899, p. 1230, besides Dr. Hubert Roberts's second case ('Transactions,' vol. xli, p. 129) which, he informs me, died rather suddenly after repeated tappings on June 15th, 1899.

Professor Pawlik's case will, I understand, be shortly reported in full.

MACERATED FŒTUS REMOVED FROM THE ABDOMINAL CAVITY TWO MONTHS AFTER SPURIOUS LABOUR.

Shown by Alban Doran, F.R.C.S.

In this case, which I intend to report in full, the patient was a married woman aged 34. She had borne five children, all females. The last was born four years ago, and she had never miscarried. The last period occurred early in February, 1899, and the patient suffered much during pregnancy. At the end of October violent labour pains set in, followed by fever and great emaciation. Drs. Walter Tate and Hubert Roberts detected a fœtus, palpable through the abdominal wall and lying in a cyst which fluctuated but was resonant on percussion, owing to gases evolved in decomposition.

I operated on December 12th, 1899. The fœtus was extremely fœtid, and was a female, like all the other children of this patient; it weighed three and a half pounds, and measured eighteen inches. The sac was

developed from the posterior layer of the right broad ligament, so that the pregnancy was of the posterior ligamentary (J. W. Taylor) or retro-peritoneal type. It could not be removed, but was drained. A fæcal fistula developed at once, but now (January 3rd) the patient is in good health and has gained flesh. The placenta came away within ten days.

[Sequel : the patient died in the ninth week after operation ; a full account will appear in the ' Transactions.']

Dr. Cullingworth, knowing from experience how much the conditions militated against success in these cases of putrefying extra-uterine fœtus, congratulated the President on the favourable result of his operation. He had himself operated six times in cases of advanced ectopic gestation in which the child was dead. In two of these cases no decomposition had taken place, and the patients recovered ; in the other four the child was putrid, and the patients all died. He would be glad if the President would state the considerations that led him to leave the placenta.

Dr. John Phillips had operated on two similar cases, and at the present time had another under his care. In two of them a spurious labour had occurred, and in all of them there was distinct history of rupture early in the pregnancy. No difficulty with the placenta should, as a rule, be experienced where the fœtus has been dead more than a month. In his third case an increasing amount of fluid, as in the President's case, is one of the leading features.

Dr. Roberts asked Mr. Doran if he had been able to determine exactly the relations and origin of the sac which surrounded the fœtus? He had seen the case with Dr. Tate in the out-patient room at the Samaritan, and the fœtus and apparently loose bones could be plainly felt, and the placental mass then occupied the right side of Douglas's pouch. He thought that as the sac at the operation was thick, the fœtation probably was intra-ligamentary, and not the tubo-abdominal form, as described by Taylor in his recent book.

In reply the President assured Dr. Hubert Roberts that, as far as could be judged from clinical evidence and from what could be seen at the operation, the pregnancy was of the posterior intra-ligamentary type. The posterior layer of the broad ligament had been displaced by the ovum discharged into the meso-salpinx after rupture of the tubal sac. As the child grew the posterior pelvic peritoneum was steadily displaced upwards so as to form a thick membrane, investing the fœtus above and

anteriorly. He detected this displaced peritoneum immediately under the anterior parietal peritoneum, and on incising the former the fœtid contents of the sac began to escape. The edges of the incision in the peritoneal investment of the sac were afterwards stitched to the parietal peritoneum. In a pregnancy of this sort the lower posterior part of the fœtus and often the placenta comes into close relation with the rectum, hence infection from the gut and decomposition of the fœtus; whilst in the anterior intra-ligamentary variety the sac was far from the rectum, so that the retained fœtus often mummified. The diarrhœa which was noted during the later stages of pregnancy in this case was probably due to part of the placenta having grown over the rectum, as also occurs in true abdominal pregnancy. Freund of Strasburg had many years ago observed intestinal catarrh and infection of the sac when the placenta was inserted on intestine.* Extirpation of the sac, as advocated and practised in one operation by Dunning, would have been impossible in the President's case, since the base of the sac was practically the wall of the rectum. The placenta, though partially in a state of advanced decomposition, bled freely on the least attempt to detach it; as its position was entirely extra-peritoneal and the opened sac was easily accessible for dressing, there was no reason to run risks by detaching it during the operation. In reply to Dr. Cullingworth the President remarked that in withdrawing the fœtus the top of the cyst was torn, a dangerous accident which was always liable to occur, as such cyst-walls are very soft. Some of the fœtid contents escaped over the intestines above; fortunately in this case adhesions prevented the septic fluid from entering the general peritoneal cavity. The fœtus probably died very near term; the nails, etc., were well developed, but it was smaller, as usual, than an intra-uterine fœtus of the same age, and had lost much weight by maceration.

A CASE OF DOUBLE PYOSALPINX IN WHICH THE TUBAL SACS COMMUNICATED.

Shown by J. D. Malcolm, M.B., C.M.Edin.

Mr. Malcolm showed a double pyosalpinx, removed from a single woman thirty-three years of age. The patient's menstruation had always been excessive, and she had

* Freund and David Smart, 'Edin. Med. Journ.,' Sept.—Dec., 1893.

noticed a lump in the right groin about six years before her operation, but did not consult a doctor until October, 1899, when she was told she had a fibroid tumour. She then sought advice from Mr. Roxburgh Fuller, and was sent to Mr. Malcolm, who agreed with the diagnosis already given; but after the patient's admission to the Samaritan Free Hospital it was thought that the abnormal swelling contained fluid, and that it was probably ovarian in origin. The uterine cavity measured two and a half inches in length. The tumour, which was central in position, filled Douglas's pouch, and extended as high as the umbilicus.

During the operation the conditions were very puzzling. The swelling was obviously cystic, and when tapped a large quantity of fluid escaped, it being doubtful at the time whether this was pus or fluid from a dermoid tumour. The mass was removed with difficulty, being extensively adherent to the whole back of the uterus and broad ligaments, and to the bottom of Douglas's pouch. The ovaries were of normal size and shape, and though adherent were separable from the cystic mass. When removed this mass was rounded by adhesions, but Mr. C. Lockyer had carefully dissected the specimen, and had shown clearly that it consisted of a double pyosalpinx, the septum between the two sacs being perforated by an opening the size of a florin.

Mr. Malcolm referred to another very similar case, in which he had removed two large dilated tubes, forming a mass which filled the pelvis and rose above the level of the navel, in a girl aged twenty. An ovarian tumour was diagnosed in this case also. Mr. Targett found abundant evidence of tuberculosis in the tubes removed from that patient, and Mr. Malcolm thought it highly probable that the tubes now shown were also tubercular in origin, although this had not been demonstrated.

In both cases the patients were single women, and there was no doubt that they were virgins. In both the development of the disease was very slow, extending over six and two years respectively at least. The woman aged twenty

had a good deal of pain without any definite history of fever. The other had practically no pain, and was not ill in any way. The younger woman was operated on on February 3rd, 1899, and made a very good recovery, being quite well in June. The elder woman's operation was on November 14th, 1899. Recovery was uncomplicated. Recently she was gaining strength, but slowly.

The PRESIDENT said that Mr. Malcolm's case reminded him of a case reported by Paltauf in a paper called "Die Schwangerschaft in Tubo-ovarialcysten nebst gerichtsärztlichen Bemerkungen über den Fruchtabtreibungsversuch," 'Archiv für Gynäk.,' vol. xxx, p. 456. In this case pregnancy occurred in a dilated left tube which freely communicated with a dilated right tube, so that, according to Paltauf, there was a free passage all round from the uterine cavity along the tubes and back to the uterus. Paltauf held that the two cystic appendages were tubo-ovarian, but we believe less in tubo-ovarian cysts than we did in 1887. As two dilated tubes, whether hydrosalpinx or pyosalpinx, often touch each other behind the uterus, it seems reasonable to suppose that their walls may yield at the point of contact so that their cavities communicate. Such a condition is, however, without doubt very rare, though it must be occasionally overlooked, the fused tubes being liable to much laceration during an operation, so that their condition cannot be made out accurately afterwards. Mr. Targett's case was highly important.

Dr. CULLINGWORTH said that cases of greatly distended Fallopian tubes were always liable to occasion difficulty of diagnosis. In the case resembling Mr. Malcolm's, which he had described and figured in his 'Clinical Illustrations of the Diseases, etc., of the Fallopian Tube,' both he and Dr. Playfair had diagnosed cystic disease of the ovaries. In that case, as in many similar cases, sepsis and gonorrhœa could almost certainly be excluded, so that the probability of the nature of the morbid condition being tubercular was arrived at, independently of the evidence of the microscope, by the process of exclusion. Convinced that the disease was tubercular, Mr. Shattock had repeatedly examined sections from the wall of the tube in the expectation of finding evidence to that effect, but without result. Mr. Targett's recent communication would be remembered, in which he threw much new light on these cases. He told us also how he had obtained negative results until he examined a section outside the distended portion of the tube. Mr. Targett's observation was of great value and importance, and it was to be hoped Mr. Malcolm would have it in mind

when searching for evidence of tubercle in his own most interesting case.

Dr. Peter Horrocks said that tubal distensions simulated fibroid tumours of the uterus much more closely than they did ovarian tumours. He referred to a paper by himself, published in the 'Brit. Med. Journ.' in 1886, on the differential diagnosis between the two. He asked what symptoms had led to the suspicion of the tumour not being a fibroid? Had there been pyrexia or pain in between the periods, or growth, or fluctuation, or pressure symptoms, and had the size of the uterus been determined by sound or otherwise? In most of these cases of tubal distension there was menorrhagia, dysmenorrhœa, and sterility, all of which were characteristic of a fibroid. Moreover, as a rule, the physical characteristics of the tumour were more those of a solid than of cystic growth, and hence suggested fibroid rather than ovarian. He had seen cases and watched them for years under the mistaken idea that they were fibroid tumours of the uterus, and they had proved on operation to be distended tubes.

In reply, Mr. Malcolm said that the specimen shown was very closely attached to the uterus, but after the lower bowel had been well cleaned he recognised that the mass contained fluid, whereas when first examined it was so tense as to appear solid.

FOUR CASES OF RUPTURE OF THE UTERUS SUCCESSFULLY TREATED BY PACKING THE TEAR *PER VAGINAM* WITH IODOFORM GAUZE.

By Herbert R. Spencer, M.D., B.S., F.R.C.P.,

PROFESSOR OF OBSTETRIC MEDICINE IN UNIVERSITY COLLEGE, LONDON; OBSTETRIC PHYSICIAN TO UNIVERSITY COLLEGE HOSPITAL.

(Received December 22nd, 1899.)

(*Abstract.*)

The author gives notes of four cases of rupture of the uterus successfully treated by packing the tear *per vaginam* with iodoform gauze. They are the only cases in which he has adopted this method of treatment, and the only cases which he has known recover. All the others (about eight in number) have died in a few hours from shock and hæmorrhage or in a few days from sepsis. Twice he has performed abdominal hysterectomy with a fatal result. After quoting some remarks he made in the 'Obstetrical Transactions' for 1897 upon the great danger of the operation of abdominal hysterectomy in patients shocked by rupture of the uterus, the author expresses the belief that the mortality of rupture of the uterus may be lessened by the use of gauze packing. Having alluded to the advocacy of gauze packing by others, he expresses his own views, for the purpose of discussion, as follows:

In the treatment of rupture of the uterus—

(1) *Abdominal section* is rarely required, and almost solely in cases where the fœtus has passed completely or in great part into the peritoneal cavity. It should be performed rapidly under local infiltration-anæsthesia, and should be followed by

flushing of the peritoneal cavity with normal salt solution and by suture of the tear, if possible, or, if this be not possible, by packing the tear with iodoform gauze and draining by the vagina or abdomen.

(2) *Abdominal hysterectomy* is hardly ever necessary; when the broad ligaments are so much damaged as to endanger the vitality of the uterus vaginal hysterectomy should be performed.

(3) All incomplete tears implicating the broad ligament and most complete tears should be treated by *packing the rupture* per vaginam *with iodoform gauze* after removing clots and fluid blood.

Case 1.—Mrs. J. H—, aged 39, came to see me at University College Hospital in September, 1895. I found her about five and a half months' pregnant, with a peculiar growth on the cervix to be presently described, which I thought was probably a benign adenoma. She was kept under observation, and the growth did not appreciably alter in the course of the next two months. She was admitted to the hospital on November 22nd, 1895, when the following notes were taken.

There was no family history of malignant disease. The patient had been married twenty-three years, and had twelve children, all born naturally, head first, the last three years ago. In December, 1894, she miscarried at the fourth month, this being the third miscarriage in ten or twelve years. Since then she had been bleeding somewhat copiously every two or three weeks. In the last three months she had had no "period," though she had had blood-tinged discharge for the last two months. She complained of pain in the lower part of the abdomen and bottom of the back; she had lost flesh during the last eight months.

On examination the patient was found to be seven and a half months pregnant, the child being alive and in the first vertex position.

The perinæum had been torn. The vagina was of a

dusky red colour. The cervix was greatly enlarged. The anterior lip contained a growth which felt somewhat like a malignant growth, but it was firmer and smoother, and did not bleed at all on examination. Through a speculum the growth on the anterior lip was seen to be of a salmon-red colour, smooth on the surface and not bleeding on examination; it had a smooth rounded edge raised above the surface of the cervix. There was a slight "erosion" on the posterior lip, which had more the aspect of malignancy than the growth, and bled on rough examination. The colour of the tumour contrasted strongly with the dusky blue of the rest of the cervix. On wiping the surface of the tumour it was found to be pitted, and from each of the pits pus oozed on pressure to the extent of several drops; this pus was examined several times and always found to be sterile.

I have never seen a similar condition in the cervix; it resembled an ectropion of the mucous membrane, but was much larger. I thought the case was one of hypertrophy and inflammation of the mucous membrane of the anterior lip, aggravated by pregnancy.

During the next six weeks of the patient's stay in the hospital the cervix was daily swabbed through a speculum with 1 in 3000 sublimate solution. No bleeding occurred during this period, and this fact strengthened my belief that the growth was not malignant.

On January 4th labour set in; at 11 p.m. the pains became stronger, and occurred every ten minutes. The os admitted two fingers, but felt very rigid. Two doses of grs. xxx of chloral hydrate were given.

On January 5th at 5 a.m. the pains increased.

At 10 a.m. the os was $1\frac{1}{4}$ inches in diameter, exceedingly rigid.

At 4 p.m. the pains continued strong; the cervix was $2\frac{1}{4}$ inches in diameter.

At 5 p.m. the membranes were ruptured.

At 7 p.m. the cervix was a little more dilated, but was still rigid.

At 8 p.m. a large "caput" formed.

At 8.30 p.m. the patient suddenly collapsed without any increase of pain; a small amount of blood was found in the vagina. The forceps was applied and the child delivered without difficulty in twelve minutes. A considerable loss of blood occurred. The placenta was expressed in about twenty minutes.

At 9.30 the patient was very collapsed and pale. I was called to see her on account of her alarming condition. I found an extensive rupture of the left side of the cervix and lower segment of the uterus, admitting the half hand into the broad ligament, but could not make out that the peritoneal cavity was opened. There was also a slight tear on the right side.

I plugged the broad ligament with iodoform gauze, which was removed on January 7th, and the fundus of the vagina was daily swabbed with 1 in 3000 sublimate solution.

The uterus involuted slowly, the fundus being 3 inches above the pubes on the 21st of January.

On January 13th the growth on the cervix appeared to have diminished, and there was no pus.

On January 18th no thickening could be detected around the two tears.

On January 24th the fundus was still 3 inches above the pubes.

There was very slight fever in the puerperium, the highest temperature in the first week being 100·4°. The patient gradually recovered her strength, and left the hospital on January 30th.

On February 20th the growth on the cervix had increased somewhat in size; the uterus was freely moveable. The growth still felt too smooth for malignant disease, but there was a little ulceration between the edge of the growth and the anterior lip. It was decided to remove the cervix. The patient, however, through some misunderstanding, did not return to the hospital till compelled by pain and loss of blood on May 7th. The growth had

then increased to the size of a Tangerine orange, and the uterus was fixed by the extension of the growth into the tissues around it. There was, however, no bleeding on examination.

The patient died of hæmorrhage and cachexia on January 10th, 1897 (a year after delivery).

The growth on the cervix was examined with the microscope and found to be a glandular carcinoma. In the left side of the cervix was a gap about an inch wide, the edges of which were infiltrated with cancer; this marked the site of the tear, which opened up the broad ligament, but did not appear to have extended to the peritoneum. The growth had infiltrated the vaginal walls.

Case 2. (The detailed notes of this case have been unfortunately mislaid.)—Mrs. C—, a multipara, had a contracted pelvis with a true conjugate of 3½ inches. She had two sisters who also had contraction of the pelvis; on one of these (a little dwarf who has a true conjugate of 2½ inches) I have twice performed Cæsarean section.

Mrs. C— was delivered on October 29th, 1896, after a labour of sixteen hours' duration, which was terminated by podalic version on account of a transverse presentation with prolapse of the arm. The child, a male, was delivered alive, but the patient became greatly collapsed and bled a good deal afterwards, and on removing the placenta a rupture of the uterus was found extending into the broad ligament. I saw her within about half an hour of delivery, when she was suffering from hæmorrhage and shock. I passed my half hand into the tear, but did not find any opening into the peritoneum. The broad ligament was plugged with iodoform gauze, which was removed after a few days. The patient made an uninterrupted recovery, and is at the present time (three years later) in fair health.

Case 3.—F. H—, aged 39, was admitted to University College Hospital at 1.30 p.m. on February 23rd, 1898, with the following history:—She had had ten children (the

last thirteen months ago), but never had instrumental deliveries; her labours averaged about three hours in duration.

On the present occasion the first signs of labour occurred on the 21st, when she had pains which kept her awake all night; at 8 a.m. of the 22nd pains were occurring every half-hour, and at 2 o'clock in the afternoon every ten minutes. The patient had no one to send for assistance till the husband came back at 6.15 p.m., when she sent for a midwife; the pains were now very violent. A doctor was sent for, who diagnosed rupture of the uterus (the head presenting), and with the assistance of two other doctors turned and delivered the child about midnight. The patient had chloroform several times, but she says she felt the tear occur when the largest part of the child was passing (the tear was probably only *increased* at that time). Labour pains did not cease after the child was born for half an hour, when the placenta was removed by hand and an extensive rupture was found. She became collapsed and bled a great deal after the child was delivered, and was in great abdominal pain.

I saw the patient immediately after her removal in an ambulance to the ward (2 p.m.). She was extremely ill and blanched, the pulse very feeble, 115, the respirations 36.

The abdomen was considerably distended and very tender. The peritoneum evidently contained free fluid (blood). After drawing a pint of dark brown urine from the bladder the uterus could be felt quite hard, extending up about five inches above the pubes. The cervix was found to be torn away from the vagina, and on passing the hand through the rupture the bladder also was found to be separated from the uterus, leaving an extensive rent in the peritoneum; and there was also a longitudinal tear in the anterior and left part of the uterus extending above the internal os. A long glass Budin's catheter was passed into the peritoneum, and about two pints of fluid blood were squeezed out through it by pressure on the abdomen; then several large clots were removed from among the intestines

and more blood was squeezed out. When no more blood could be expressed, two long strips of iodoform gauze were introduced by means of long forceps into the peritoneum, and packed between the bladder and the uterus and into the tear, the intestines being held up with the fingers whilst this was done.

A hypodermic injection of morphia (miv) was given, and patient slept well during the evening and retained milk and barley-water in the stomach.

Next morning (24th) the patient was sick three times (temp. 99°, pulse 110). The catheter was passed every eight hours. The condition had markedly improved, and the patient from this time made steady progress to recovery. The plugs were removed on March 3rd and 4th ; they were offensive, and might with advantage have been removed earlier. The highest temperature for the first five days was 100·2° ; the highest temperature recorded during patient's stay in hospital was 101·8° (March 1st, 2nd, 3rd). After March 11th the pulse and temperature were practically normal, the highest temperature being 99·4° and most frequent pulse 88.

The patient left the hospital practically well on March 19th, 1898. The uterus still reached three and a half inches above the pubes. The tear in the uterus and vagina had almost healed. The uterus was fairly moveable. When last seen by the doctor who attended her, about a year later, the patient was quite well.

Case 4.—On the 21st of January, 1899, I saw at Bexley, in consultation with Dr. Donkin, Mrs. R—, a multipara (four children) aged 33, who had been delivered by version at 3 p.m. on the previous day. The version had been easy, and was performed under chloroform on account of shoulder presentation, the shoulder being at the vulva. The patient became extremely collapsed after delivery of the child (dead), and the placenta followed in five minutes. The hand introduced into the uterus on account of the bleeding was found to pass into the peritoneal cavity.

The shock was treated with brandy and Valentine's meat juice by mouth and rectum. The pulse varied between 130 and 160 during the night, and was very feeble and irregular; the patient vomited frequently. The temperature, at first subnormal (97·2°), rose to 99·4°, at which height it remained when I saw her at midday on January 21st, nearly twenty-four hours after the accident. The patient was still very collapsed and extremely pale, the pulse being very feeble and 180 to the minute. The abdomen was tender and a little distended; fluctuation could be obtained over the lower part. A piece of membrane, slightly offensive, was hanging in the vagina and was removed, and the vagina was scrubbed with 1 in 3000 sublimate solution. The patient having been drawn over the edge of the bed in the dorsal position, the hand and forearm, carefully disinfected, were passed into the vagina. The uterus was found to be torn away from the vagina and bladder anteriorly, and the left side of the front wall of the uterus was torn through nearly up to the fundus. Small clots were withdrawn by the hand from the peritoneal cavity, and a long rubber tube three quarters of an inch in diameter was passed into the peritoneum, and by pressure on the abdominal wall a large quantity of fluid blood was squeezed out through it. The operation was not very painful, and the patient felt much better and freer from pain when the blood had been removed from the peritoneum. When no more escaped a long piece of iodoform gauze about five inches wide was passed into the peritoneal cavity as high as the top of the tear in the uterus. The lower end was left hanging out of the vagina. The pulse improved rapidly, falling to 120 and 100, at which latter frequency it remained till February 3rd, and gradually fell to normal a month after the accident. The temperature reached 101° on January 26th, and 101·4° on January 30th, and 101° on February 2nd; otherwise the temperature was about 100° till February 6th, was continuously below 100° after February 7th, and fell with the pulse to normal at the end of four weeks.

The lochia were free and not offensive.

The gauze was removed on January 26th, and boric acid douches at low pressure were given. The patient made a very good recovery, and when I examined her on April 27th the uterus was freely moveable, and the scar was quite healed and had only a very little thickening around it.

I have just heard from Dr. Donkin that the patient remains quite well (December 22nd, 1899).

These four cases of rupture of the uterus are the only ones which I have treated by gauze packing, and are the only cases which I have known recover. All the others (about eight in number) have died within a few hours from shock, or a few days from sepsis. Two of these fatal cases I treated by abdominal hysterectomy; of these, one (with extra-peritoneal treatment of the pedicle) died on the operating table, the other (abdominal pan-hysterectomy) died shortly afterwards. This experience led me, in speaking on a case of a ruptured uterus treated by abdominal hysterectomy, shown to this Society in October, 1897, by Dr. John Phillips, to remark that "abdominal hysterectomy was, speaking generally, too severe an operation for patients already shocked by rupture of the uterus. Cases in which the child had escaped into the abdomen required abdominal section, and those in which (as in Dr. Phillips's case) the broad ligament had been torn across, required hysterectomy; but in such a case vaginal hysterectomy was preferable, being a simpler and quicker operation and attended by less shock." ('Obst. Trans.,' vol. xxxix, p. 263).

In my remarks on Dr. Phillips's case I cited two of the above cases in which I had packed the tear with iodoform gauze, and recommended this method of treatment. In 1898 Mr. Mayo Robson alluded to my cases without mentioning my name, and himself gave notes of a successful case ('Practitioner,' 1898, vol. lxi, p. 26). With this exception I am not aware of any publication upon the use

of iodoform gauze packing for rupture of the uterus in the literature of this country, and I have thought, therefore, it might be useful to bring the subject before our Society for discussion.

On the Continent this method of treatment has been recommended by Leopold ('Archiv für Gynäkologie,' 1890, Bd. xxxvi, p. 324); Piskaçek ('Beiträge zur Therapie und Casuistik der Uterusrupturen,' Wien, 1889) and Bar ('Le Progrès Médical,' 1899, No. 28). Leopold makes the suggestion that after abdominal section it is sometimes better to pack and drain with gauze than to remove the uterus, and the suggestion seems to me to be a valuable one. But the mere operation of opening the abdomen is not unattended by shock when performed upon a patient suffering from rupture of the uterus, and it necessitates the administration of an anæsthetic. Abdominal section may be necessary in some cases when the child has escaped into the abdomen; but even then it will usually be advisable, if the shock be great, to wait until the patient has recovered; and while waiting it will be advisable to pack with iodoform gauze if bleeding be still going on. I attach great importance to the removal of all blood from the peritoneal cavity by squeezing it through a long, thick rubber or glass tube passed with the hand through the tear, and by removing clots with the hand. And it might be beneficial to flush out the abdomen through the tube with salt solution. The gauze should be left in for from six to ten days, and gentle, mild vaginal douches should be subsequently employed. I believe that the mortality of rupture of the uterus may be lessened by the method of treatment advocated above, and I shall be glad to hear the opinions of others who have experience of this terrible accident.

My own views, for the purpose of discussion, may be briefly stated as follows:

In the treatment of rupture of the uterus—

1. *Abdominal section* is rarely required, and almost solely in cases where the fœtus has passed completely or

in great part into the peritoneal cavity. It should be performed rapidly under local infiltration-anæsthesia, and should be followed by flushing of the peritoneal cavity with normal salt solution and by suture of the tear, if possible, or, if this be not possible, by packing the tear with iodoform gauze and draining by the vagina or abdomen.

2. *Abdominal hysterectomy* is hardly ever necessary; when the broad ligaments are so much damaged as to endanger the vitality of the uterus, vaginal hysterectomy should be performed.

3. All incomplete tears implicating the broad ligament and most complete tears should be treated *by packing the rupture* per vaginam *with iodoform gauze* after removing clots and fluid blood.

The PRESIDENT observed that absorption of iodoform caused rapid pulse, which is very confusing, as it may be taken as a symptom of sepsis. He would like to hear Dr. Spencer's opinion on this point. The President had already noted very rapid pulse in a case where he packed a very vascular irremoveable capsule, after enucleation of a broad ligament cyst, with iodoform gauze; the pulse was alarmingly high for a time, but there was no evidence of septic infection, and the pulse fell after removal of the gauze. Many foreign authorities objected now to iodoform or any other chemical antiseptic agent in packing wounds and capsules, relying on sterilized gauze. Did Dr. Spencer hold that the iodoform in gauze was an active antiseptic germicide agent?

Dr. PETER HORROCKS thought that a very strong distinction should be made between cases of laceration of the cervix and rupture of the body of the uterus. In two of Dr. Spencer's cases the laceration had not penetrated the peritoneal cavity, and had been confined apparently to the cervix as far as the internal os. Such cases were not uncommon, and often did well without any gauze packing, or indeed without any treatment at all, and the chief point was to stop hæmorrhage and see that everything was done aseptically. The cases in which the peritoneal cavity was opened by the rupture were, as a rule, much more severe and much more dangerous. He had had several cases, and the results had been highly satisfactory in recent years. He attributed this not alone to the packing by gauze, but to the fact that the labours had been conducted aseptically by the accoucheur, and so the parts had not become

septically contaminated before treatment. He gave details of a case seen many years ago with the late Dr. Wilton and his partner Dr. Bosworth, of Sutton. It was a case of difficult transverse presentation in which the uterus ruptured during delivery, the rent extending from the cervix up to the body of the uterus, opening the peritoneal cavity. When he arrived the intestines were in the vagina. They were washed and put back, and the rent was sewn up, but the patient died from peritonitis in about forty-eight hours. This was in the pre-aseptic days; but a few years ago he saw a case of rupture of the uterus with Dr. Henry of Lewisham where the rent was due to precipitate labour, and where the tear was so extensive that it was easy to pass the whole hand into the peritoneal cavity. In this case he put in two silkworm gut sutures, so as to draw the gaping wound together somewhat, and then he packed with sal-alembroth gauze after washing out with a solution of Tinct. Iodi, a drachm to one pint. Thinking that the gauze would not only drain the peritoneal cavity, but also would suck up the lochia, he recommended the removal of the gauze and washing out with the iodine solution every twelve hours for the first few days, and once a day afterwards. This was done under chloroform every time, and the patient made a most excellent recovery without pyrexia or offensive discharge. One of the stitches, however, gave trouble, in that it had to be removed under an anæsthetic some nine months afterwards. Dr. Henry had published the case in the 'West Kent Med.-Chir. Soc. Trans.' Since then the lady had been confined of a living child, which with Dr. Henry he had brought on at the eighth month fearing that the old rupture might give way, particularly as the patient nearly always had large children. He gave details of three other cases of grave rupture of the uterus penetrating the peritoneal cavity, in all of which sal-alembroth gauze was used to pack with, and Tinct. Iodi solution had been used as a douche. In each case the gauze was removed every twelve hours for the first few days, and every twenty-four hours for the next few days, and each patient had made an excellent recovery. He thought Dr. Spencer had left the gauze in too long, and that it rapidly became thoroughly soaked with lochia, when these were abundant, as during the first few days after labour. Moreover, there was the danger that the gauze might become adherent to the intestines, and so cause trouble on trying to remove it. He did not think hysterectomy, either abdominal or vaginal, was to be recommended in rupture of the uterus, when everything in connection with the labour had been conducted aseptically. He thought the best treatment in cases which were not capable of being treated in the way already mentioned, was to open the abdomen and sew up the tear with sterilised silk. He gave details of a case in which he had done

this successfully. The rent was along the anterior wall of the uterus, and extended from the os internum upwards. The lady was under the care of Dr. Shadwell, of Walthamstow, and she made a good recovery, although about the tenth day the whole abdominal wound gave way, and the bowels protruded during a severe fit of coughing soon after the removal of the stitches. Dr. Shadwell washed the bowels with boracic lotion, replaced them in the abdomen, and put in some silver wire sutures, and the patient did well. Finally, he did not think any special kind of gauze was essential. So long as it was aseptic that was probably enough. He had never used anything but sal-alembroth gauze himself, and he saw no reason to change it for iodoform gauze.

Dr. Lewers said he had had a case of rupture of the uterus at the London Hospital about eighteen months ago in which a method of treatment similar to Dr. Spencer's was adopted. The rupture was one through the cervix posteriorly into the peritoneum. Iodoform gauze was packed into the rent so as to project into the peritoneal cavity, and it was left there for some days. The patient was several times in an extremely critical condition during the first week, with very rapid feeble pulse and other alarming symptoms, but she eventually recovered. He noticed that in one of Dr. Spencer's cases he had observed exudation on pressure of puriform fluid from several openings on the surface of a cervix, which ultimately proved to be the seat of malignant growth. He had noticed the same phenomena for the first time some five years ago, and had since noticed it in other cases of cancer of the cervix. He was now accustomed to look upon the sign as a valuable indication of cancer of the cervix. Referring to the material used for packing into the peritoneum, either in cases of complete rupture of the uterus or in cases of abdominal section, he believed that the iodoform gauze commonly supplied varied a good deal in strength, sometimes, for instance, being much yellower than at other times. Except when the less highly iodoformed gauze was employed he was sure there was a good deal of danger of iodoform poisoning, and of late he had used carbolic gauze in the peritoneum with satisfactory results in cases where some kind of gauze drain was required.

Dr. Herman said that suture of a ruptured uterus was useless unless the edges of the wound were brought accurately together throughout the whole length. One or two sutures far apart were worse than useless, for the spaces between them might form pockets in which secretions might be retained and decompose. In cases in which complete suture of the wound could not be done, he thought packing with iodoform gauze was the best practice, and he congratulated Dr. Spencer upon his successful application of it. If the rent was so situated that

packing with gauze was impracticable, he thought vaginal hysterectomy would give the patient the best chance. The vaginal extirpation of the puerperal uterus had not been done until recently, probably because most obstretricians, as he himself, had supposed that the removal of the uterus immediately after delivery would be a difficult and dangerous thing; but those who had done it had found it a very easy operation.

Dr. Drummond Robinson was much interested in Dr. Herbert Spencer's paper, and also in the reports of instances of successful treatment of the ruptured uterus mentioned by other speakers. His experience of this condition was not large, but as he thought that every addition to our knowledge of the subject was valuable, he would mention his cases. He had had three cases of ruptured uterus under his care. In one case the patient died within a couple of hours of a complete rupture of the uterus. The other two cases recovered. The first of these was an incomplete rupture into the left broad ligament, the result of a neglected shoulder presentation. No suitable drainage material was at hand, so the rupture was not packed with gauze or otherwise drained. When seen again the patient had exhibited no bad symptoms, and she was therefore not disturbed. She made an uninterrupted recovery. No drainage of any sort was used. There was very little hæmorrhage at the time of or after the rupture. The second successful case, which occurred some two years ago, was that of a multipara of about forty. Labour had been tedious, and forceps were at length used by the medical man in attendance, and the child delivered (dead) without difficulty. The patient (always anæmic) now became markedly collapsed, and on vaginal examination a piece of material (looking like fœtal membranes) the size of the hand was seen protruding from the vulva. On tracing this upwards it was found to be a flap of peritoneum, which projected through a large rupture in the anterior wall of the lower uterine segment. The cervix was completely split anteriorly up to the rupture in the lower uterine segment. The bladder was separated from the supra-vaginal portion of the cervix uteri, and was uninjured. The flap of peritoneum was cut off, and the rupture packed with cyanide gauze; this was changed after three days. The patient was very ill for nearly a fortnight, but subsequently made a good recovery, and has since given birth to another child quite normally. A few days after the rupture a sinus developed at the umbilicus from which serous fluid exuded. This healed up in a few days.

Dr. Herbert Spencer, in reply, said that two of his cases were complete ruptures and two incomplete. The distinction between laceration of the cervix and rupture of the body of the uterus could not be sharply drawn. Most cases of the latter did actually involve the cervix. Slight cases of laceration of

the cervix up to or even beyond the vaginal insertion were of small importance; but where, as in his two cases, the cervix and lower segment were lacerated so extensively as to admit the half hand into the broad ligament, and there was much hæmorrhage and shock, the danger was great. The extent of the laceration in the uterus was of less importance than the extent of the laceration of the vessels and tissue of the broad ligament. He had known death to occur where a cervical laceration was so short as not to involve either os. It was his experience and belief that these severe incomplete lacerations actually killed more women than the complete. He wished again to emphasise the great danger of abdominal section in rupture of the uterus, and agreed with the remarks of Dr. Herman as to the uselessness of partial suture. He considered it undesirable to inject an irritant like iodine solution into the peritoneal cavity, and dangerous to give chloroform and change the gauze every twelve hours; iodoform gauze might be left in for six days or longer. The cases related by other speakers strengthened his belief in the value of gauze packing. Though iodoform gauze was not free from risk, he believed, in anæmic cases like those under discussion, it was less dangerous than cyanide or carbolic gauze, or even sterilised gauze, which would not long remain aseptic in the vagina.

ANNUAL MEETING.

FEBRUARY 7TH, 1900.

ALBAN DORAN, F.R.C.S., President, in the Chair.

Present—54 Fellows and 4 Visitors.

Books were presented by the St. Bartholomew's Hospital Staff and the Leigh-Browne Trust.

E. Collingwood Andrews, M.A., M.D.Cantab., and Sydney Henning Belfrage, M.B.Lond., were admitted Fellows of the Society.

The following gentlemen were proposed for election :—Hugo Adolf Levison, M.D., and Frank Edward Taylor, M.A., M.B.

SPECIMEN OF FŒTUS THORACOPAGUS.

(See Plates II, III, and IV.)

Shown by Dr. AMAND ROUTH.

THE clinical notes on the birth of this homologous twin (Thoracopagus) are supplied by Dr. H. W. Abbott.

The mother of the twin was a primipara, who conceived two months after marriage, the pregnancy having lasted thirty-two weeks and three days, dating from the last day of the previous "period." She consulted Dr. Abbott when twenty-eight weeks pregnant for unusual size of the abdomen.

During the labour examination showed that a head was presenting in the first position of the vertex. The os was fully dilated ten hours after onset of labour. The second stage was slow, but the head came partially through the vulva, and was encouraged to rotate forwards in the intervals of pains. At this time there were facial contractions from efforts to breathe, and as the face was becoming cyanosed, Dr. Abbott released the two shoulders and then found the hands of the second child, and not knowing the twins were conjoined, he endeavoured to push the hands back whilst he delivered the first child. Finding the first child immobile he administered chloroform, and discovered that the bodies were joined. He thought of dividing the twins at their line of union, but found there was too little room to work in, so he endeavoured to deliver the second head, which was firmly pressed against the thorax of the first child. He accomplished this by drawing on the head and arms of the first child, and the twins were finally delivered. The perinæum, which was torn through the sphincter ani, was sutured, and healed well, and the patient convalesced normally. The placenta was single, and being partly adherent, had to be extracted manually. The umbilical cords were united four inches from their insertion into the placenta.

There is nothing of moment in the personal or family history of the patient except that her father was one of triplets.

Dr. Arthur Giles said that the condition of the intestine in these cases was of greatest interest. From just below the duodenum to a point some distance above the cæcum the intestines of the two fœtuses were fused, remaining distinct above and below. This fused portion corresponded to the original mid-gut, which remained open and in direct continuity with the yolk-sac for some time after the fore-gut and hind-gut had become separated off. In the normal fœtus the mid-gut formed the principal part of the anterior limb of the long intestinal loop, the bend of which was the last part to remain attached to the umbilicus, and was sometimes found permanently drawn

out as Meckel's diverticulum. The globular dilatation observed in the specimen at the posterior junction of the fused with the separate portions of the gut evidently corresponded in position with a Meckel's diverticulum. The great interest of this condition consisted in this, that it formed a striking proof of the fact that in the case of thoracopagous twins the two embryos had developed from a single ovum.

Report on Specimen of Fœtus Thoracopagus, shown by Dr. Amand Routh.

(See Plates II, III, and IV.)

The specimen is one of homologous female twins, weighing 9 lbs. 7 oz., united along its anterior aspect by fusion of the ribs, commencing between and just below the level of the manubria sterni as far as the umbilicus. It belongs to the group known in teratology as Emprosthozygosis, and to the sub-order Thoracopagus. The double skeleton is complete with the exception of the fused ribs. Beyond extroversion of the intestines at and below the umbilicus, there were no other deformities.

The left fœtus is the larger, measures 17 inches in length, whilst the right is only $15\frac{1}{2}$ inches long.

The left head has a biparietal diameter of $3\frac{1}{2}$ inches, and a circumference of $12\frac{1}{4}$ inches, compared with 3 inches and 11 inches on the right side.

There is a single umbilical cord containing two arteries and two veins, but these vessels were not able to be traced, being spread out over the sac of peritoneum which covered the extroverted intestines.

There is one thoracic cavity containing four lungs, each in its own pleural cavity. The one on the extreme right is three-lobed, and the one on the extreme left is two-lobed. The two internal lungs are less well developed. All the lungs were completely collapsed.

There are two complete hearts, united at their bases by a solid band. There is only one pericardial sac. The heart of the left fœtus is twisted to the left, so that its posterior surface faces more or less anteriorly. The band

of union between the cardiac bases is solid, and unites the muscular walls of the right auricle of the left fœtus with the left auricle of the right fœtus. The cardiac vessels are normal, and the foramen ovale and the ductus arteriosus of each side are well marked.

There are two thymus glands.

There is a single abdominal cavity, with a single peritoneal sac. There are two livers, united by their posterior borders, their inferior surfaces being apposed, each showing a collapsed gall-bladder. When the livers are viewed from the front they are seen to be lying so that the upper surface of the liver belonging to the left fœtus faces anteriorly, behind which is the liver of the right fœtus with its upper surface facing posteriorly.

On each side of the fused livers, at the angle of their fusion, is a perfect stomach, passing inwards along the under aspect of the line of fusion in the space between the livers, uniting there to form a common duodenum, which is continued by twenty-two inches of small intestine (? jejunum) ending in a remarkable intestinal sac, more or less spherical in shape, measuring about three and a half inches across, containing meconium.

From the two sides of this sac, equidistant from the point of entry of the single small intestine, two other pieces of small intestine (ileum) issue, 10 inches long on the right side and 14 inches long on the left, terminating on each side with a well-formed cæcum and vermiform appendix. From the cæcum, on each side, the large intestine, distended with meconium, is continued for 14 inches, and terminates in a rectum, of which the anus is perforate in each fœtus.

Each fœtus has two kidneys, two ureters, and two adrenals. There are also two spleens, the left double the size of the right, situated normally.

The uterus, ovaries, and Fallopian tubes, as well as the bladders, are complete in each fœtus.

Amand Routh.

C. Hubert Roberts.

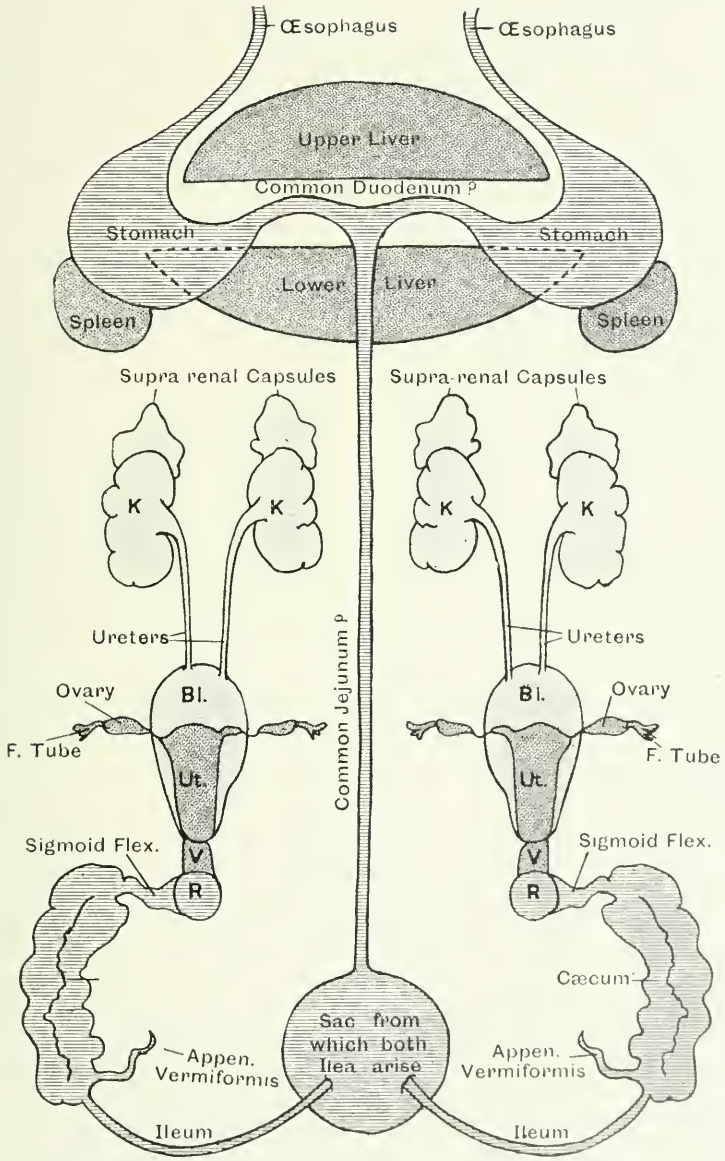

Drawn by C. Hubert Roberts.

Illustrating Dr. Amand Routh's Specimen of Fœtus Thoracopagus.

Engraved and Printed by Bale and Danielsson, Ltd.

DESCRIPTION OF PLATE III.

Illustrating Dr. Amand Routh's specimen of Fœtus Thoracopagus.

1. Common pericardium for the fused hearts.
2, 2. Lungs.
3, 3. Right auricles.
4, 4. Thymus glands.
5. Left auricle fused to the right auricle of the other side, but not communicating with it.
6, 6. Left ventricles, normal.
7, 7. Right ventricles, normal.
8, 8′. Upper and lower livers, fused.
9, 9. Spleens.
10, 10. Stomachs.
11, 11. Gall-bladders.
12. Umbilical cord (two arteries, two veins).
13. Umbilical veins.
14. Common duodenum.
15, 15. Sigmoid flexures.
16. Common jejunum.
17, 17. Vermiform appendix on each side.
18, 18. Cæcum on each side.
19, 19. Ileum.
20. Rounded sac into which common jejunum opens, and from which ilea arise.
21, 21. Genitals, both ♂.

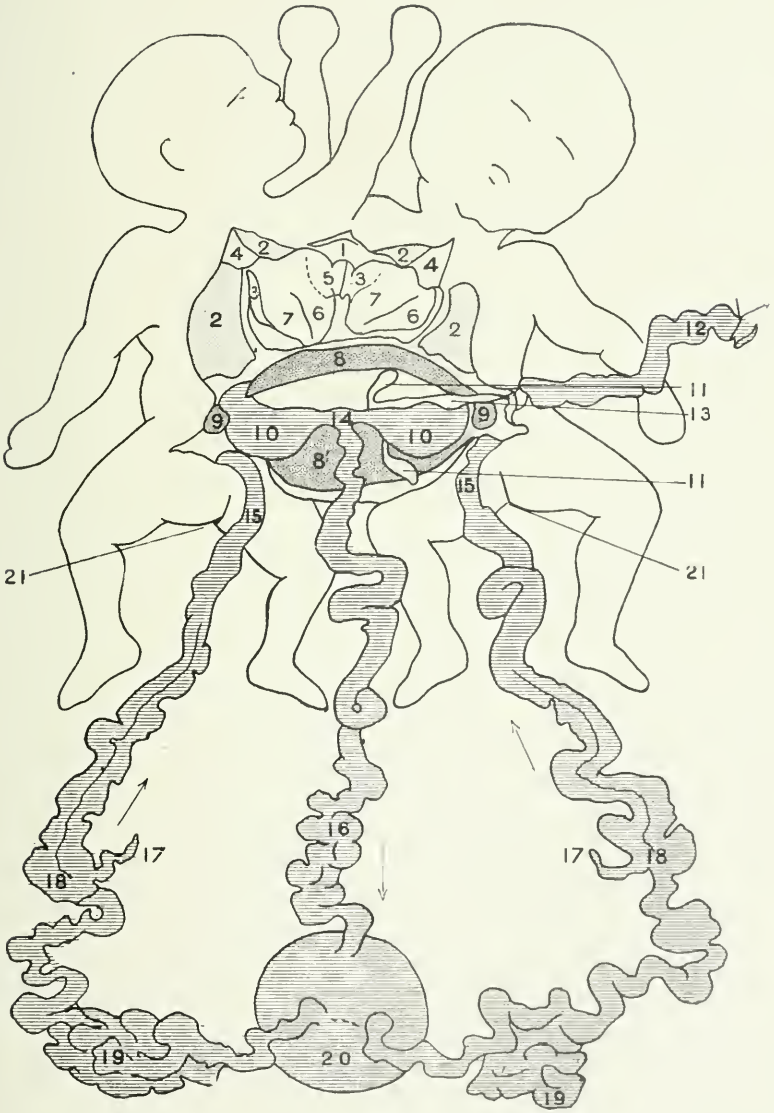

Drawn by C. Hubert Roberts.

Illustrating Dr. Amand Routh's Specimen of Fœtus Thoracopagus.

Engraved and Printed by Bale and Danielsson

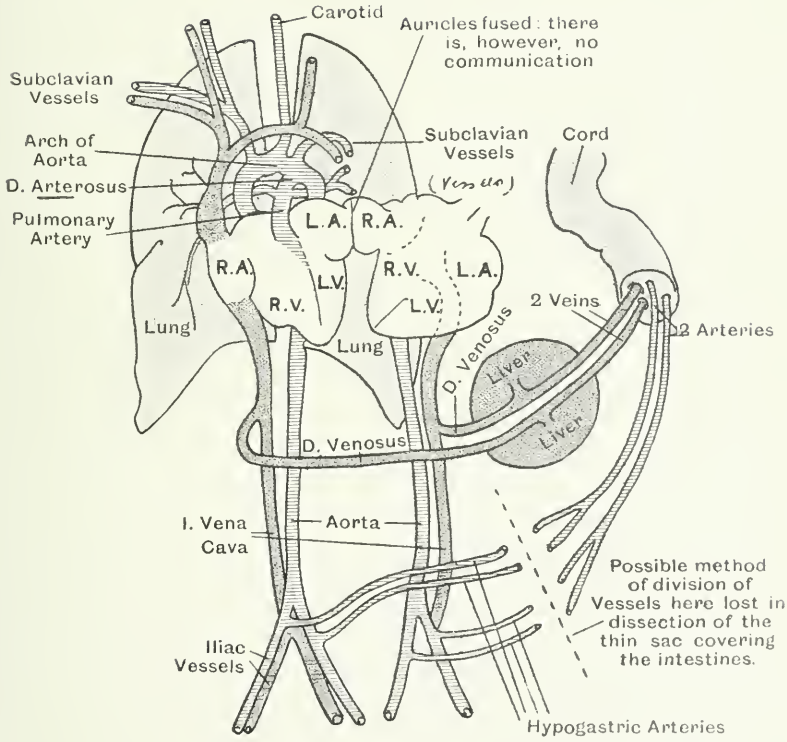

Drawn by C. Hubert Roberts.

Illustrating Dr. AMAND ROUTH's Specimen of Fœtus Thoracopagus.

Engraved and Printed by Ba[illegible] and Dan[illegible]son, Ltd.

Dr. Roberts said he was much interested in the specimen, and had had the advantage of dissecting it with Dr. Routh. The marked peculiarities were the fusion of the hearts, livers, and the intestinal tract. The fœtuses were homologous female twins, therefore of the same sex, and appeared to be joined by their visceral laminæ above the umbilicus. Looking over the specimens at the Royal College of Surgeons, Teratological Series, all the nine specimens were females, and two exhibited almost similar conditions of the intestinal tract (Nos. 112, 113), viz. there were two livers more or less fused, two stomachs, two duodena, the latter entering a common jejunum which passed into a common rounded sac, from which two ilea then arose, passing to a cæcum on either side, each of which communicated with the rectum which each fœtus possessed. The common sac was of great interest, and he thought, with Dr. Giles, it possibly represented a diverticulum of the ileum, but in Dr. Routh's specimen it seemed to occur at the origin of the ilea, not in the lower part. In one specimen at the College of Surgeons the cord had two umbilical veins and four arteries (No. 112). The hearts in the specimens at the College varied; some were separate, others fused; in one case (No. 117) the hearts were placed one above the other, the upper heart giving an aorta to either fœtus. Extroversion of the viscera also occurred frequently, and one or other fœtus might be deformed. The anterior method of junction of the two bodies = parazygosis, sub-variety = thoracopagus, appeared to be the commonest variety of duplicity in the human species.

The President suggested that there was quite enough material in the Society's 'Transactions' to make up a first-class English work on teratology. Many valuable specimens of monsters were to be found in the museums of the Royal College of Surgeons and the medical schools in London. The published and unpublished cases collected into one volume would form a work rivalling and perhaps excelling the standard monographs of Förster, Ahlfeld, and Barton Cook and Hirst. The work might be divided into two parts. The first would be scientific, being a systematic description of the different types of monsters and malformations, including comments on the embryological, anatomical, and morphological aspects of each type; the second part would be obstetrical, treating of difficult labour due to monsters, and of the phenomena of twin-gestation and hydramnion in relation to certain special forms of monstrosity.

SPECIMEN OF PRIMARY SOLID CARCINOMA OF THE OVARY.

(See Plate V.)

Shown by W. S. A. Griffith, M.D.

In August, 1897, a lady aged 58 was seen by Dr. Griffith.

Menstruation commenced at 17, was scanty and irregular until marriage. She had had two children without complications, the younger being thus 34 years of age. No miscarriages.

Since the birth of the children menstruation had been normal and quite regular until about the age of 47, when menorrhagia with clots commenced, and continued until the cessation at 53.

In December, 1896, she broke a leg, and in April, 1897, hæmorrhage from the vagina began without any ascertained cause, which continued with occasional cessation for a day or two until her visit to Dr. Griffith. The quantity was always slight, less than menstrual, one diaper a day being usually sufficient. There was no pain or leucorrhœa. Her weight was as usual, and general health good.

At the age of 19, and once since, Sir James Paget had removed some small nodules from the left breast.

The uterus was found to be a little enlarged by a small fibroid of the posterior wall; the cervix quite healthy.

On September 8th the uterus was dilated and explored, and found to be empty; it was curetted and swabbed with tincture of iodine. Recovery uneventful.

1898.—In May she was seen again. Slight and irregular hæmorrhage began a few weeks after the curetting, lasting a few days, with intervals of two or three weeks. No other discharge or pain; the uterus appeared to be a

DESCRIPTION OF PLATE V.

Illustrating Dr. W. S. A. Griffith's specimen of Primary Solid Carcinoma of the Ovary.

FIG. 1.—*a* = columnar-celled growth invading ovarian stroma.

FIG. 2.—*a* = ovarian stroma. *b* = acini lined by columnar epithelium.

½-in. Objective.

FIG. 1.

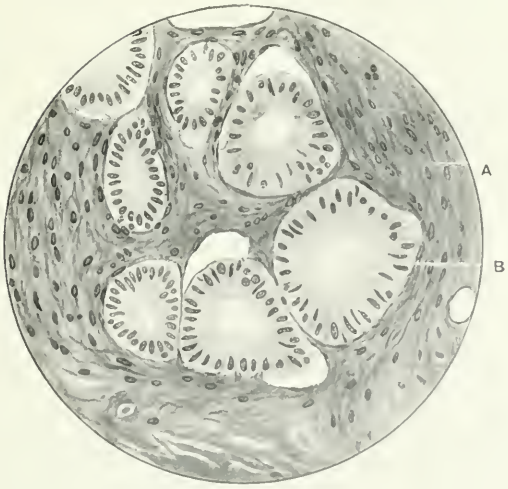

⅛-in. Objective.

FIG. 2.

Illustrating Dr. W. S. A. GRIFFITH'S Specimen of Primary Solid Carcinoma of the Ovary.

Drawn, Engraved and Printed by Bale & Danielsson.

little larger from the growth of a second nodule, but this was not certain.

1899.—In October she returned to London saying there was a definite enlargement of the abdomen; her health had been and was good, and there had been no hæmorrhage since July, 1898.

Dr. Griffith found a large solid tumour in the abdomen, which appeared to have originated in the right ovary, the uterus being displaced to the left and not directly connected with the tumour. The tumour, having developed since her visit fifteen months previously, was believed to be a sarcoma and its removal was advised.

On November 2nd the tumour was removed by Dr. Griffith without any important difficulty; there was no excess of peritoneal fluid; the left ovary was small and healthy, and was removed; the uterus was so nodular and suspicious in appearance, that after some consideration it was removed by supra-vaginal amputation. This part of the operation took much longer than was expected, the tissues being very soft; though there was no loss of blood, the pulse failed, and she survived the operation only two days.

Examination of the uterus afterwards showed that it might have been left safely, one or two of the fibroids showing evidence of active growth, the others being quite senile.

The tumour, which involved the whole ovary, was of the size of a child's head, nodular on the surface, firm and without cysts, and had the general shape of the adult ovary.

Preserved it measures 5 inches by 5 inches by 4 inches.

On section it presents a firm white reticulated structure, the spaces being usually gelatinous, and yellowish or greyish in colour.

The white reticular bands present the usual characters of the ovarian stroma, the recent and actively growing parts being spindle-celled, the older parts fully developed connective tissue, and the yellow and grey gelatinous

parts being the same in an active state of softening and liquidation of the stroma.

The cells are contained in alveoli very sparsely scattered in the stroma, some quite minute, and others of considerable size. The earliest stage of development is from simple tubes lined by a single layer of columnar epithelium, well formed, with a central lumen.

The epithelium and tubes, proliferating, become closely packed, so that some alveoli are filled with masses of cells and closely pressed tubules, still retaining the columnar types of cells; while in others the cells are so compressed, and have proliferated so rapidly, that they have lost more or less completely their columnar shape, and are oval or even spheroidal in shape. A section from such a place would have left the exact nature of the tumour in some uncertainty; such structures are usually described as "scirrhus."

Solid carcinoma of the ovary is a rare disease, though carcinomatous masses, like dermoid patches in ovarian cysts, are not uncommon.

It is said to be usually bilateral, and that ascites develops early; in this case the other ovary is senile and presents no signs of a similar growth, and there was no accumulation of peritoneal fluid.

The combination of such diverse histological characters in a single specimen, developing at about the age of 60, appears to be unusual. Pfannenstiel, in Veit's 'Handbuch,' Band iii, p. 346, in his account of carcinoma of the ovary, describes two forms, the medullary occurring at an early age (Olshausen quotes one of eight years of age), and the scirrhus at advanced age. Had not sections been made from different parts of the tumour, it would have been described as scirrhous or spheroidal-celled carcinoma.

Dr. Griffith is indebted to Dr. Hubert Roberts for the excellent drawing of the specimen.

A MULTILOCULAR CYST OF THE OÖPHORON.

Shown by Cuthbert Lockyer.

Mr. Cuthbert Lockyer showed a multilocular cyst of the oöphoron, which had burrowed into the right mesometrium. The cyst contained sixteen pints of thick glairy fluid, had very thick walls, and was made up of four separate loculi. The ovarian fimbria was eight inches long, extending around one third of the circumference of the tumour. He remarked that cystic adenomata of the ovary were rare in this subserous situation.

Three cases were quoted from the President's writings, and, referring to 250 ovariotomies performed by Olshausen, in which forty-six of the cysts were intra-ligamentary (excluding the parovarian variety), Mr. Lockyer stated that a great number of these seemed to be hilum cysts, and not arising, as in his specimen, from the egg-bearing portion of the ovary. A drawing of the specimen in the recent state accompanied the cyst.

The President held that much was yet to be learnt about broad ligament cysts. He had known papillomatous cysts of that class to prove highly malignant, whilst others never recurred. He had found that the fluid in the common "parovarian" cyst was clear and non-albuminous, as was commonly taught. In one case, however, the cyst seemed to be a dilated lymph-channel, containing several pints of extremely coagulable fluid, whilst it possessed no true wall, the broad ligament forming its capsule, or rather its wall bore papillary growths. The cavity was simply drained, and two years later the patient was free from recurrence.

Annual Meeting.

The audited balance-sheet of the Treasurer (Dr. J. Watt Black) was passed round.

OBSTETRICAL SOCIETY OF LONDON.

Abstract of Receipts and Payments for the year ending December 31st, 1899.

1899.	RECEIPTS.	£	s.	d.
To balance from 1898 .	£221 14 1			
Less Cheque outstanding	7 13 0			
	214 1 1			
On Deposit . . .	650 0 0			
		864	1	1
„ (1) 505 Annual Subscriptions, realising .		530	3	6
„ (2) Composition Fees . . .		68	5	0
„ (3) Midwives' Examination Fees . .		871	10	0
„ (4) Sale of 'Transactions' (Longmans) . .	£77 17 11			
Do. do. (Society) .	2 11 0			
Do. Midwives' Questions .	0 19 0			
Do. Midwives' Regulations and Infant Rules . .	0 2 8			
		81	10	7
„ (5) Interest on Consols .	41 17 6			
Ditto on Deposit .	15 0 1			
Ditto on N. British Railway Debentures .	21 4 3			
		78	1	10
„ (6) Sale of £2100 Consols .	2218 1 6			
Less cost of Power of Attorney	0 11 6			
		2217	10	0
		£4711	2	0

Audited and approved,

TOM MUNDY, F.C.A.

J. WATT BLACK, M.D.,
Treasurer.

3rd February, 1900.

1899.	PAYMENTS.	£	s.	d.
By (1) 'Transactions,' Vol. XLI, Printing, Paper, Binding, Delivery, and Illustrations		219	3	4
„ (2) Library:				
Books purchased .	£32 17 1			
Binding . . .	14 11 11			
		47	9	0
„ (3) Museum and Library:				
Rent . . .	200 0 0			
Librarian's Salary .	145 0 0			
Repairs to Furniture, Cleaning, Coals, Lighting, &c. . .	36 13 0			
		381	13	0
„ (4) Expenses of Meetings . .		24	19	10
„ (5) Stationery, Stamps, and Printing .		46	7	3
„ (6) Examination of Midwives:				
Fees paid to Examiners .	408 18 6			
General Expenses .	134 13 11			
		543	12	5
„ (7) Extraordinary Payment:				
Refunded overpaid to Bank in 1898 .		1	0	0
„ (8) Banking Expenses:				
Cheques and Commission . .		0	14	3
„ (9) Investment:				
Purchase of—				
£1468 N. Brit. Debentures	1559 0 9			
£1641 18*s.* Mid. Raily. do.	1559 0 9			
		3118	1	6
„ Balance at Bank . £235 4 6				
Less Cheque not presented .	7 3 1			
	228 1 5			
On Deposit . . .	100 0 0			
		328	1	5
		£4711	2	0

It was moved by Dr. Playfair, seconded by Dr. Stabb, and carried—"That the audited report of the Treasurer be received, adopted, and printed in the next volume of the 'Transactions.'"

Report of the Honorary Librarian for 1899.

"There is very little of interest to report regarding the Library of the Society.

"Fifty-nine volumes have been added to the Library, of which 31 have been presented by their authors, and 28 have been purchased. The total number of books in the Library now amounts to 5431.

"It is disappointing to find that so little use is made of the Library by the Fellows of the Society. Only 610 visits were made to the Society's rooms during the year, an average of about two for each day, and only 43 Fellows made use of their privilege of borrowing books from the Library during the same period. These figures prove that the advantages of such a Library, unique in its special branch of literature, are not yet fully realised by the Society as a whole.

"Amand Routh, M.D."

It was moved by Dr. Griffith, seconded by Dr. J. Watt Black, and carried—"That the report of the Hon. Librarian be received, adopted, and printed in the 'Transactions.'"

Report of the Board for the Examination of Midwives.

"The Board of Examiners have the honour to report that during the past year 842 candidates entered for examination; 705 were successful in satisfying the examiners, 119 failed, and 18 were absent.

"The total number on the Register up to the present date is 4943.

"The increase of applicants this year over last year is 154.

"During the last twelve months the opposition that has been raised in some quarters to a Midwives Bill has been considerably modified. At the November sitting of the General Medical Council, Mr. George Brown and Mr. Victor Horsley were defeated, and the action of the Obstetrical Society was supported and approved by the President, Sir William Turner, the late Sir Richard Thorne, and others, and the beneficial influence which the Obstetrical Society had exercised in improving the status of midwives was freely acknowledged. Moreover, at the meeting of the Metropolitan Counties Branch of the British Medical Association in December, the only resolution which was carried was—'That this Branch, realising that the abolition of midwives is impossible, is of opinion that all women practising as midwives should be placed under proper supervision by medical practitioners, and is prepared to support legislation for this purpose,'—a resolution which we cordially endorse.

"On behalf of the Board,

"PERCY BOULTON, M.D.,

"*February 7th*, 1900. "*Chairman.*"

Dr. GRIFFITH moved—"That the report of the Chairman of the Board for the Examination of Midwives be received, adopted, and printed in the 'Transactions.'"

This was seconded by Dr. ROBERT BOXALL and carried.

The ballot was then taken for the election of Honorary Fellows, and the following gentlemen were declared elected: Sir William Overend Priestley, M.D., M.P. (London); James R. Chadwick, M.D. (Boston, U.S.).

The President announced that the officers and Council shown on the printed list as recommended by the Council were duly elected.

Officers and Council.

President.—Alban Doran, F.R.C.S.

Vice-Presidents.—John W. Byers, M.A., M.D. (Belfast); William Radford Dakin, M.D.; John Phillips, M.A., M.D.; Jamieson Boyd Hurry, M.A., M.D. (Reading).

Treasurer.—James Watt Black, M.D.

Chairman of the Board for the Examination of Midwives.—Percy Boulton, M.D.

Honorary Secretaries.—Herbert R. Spencer, M.D.; Amand Routh, M.D.

Honorary Librarian.—Montagu Handfield-Jones, M.D.

Other Members of Council.—Augustus W. Addinsell, M.B., C.M.; A. H. Freeland Barbour, M.D. (Edinburgh); George Francis Blacker, M.D.; Robert Boxall, M.D.; Francis Henry Champneys, M.A., M.D.; Thomas Vincent Dickinson, M.D.; Angus Fraser, M.D. (Aberdeen); Arthur Edward Giles, M.D.; George Ernest Herman, M.B.; Thomas Robert Lombe, M.D. (Torquay); John Dysart McCaw, M.D.; Ewen John Maclean, M.D.; Hugh James Moon Playfair, M.D.; William Loudon Reid, M.D. (Glasgow); George H. Drummond Robinson, M.D.; William Japp Sinclair, M.D.; Arthur Francis Stabb, M.B., B.C.; John William Taylor, F.R.C.S. (Birmingham).

It was moved by Dr. W. J. Gow, seconded by Dr. Nix, and carried—"That the thanks of the meeting be given to the retiring Vice-President, Dr. William Duncan, and to the other retiring members of the Council, Dr. Ford Anderson, Dr. Eden, Dr. Hayes, Dr. Nicholson, Dr. Pinhorn, Dr. Hubert Roberts."

It was moved by Dr. Cullingworth, seconded by Dr. Horrocks, and carried—"That the best thanks of the meeting be given to the retiring Hon. Secretary, Dr. John Phillips, and to the retiring Hon. Librarian, Dr.

Amand Routh, for their valuable services to the Society during their respective terms of office."

Dr. CULLINGWORTH, in moving the resolution, said that he could not let the retirement of Dr. John Phillips from the secretaryship pass without a personal acknowledgment from him (the speaker) of the great assistance Dr. Phillips had given him during his two years of office as President, of the pleasure it had been to work with him, and of the admirable and conscientious manner in which he had performed the responsible and somewhat exacting duties of the secretarial office.

He believed that compared with the office of Hon. Secretary that of Hon. Librarian was not particularly onerous; but though the duties might be somewhat light, Dr. A. Routh had performed them conscientiously, and deserved the thanks of the Society. Dr. Routh was now going to undertake the heavier duties of the Secretaryship, and he had no doubt that he would do the work allotted to him in such a way as to earn the gratitude of the Society, just as surely as he had done in the post he was now relinquishing.

The PRESIDENT then delivered the Annual Address.

ANNUAL ADDRESS.

Gentlemen,—The President of this Society is expected to give at each Annual Meeting an account of the work done during the past year. On January 1st, 1899, the total number of Fellows was 693, 14 being honorary and corresponding, and 679 ordinary Fellows. In 1899 we lost 10 by death and 20 by resignation. On the other hand we have gained 26 by election, so that our net loss is 4. On January 1st, 1900, our total amounted to 689, of whom 14 are honorary and corresponding, and 675 ordinary Fellows. I trust that the Fellows will exert themselves to increase our ranks. No doubt the great multiplication of newer and more local societies accounts for the almost stationary condition of older associations, as far as mere numbers are concerned. Yet the special advantages which we can offer to all who join us, young and old, should be explained to all members of the profession suitable as candidates.

You have seen that the reports of the Treasurer, Honorary Librarian, and Chairman of the Board for the Examination of Midwives, are altogether satisfactory. The advantages of our fine Library do not seem to be generally appreciated by the Fellows ; let me then remind you that it is kept supplied with all the leading text-books, monographs, and periodicals, British and foreign, which treat of midwifery and the diseases of women. The prospect of legislation for midwives would be bright indeed if it were not for the terrible responsibilities which Parliament must face during this Session, and which will leave it little time for domestic legislation. Our Council and Board have during the past year kept watch over the

rights and interests of our Society, lest they should be prejudiced by misunderstandings and misstatements.

The essential part of our annual address consists of a review of our work, and some notice of the lives of those departed from us. The obituaries make up a tragic theme, especially on this occasion, when I shall have to speak of that remarkable man Mr. Lawson Tait. I must begin with the review, which, I am glad to say, cannot rank as tragedy, and is not exactly comedy, but, from its very nature, and no fault of ours, is apt to fall under the tutelage of the genial goddess of Dulness mentioned in Pope's "Dunciad." Now with your gracious patience, I will a round, unvarnished tale deliver of the whole course of our meetings in 1899. This annual review is undoubtedly a little wearisome to the whole meeting, but individual Fellows must be considered as well as the entire Society. A President would give offence should he, after furnishing you with full details of a few contributions, speak of the other papers, like the author of the 'Eton Latin Grammar' spoke of certain nouns, as "many others which it would be tedious to recapitulate."

Following the commendable example of my predecessor, I shall review the papers in scientific and not in chronological order, and will begin with communications on obstetrical subjects, of which we had a good series last year.

Pregnancy, Labour, and the Puerperium.

Puerperal eclampsia formed the subject of two papers. Drs. Walter Griffith and Eden read in April a communication on a case of this disorder, adding a description of a five weeks' ovum removed in a subsequent pregnancy. The patient was subject to chronic nephritis. The ovum showed, under the microscope, morbid changes, which the authors held to be primary. In October another clinical report on puerperal eclampsia was read by Dr. Horace Savory; in this instance obstinate constipation existed,

and when overcome the patient began to get well. Copræmia, it was noted, is by no means the cause of eclampsia, though clearly a perilous complication.

In June a good discussion followed the reading of Dr. Thomas Wilson's interesting paper on hydramnion in cases of unioval or homologous twins, based on two cases in the author's practice and twenty carefully tabulated from other sources. The promulgation of Dr. Wilson's views on the subject led to much discussion as to the causation of hydramnion under any circumstances, and as to the natural sources of the liquor amnii.

Dr. Lewers favoured the Society in July with a record of a case of persistent mento-posterior position of the face, in which, after failure with the ordinary forceps, the child was speedily delivered with the axis-traction forceps. There was some discussion after the reading of this report as to whether the mal-presentation was strictly "persistent," and might not have been better corrected by a Luke Robinson's lever, or by a long straight forceps.

In October we were indebted to Dr. Herbert Williamson for a contribution on hydatidiform degeneration of the chorion. He discussed, among other things, the relation of hydatidiform mole to deciduoma malignum. In consequence we were honoured by some observations made by Dr. Ludwig Fraenkel, of Breslau, the author of several important monographs on hydatidiform mole, and one of the chief supporters of the German theory that deciduoma malignum often owes its origin to this form of mole. Addressing us in the noble language of Goethe and Schiller, he brought forward arguments in defence of his theory certainly based on patient observation and direct research. He observed that Veit was the sole German authority who agreed with the theory of Kanthack and Eden, that decidnoma malignum arises in a sarcoma of the uterus existing before, but stimulated by, the pregnancy.*

Dr. Herman read in November a report of two cases

* "Deciduoma malignum," Veit's 'Handbuch der Gynäkologie,' vol. iii.

in which life was apparently saved by the use of anti-streptococcic serum. This preparation was in the first instance administered to a patient apparently moribund after the partial removal of a suppurating pelvic cyst, in the second to a subject suffering apparently from pyæmia in childbed. Considerable scepticism as to the value of serum-therapy was admitted by the author in the very title of his paper, and by others who discussed it. Both the valuable report of the American Gynecological Society and the investigations of our Honorary Secretary, Dr. Herbert Spencer, made public at the Portsmouth meeting of the British Medical Association last August, alike tend to discredit the use of antistreptococcic serum.

Dr. John Phillips read in December notes on a case of apparently acute idiopathic peritonitis complicating pregnancy and labour. An exploratory incision was made, but the patient died. At the necropsy no definite cause for the peritonitis could be discovered.

Extra-uterine Pregnancy.

A clinical report was read by Dr. Archibald Donald, in January, on a case of intra-ligamentary ectopic gestation at the seventh month, in which the fœtus was extracted by vaginal incision and perforation. An abdominal incision had just been made, but as the placenta presented in that direction, the vaginal route was deemed the safer. The patient recovered. The placenta came away slowly and in fragments.

Notes on a case of tubal molar pregnancy were read by Dr. John Phillips in December. The author laid stress on the continued uterine hæmorrhage which was observed. An ovarian cyst on the opposite side suppurated, and the affected tube was removed in the fifth month, when fever had set in.

I now come to papers on gynæcology.

Diseases of the Uterus.

Dr. P. D. Turner, of Ryde, brought forward in November some valuable evidence on tubercular disease of the uterus and Fallopian tubes, based on the examination of the genital tract in twenty-seven consecutive cases of phthisis, in the post-mortem room at the Brompton Hospital. We know that primary tubercular disease, when it attacks the female organs, usually selects the tubes; Dr. Turner's investigations seem to show that in phthisis the uterus is almost as often the victim of secondary affection as are the tubes.

Two clinical reports on sarcoma of the uterus were read by Dr. Walter Griffith in June. The specimens were placed in the hands of a sub-committee; in the first case, though the after-history proved high malignancy, the sections of the tumour did not present distinctly malignant characteristics.

Fibroid tumours of the broad ligament, separate from the uterus, formed the subject of two communications made in May. Dr. Hubert Roberts related the case of a suppurating cystic fibro-myoma weighing 25 lbs. and containing 13 pints of pus. This tumour was successfully removed by Mr. Meredith. On the same evening I read full notes of a case where I removed a solid fibroid of the broad ligament weighing 44½ lbs., or 20 kilogrammes, the largest as far as I can find which has ever been removed with satisfactory results. I also submitted to your notice a table of thirty-nine cases of this class of tumour, with an analysis of the ages of the patients, symptoms, and other matters of interest.

Diseases of the Fallopian Tubes.

In March Dr. Hubert Roberts read an instructive clinical communication on a second case of that rare affection, primary carcinoma of the Fallopian tube, under his own observation. The patient was sixty years old,

much above the average age in this disease. The diseased tube was removed by Mr. Meredith, and the patient remained in good health for seven months, dying from recurrence a little over eleven months after the operation.

Diseases of Infants and Female Children.

In January Dr. Drummond Robinson made public the results of his investigation of fifty-five cases of vulvitis in children. In over three quarters of the cases the pus-cells in the discharge contained what appeared to be the gonococcus, so that the disease must usually be gonorrhœal in origin.

I will now speak of specimens and short communications, classifying them in the same order.

Pathology of Pregnancy and Labour.

Dr. McKerron read in April two cases illustrating antero-posterior positions of the head as a cause of difficult labour. In both the posterior fontanelle lay anteriorly, the sagittal suture running almost directly backwards. In both the character of the pelvis precluded version as a means of rectifying the unfavourable position. Craniotomy was therefore the only alternative to rotation with the forceps. An earlier resort to the forceps would, in all probability, have saved the children; such was in Dr. McKerron's opinion the practical deduction from these two cases. Notwithstanding the prolonged labour both mothers made good recoveries.

Dr. Dakin read in March some notes of high interest to the practical obstetrician on a fibro-myoma spontaneously enucleated during labour. The tumour presenting, at first simulated placenta prævia.

Dr. Purslow, of Birmingham, exhibited in May a four months' fœtus spontaneously expelled, after a few pains, in its amniotic sac unruptured.

The Pelvis and its Deformities.

A Naegele's pelvis was exhibited by Mr. Targett in June.

At the July meeting Professor Arthur Thomson, of Oxford, gave a demonstration of the sexual differences of the fœtal pelvis, based on his important monograph published in 1899 in the 'Journal of Anatomy and Physiology.' He showed that the essential sexual characters of the pelvis are as well defined in the fœtus as in the adult, although great authorities have taught us otherwise.

Morphology and Teratology.

Dr. Amand Routh deserves our thanks for having exhibited in January a beautiful specimen, preserved in formalin, of early gestation in both horns of the uterus in a bitch. Formalin, and not alcohol, is clearly the right medium for preserving the placenta.

Morphology has teratology for a handmaid. The two were combined in Mr. Bland-Sutton's specimen of an acardiac monster from a cow, brought forward at our March meeting. A third morphological specimen, consisting of sections of the uterus of *Macacus radiatus*, was exhibited by Dr. Addinsell in April.

Dr. Arnold Lea showed us in January a tumour expelled from the uterus during labour at six and a half months in a case of hydramnion. After careful examination a committee decided that the tumour was an acardiac fœtus arrested very early in its development.

Dr. Burton's specimen of deformed fœtus exhibited in October was reported by a committee to be an example of fœtal rickets or achondroplasia.

Ectopic Gestation and Retained Fœtus.

In May Dr. Addinsell exhibited an uterus and appendages with ruptured pregnant tube, and Dr. Galabin

showed a case of very early tubal abortion, the embryo measuring only one third of an inch in length. Yet the symptoms were as severe as those usually observed in rupture of the pregnant tube at a much later stage.

Specimens of retained fœtus after extra-uterine pregnancy were exhibited in June by Mr. Malcolm. In the first case the fœtus had been retained for a year unsuspected, and with its surroundings formed a tumour simulating an ovarian cyst. In the second the fœtus, as proved by an earlier diagnosis, has been retained for seven years; its bones lay scattered about the pelvis; one at least perforated the walls of the intestine. In July Dr. Lediard, of Carlisle, read notes of a case of discharge of a retained fœtus piecemeal through the rectum.

Diseases of the Uterus.

Dr. Smyly brought forward in March three myomatous uteri removed after Doyen's method through the vagina. He found that shock and mortality were less than in abdominal hysterectomy. Dr. Amand Routh showed in April a tumour of the uterus removed by pan-hysterectomy. A committee reported it to be a fibro-myoma with inflammatory, not malignant, changes. Three uteri removed by pan-hysterectomy were shown by Dr. Lewers in July.

Dr. Addinsell exhibited in June a specimen showing unusual thickening of the endometrium in fibroid disease of the uterus.

At the October meeting Mr. Bland-Sutton exhibited a specimen of myoma which had undergone rotation and impaction; a second myoma, partially calcified, and weighing 26 lbs., successfully removed from a woman aged 74; and a broad ligament tumour weighing 22 lbs., also successfully extirpated.

At the same meeting I exhibited a fibroid in the undeveloped right cornu of an uterus unicornis, which I

had removed by operation. Pregnancy had already occurred twice in the left cornu, and I have just been informed that the patient is once more pregnant.

Dr. Walter Tate exhibited in December a calcareous fibroid imbedded in the posterior wall of the cervix, in a woman aged fifty-eight. The uterus was removed, the fibroid being too firmly fixed to allow of enucleation.

In December Dr. Blacker exhibited a mushroom-shaped fibro-adenoma of the cervix, and Dr. Herbert Spencer showed a mucous polypus of the cervix bearing in its centre a deep canal, the orifice of which simulated an os uteri. In certain characters it was not identical with Oldham's "channelled polypus," which it in other respects resembled.

In November Mr. Targett showed a specimen of perimetric sarcoma, and Dr. Robert Wise submitted for our inspection a photograph of a corpulent subject with a large lipoma below the right breast and a bulky pendulous uterine tumour.

Diseases of the Ovary.

In January Dr. Boxall showed two dermoid ovarian tumours from the same patient. Both pedicles were twisted, and clinical evidence indicated that torsion occurred in one pedicle eleven months after the same accident had befallen its fellow.

Mr. Bland-Sutton submitted to our notice in March a ruptured ovarian adenoma. The peritoneal cavity became so stuffed with colloid material that a hernial umbilical and femoral sac developed, having this material as its sole contents.

In June Mr. Malcolm demonstrated a remarkable multilocular papillomatous cyst attached to the front of the bladder and distinct from both ovaries. Dr. Robinson exhibited, in December, a large ovarian cyst removed through a vaginal incision. At the same meeting Dr.

Walter Tate showed a sarcoma of the ovary from a young girl. It had grown rapidly, and also became remarkably painful. It proved not only to be sloughy, but also undergoing suppuration. Dr. Purslow showed in May a broad ligament cyst with walls of unusual thickness.

Diseases of the Fallopian Tube.

In January Dr. Addinsell showed sections of a tube and ovary removed for the relief of intermenstrual pain, or "Mittelschmerz" by Mr. Bland-Sutton, who also performed a hysteropexy; the pain then disappeared. The tube showed the appearances of simple chronic inflammation; it was obstructed at the abdominal end.

At the annual meeting Dr. Cullingworth read notes on a genuine case of tubo-ovarian abscess. It originated in a pyosalpinx which adhered to an ovarian cyst, their cavities ultimately communicating.

Dr. Arnold Lea brought forward a specimen of hæmatosalpinx not due to tubal pregnancy, but to chronic pelvic inflammation, probably of gonorrhœal origin.

Mr. Targett exhibited in May specimens of primary double tuberculous pyosalpinx, and in November samples of tubercular pyosalpinx secondary to phthisis. Reference has already been made to Dr. Turner's cases, where the uterus as well as the tube was tubercular; one specimen of tubercular uterus was exhibited by Dr. Turner.

In December I exhibited a specimen of double hydrosalpinx without evidence of salpingitis, in reference to a paper which I read just ten years previously, and in respect to the question of salpingostomy.

Diseases of the Vagina and Vulva.

Mr. Targett read notes, in March, on a case of fibromyoma of the anterior vaginal wall removed with scissors, and in December Dr. Herbert Spencer read a short communication on adenoma of the meatus urinarius, removed

by Paquelin's cautery. The patient, nearly seventy years of age, was free from recurrence six months later.

Some discussion on the bacteriology of the vagina and its discharges was raised in June, when Dr. T. G. Stevens read notes of a case of membranous vaginitis in which the *B. coli communis* was found.

Diseases of Infants.

Mr. Lionel Smith exhibited at the March meeting an infant six weeks old subject to diffuse subcutaneous induration. The affection differed in several respects from the usual form of œdematous sclerema, and seemed more akin to scleroderma.

I have already referred to Alexander Pope, and now that my review of our work for 1899 is concluded, I feel sure that you will admit that my allusion to the Goddess Dulness was hardly out of place. "Dulness is sacred in a sound Divine" says the Rev. Luke Milbourn in the second book of the "Dunciad" (v. 352), but it seems absolutely essential in a sound President engaged in delivering an annual address. Fortunately it is his duty to record past work, not to criticise it. The Bard of Strawberry Hill begins his splendid "Essay on Criticism" by remarking that—

> "'Tis hard to say if greater want of skill
> Appear in writing or in judging ill;
> But, of the two, less dang'rous is th' offence
> To tire our patience, than mislead our sense."

The gentlemen about whose labours I have spoken have not written ill; but though the President is not in the position of a critic, and so cannot mislead your sense, he is most unnaturally forced into the place of a bad writer, and thus compelled to tire your patience.

Obituaries.

During the year 1899, the Society lost by death, so far as is at present known, ten Ordinary Fellows. Earliest on the list come two of our number who departed this life on the same day, namely, Mr. George Farr, and Mr. Bright of Forest Hill.

George Frederick Farr

was one of our senior Fellows, having been elected in 1861, before the Society was two years old. Born at Baldock, Hertfordshire, in March, 1832, he entered Guy's Hospital as a student when twenty-four years of age. In 1859 he became a Member of the Royal College of Surgeons of England, and in the succeeding year took the diploma of L.R.C.P.Edin. He began practice at first in the Borough, succeeded Dr. Wakem in West Square, St. George's Road, and on settling in Kennington, which he was destined never to leave, soon began to prosper, as is often the case when the practitioner begins life at a mature age. He became greatly esteemed by his patients, and acquired a large circle of friends. Seventeen years ago he was made a surgeon of police, distinguishing himself in that department. In 1885 he was elected a member of our Council. His eldest son, Frederick William Farr, was a member of our profession, but died before him in 1893; to a second son, Mr. George Farr, I am indebted for these particulars. Mr. George Frederick Farr, practising to the last in Kennington, died rather suddenly from cerebral hæmorrhage at his private residence at Twickenham, on January 11th, 1899, having nearly completed his sixty-seventh year.

John Meaburn Bright

was born in the city of London in 1833; his grandfather was the Rev. John Bright, Prebendary of Salisbury.

His father, Dr. Richard Bright, practised in South Audley Street. Dr. Bright was educated at Rossall, and was designed for the Church, but he preferred to take up our profession, and began the study of medicine at Queen's College, Birmingham, afterwards entering the Medical School of Guy's Hospital, where he was distinguished for his industry and gained the friendship of Dr. Addison. He qualified in 1857 at Apothecaries' Hall, and two years later became a Member of the College of Surgeons; in 1862 he received the degree of M.D. of St. Andrews, with honours. In 1864 he was elected a Fellow of our Society, and was a member of the Council in 1873–4.

After acting as assistant to the late Dr. Ray, of Dulwich, and holding the appointment of House Surgeon to the Surrey County Hospital, Guildford, Dr. Bright settled for good in practice at Forest Hill in 1863, where he became deservedly beloved and trusted. Mr. Rand, of Wimbledon, informs me that Dr. Bright had for many years a large obstetric practice, and not long ago a leading London gynæcologist invited him to take up obstetric work in town under his auspices, a proposal which Dr. Bright considered unadvisable to accept, as he was doing so well at Forest Hill.

Dr. Bright was a genial, learned, and public-spirited gentleman, as well as an able practitioner. When young he had the opportunity of studying diphtheria during two severe epidemics of that malady at Dulwich and Guildford, and several cases, reported with great care, were incorporated with Sir Hermann Weber's treatise, "Ueber die Nervenstörungen und Lähmungen nach Diphtheria," in the twenty-eighth volume of 'Virchow's Archiv.'* In Dr. John Harley's report of a "Case of Hydatid Tumour of the Liver, involving the Gall-bladder; Operation; Recovery," published in the forty-ninth volume of the 'Medico-Chirurgical Transactions,' Dr. Bright's share in

* Dr. Bright's cases will be found loc. cit., pp. 489—493. The first part of Hermann Weber's treatise was published in the twenty-fifth volume of the 'Archiv,' p. 114.

the case, which he attended in the absence of the author, is acknowledged. Dr. Bright edited the "Report on Midwifery and Diseases of Women and Children" in the New Sydenham Society's 'Year-book,' 1863–4.

Dr. Bright, however, after taking to the practice in which he died in harness, devoted his leisure to intellectual rather than scientific work. Being very versatile, he not only took deep interest in politics, literature, and the drama, but also wrote several commentaries on books of the Old and New Testament, which were published anonymously. He took an active part in the founding of the Forest Hill Provident Dispensary and the establishment of the Sydenham District Medical Society.

Dr. Bright's death occurred very suddenly, from syncope, on January 11th; thus, as I have already observed, he and Mr. G. F. Farr died on the same day.

William Richard Dambrill-Davies,

latterly known as a distinguished volunteer surgeon, died rather suddenly at his residence, Stonycroft Grange, Alderley Edge, Cheshire, on February 26th, from internal strangulation. He was born fifty-five years ago in Carmarthen; his father, Mr. Davies, was then the leading chemist in that town. He was educated first at the local grammar school, and afterwards at the Normal College, Swansea, from which institution he passed the Oxford Higher Local Examination. His professional studies were prosecuted at University College, London; he took the old double qualification of M.R.C.S. and L.S.A. in 1867. In the following year he became House Surgeon to the Southern Hospital, Liverpool, holding that appointment for two years. He then took a practice at Sandbach, Cheshire, where he was much respected; and on marrying a Miss Dambrill he added his wife's surname to his own, and was thus afterwards known as Mr. Dambrill-Davies. Moving to Chelford, he went into partnership with Dr. Clay, of Manchester, and worked

with him for a few years, taking over Dr. Clay's consulting-rooms when that celebrated surgeon retired. Mr. Dambrill-Davies, however, was a modest and somewhat diffident gentleman, and it cannot be said that he possessed those qualities by which others were enabled to establish abdominal surgery. He had a keen sense of justice, which induced him to defend his friend, Dr. Clay, with great energy. In support of his teacher's claims as an ovariotomist, he prepared a life of Charles Clay, to be found in the second volume of Leyland's 'Contemporary Medical Men' (p. 41).

In 1882 Mr. Dambrill-Davies became a Fellow of our Society. He finally set up in practice at Alderley Edge. There he prospered and took much interest in military surgery, so that he was ultimately raised to the rank of Surgeon Lieut.-Col. (V.D.) in the Army Medical Reserve and 5th Volunteer Battalion of the Cheshire Regiment. It was Mr. Dambrill-Davies who introduced the opaque-white glass drainage-tube, which he preferred to the clear glass tube of Keith and Koeberlé. As he had lived respected at Sandbach, so he lived and died respected at Alderley Edge. For much information concerning his career I am indebted to Drs. Renaud, Lloyd Roberts, and Mr. Thomas Jones, of the Manchester Royal Infirmary, and also to Dr. Emrys Jones, who testifies that the deceased "was most kind to the poor, and actuated always by the highest ethical standards."

Clement Pound

was the son of Dr. George Pound, of Odiham, Hants, where he was born in 1861. He was educated at the Middlesex Hospital, where, after qualification, he held the appointment of House Surgeon. In 1886 he became L.S.A., and next year took the L.R.C.P. of London. On the death of his father, in 1893, he succeeded to his old-established practice, and in 1894 became a Fellow of this Society. Unfortunately his health began to fail in the

spring of 1898, so he took a voyage to Natal. On his return he became Medical Officer to the British India Steam Navigation Company. During a visit of the "Goa" to Zanzibar he contracted fever, which was followed by acute pleurisy, and he died on board that ship on March 2nd, at the early age of thirty-eight.

James Andrew Duncan,

one of our Original Fellows, died on April 5th, in his eightieth year. He was born at Oxford; his father, Mr. Andrew Duncan, was a solicitor who practised in Buckingham Street, Strand. He was educated at King's College School, and studied medicine at that college, of which he became an Associate. He qualified as M.R.C.S. in 1845, and took the degree of M.B.Lond. in the same year, and then held the appointment of House Surgeon at King's College Hospital under Sir William Fergusson. In 1847 he settled in practice in Covent Garden, where he remained till his death fifty-two years later. This veteran must be mourned by us as an Original Fellow; he was a member of Council in 1863–4, and Vice-President in 1895. He was a working, but not a writing man, his sole contribution to medical literature being a paper on "The Inhalation of Naphtha in Pulmonary Consumption," published in the 'Medical Gazette.' His life was dedicated to our profession, and his example has been followed by two of his sons, Surgeon Lieut.-Col. Andrew Duncan, and Dr. Horace Duncan.

Alfred Thomas Gibbings

was born at Woodbury, Devonshire, in 1848, but brought up chiefly at Chichester, where he became a pupil of Dr. Leonard Buckell. Afterwards he entered at the Medical School of King's College, of which he became an Associate, Scholar, and Prizeman. He took the diplomas of M.R.C.S. and L.S.A. in 1869, and graduated as M.B.Lond.

in 1870 and M.D. in 1874. After holding the appointment of House Surgeon at the Stamford Infirmary, he entered into partnership with Drs. Daly and Long, of Dalston. In 1875 he became a Fellow of this Society, and was a member of the Council in 1885 and 1886, and also in 1888.

Dr. Gibbings fell a victim to duty. He suspected cardiac mischief for the last two years of his life, and was greatly overworked, especially last winter, when he had to attend many cases of influenza, whilst at the same time the new legislation increased his work as public vaccinator. After attending three cases of pneumonia in one house last March, Dr. Gibbings himself became a subject of that disease, and died on April 9th. "Peace," says Milton in his sonnet on Cromwell, "hath her victories no less renowned than war." Unfortunately her victims too often stand lower in public esteem than those who fall on the field of honour. Yet the public, whilst honouring our heroes in South Africa, should not forget that Dr. Gibbings sacrificed himself for the public cause.

Lawson Tait.

On June 3rd, 1899, died one of the most remarkable men known in the entire annals of surgery, perhaps the most original of all the many original characters which our profession has developed in the course of that highly original century which is now passing away. Robert Lawson Tait was born in Edinburgh on May 1st, 1845. His father, Archibald Campbell Tait, was a lawyer, cousin to the Archbishop of Canterbury of the same name. At the age of seven Lawson was admitted into Heriot's Hospital, of which his father was a guild brother. He gained a scholarship, and by that aid entered the University of Edinburgh. He ever afterwards believed in intellectual education as a support to manual dexterity. He felt sure that even the Birmingham button-cutter was the better for the compulsory and almost free education supplied in the Birmingham schools. His medical edu-

cation extended from 1860 to 1866, when he came under the guidance of a surgeon of great promise who unfortunately died young, Mr. McKenzie Edwards, a favourite pupil of Sir William Fergusson.

In 1866 Tait qualified as Licentiate of the Royal College of Surgeons, Edinburgh, and four years later became a Fellow, taking also the Fellowship of the English College in 1871. Later on he received honorary degrees, chiefly from American universities. But qualifications and professional titles are of little importance in respect to a man like Tait. He often declared that much of his success was due to what he learnt as a student from Sir James Simpson, and as an assistant from Sir Henry Littlejohn.

His first regular appointment after qualification was the House-surgeoncy to the Wakefield Hospital, where he succeeded Milner Fothergill. There he remained for three years, and at once showed his skill as an operator. In 1868, when but twenty-three years of age, he performed his first ovariotomy at the Wakefield Hospital, and did five more within the two years that he remained there. Already he displayed those tendencies to oppose and attack past and current practices for which he was ever afterwards celebrated.

In 1870 he settled for good in Birmingham, having bought the practice of Dr. Thomas Partridge, now Medical Officer of Health for Stroud; he also became associated with Dr. Bell Fletcher. Always ready to use his pen, Tait joined the staff of the 'Birmingham Morning News,' and became an active contributor to the columns of that enterprising newspaper.

In 1871 he married the daughter of the late Mr. Stewart, of Wakefield. In the same year, through the exertions of Mr. Arthur Chamberlain, Tait, and others, the Birmingham and Midland Hospital for Women was established, and, along with Dr. Savage, Lawson Tait was appointed Honorary Surgeon. At once he began to distinguish himself in the field of abdominal surgery. It

was in February, 1872, that he removed an ovary for chronic abscess, the first occasion on which that organ had been deliberately excised for inflammatory disease. This innovation, though destined to lead to great abuses, was none the less important. It paved the way to intelligent operating on deep pelvic structures. On August 1st of the same year Tait for the first time removed the uterine appendages for myoma. The similar experiences of Battey and Hegar * at this date must be remembered, though to detail them here would be out of place. In 1873 he was awarded the Hastings Gold Medal by the British Medical Association for a treatise on diseases of the ovaries, and four years later the appearance of his work on 'Hospital Mortality' excited great controversy.

In 1877 he turned his attention to the Fallopian tube and began to remove it for disease. During that year I was engaged in working at the new catalogue of the Pathological Series in the Museum of the Royal College of Surgeons. As specimen after specimen arrived at Lincoln's Inn Fields from Birmingham, I was astonished to find how salpingitis and allied affections had been overlooked by the pathologist and the surgeon. No doubt, in the light of further experience, many of the samples which I received showed that "Hic manebimus optimè," as Camillus once remarked, would have been the best motto for the tubes before operation. Still, if it is from Tait that we have learnt what to avoid, we must thank him for that teaching, and remember that we have also learnt from him how under many circumstances the Fallopian tube must be sacrificed, and how to remove it. This class of operation brought about a few years later his disputes with Sir Spencer Wells, who, as I am able to

* These authorities wrote their own account of their experiences in the celebrated "Symposium" ('Amer. Journ. Med. Sciences,' vol. xcii, p. 455), presently to be quoted. See also Marion Sims's "Remarks on Battey's Operation," 'Brit. Med. Journ.,' 1877, vol. ii, pp. 793, 840, 881, and 916.

bear witness, prophesied truly about the abuse of operations for chronic disease of the appendages.*

Lawson Tait's energy was destined to manifest itself most brilliantly in 1879. It was then that he displayed most clearly his faculty of establishing procedures which others had suggested, or even introduced, yet had failed, through the want of that faculty, to put into practice, or to raise to the rank of accepted surgical operations. It was then that he described at one of our meetings the flap-splitting method for the repair of the perinæum with which his name is very naturally identified. It is a pathetic fact that the last operation which he ever performed was a perinæorrhaphy of this class, undertaken within three weeks of his death.

In the same year we may say, without exaggeration, that Tait gloriously established hepatic surgery. He performed in 1879 his first cholecystotomy.† In the year 1869 Tait opened up a sinus which discharged through the umbilicus and communicated with a suppurating gall-bladder. He was thus enabled to remove several gall-stones. In 1878, nine years later, Marion Sims, for whom Tait ever owned the greatest admiration, performed cholecystotomy on a patient almost dying from chronic obstruction of the bile-ducts. Relief was immediate, but the patient sank a week later. It happened, however, that Dr. Bobbs, of Indianapolis, had successfully undertaken a genuine cholecystotomy in 1867, two years before Tait's operation on the sinus. But Tait, after he performed in 1879 the third operation of that kind on record, and the second that ended successfully, was more fortunate than

* The controversy between Lawson Tait and Spencer Wells is summed up in Tait's "Discussion of the General Principles involved in the Operation of the Removal of the Uterine Appendages" ('Proc. Med. Soc.,' vol. x, pp. 38—60, 1886), and in Spencer Wells's, Hegar's, and Battey's "Castration in Mental and Nervous Diseases: a Symposium" ('Amer. Journ. Med. Sciences,' vol. xcii, p. 455): an invaluable record of the personal opinion of those three authorities.

† "Case of Cholecystotomy performed for Dropsy of the Gall-bladder due to Impaction of a Gall-stone," 'Med.-Chir. Trans.,' vol. lxiii, p. 17.

Sims or Bobbs. Special faculties and favouring circumstances enabled him to follow up his victory well, and Mr. Mayo Robson has justly insisted that to Lawson Tait "undoubtedly belongs the credit of having popularised the operation with the profession." So high did Tait's fame rise in later years, in the field of hepatic surgery beyond the earlier limits of the gall-bladder, that in 1895 he was summoned to France in order to operate on one of our Honorary Fellows, who has never since missed an opportunity of expressing his gratitude. The French obstetrician dedicates his famous "Femmes en Couches et Nouveau-Nés—À Lawson Tait; Grâce à vous j'ai pu écrire ce livre. Permettez-moi de vous le dédier. Votre très reconnaissant Pierre Budin." In an obituary notice M. Budin thus refers to his own case: "He (Tait) was one of the first to undertake with success surgical proceedings on the biliary ducts and the liver itself. That is why in 1895, on the advice of Professors Brouardel, Bouchard, and Tarnier, we asked him to be so good as to go to the south of France to perform on us a laparotomy for an obscure hepatic disorder. On Monday, May 4th, he received our letter at noon; on the 5th he left Birmingham, met Tarnier when passing through Paris, and reached Beaulieu at 8.30 a.m. on the 7th. At 11 a.m. he operated on us in presence of our friends Drs. Bar, Crouzat, and Thaon (of Nice). He brought with him Mr. J. W. Taylor as his assistant. It is needless to say how much gratitude and affection we feel for him; the news of his decease plunged us into deep sorrow." *

Certainly British surgery and Lawson Tait himself received on that occasion a very sincere and practical compliment. In 1880 he performed for the first time the operation of hepatotomy.† He gradually gave up antiseptic surgery during these years when he introduced so

* 'L'Obstétrique,' 4th year, p. 432 (July, 1899).

† "Three Cases of Hepatotomy," 'Proc. Roy. Med. and Chir. Soc.,' vol. ix, p. 73 (not in 'Med.-Chir. Trans.'). For discussion see 'Lancet,' 1881, vol. i, p. 868. In Tait's reply "Australian" is misprinted "Styrian."

much original work, and carried on a characteristic warfare with his opponents in the correspondence columns of the medical papers.* In 1885 he published a remarkable communication on "One Hundred and Thirty-nine Consecutive Ovariotomies performed between January, 1884, and December 31st, 1885, without a Death."† In this operation he, like Sir Spencer Wells, was a great advocate of a short abdominal incision. Tait's defiance of antiseptics, and even of asepsis, comes out very clearly in a well-known passage in this celebrated paper. In allusion to his practice of washing out the peritoneum, on which he wrote more specially two years later, he declared that "the water is plain, unfiltered tap-water, warmed by the addition of enough from the boiler. It is full of germs and spores, and small beasts of thirty-four different varieties, according to a careful report of Dr. Alfred Hill, published some few years ago." As he speaks of additions from the boiler, we see that the cold water was not previously sterilised by boiling on more modern "aseptic" principles.

Acting on post-mortem evidence in a case where he had declined to operate in 1881, Lawson Tait performed his first operation for ruptured tubal pregnancy on January 17th, 1883. Nobody can deny that Tait conferred on womankind great benefit by his boldness in the treatment of ectopic gestation; this truth is proved by the wonderful advance in the surgery of this condition during the past seventeen years.

In 1887 he published a remarkable series of operations

* "The Antiseptic Theory tested by the Statistics of One Hundred Cases of Successful Ovariotomy," 'Med.-Chir. Trans.,' vol. lxiii, p. 161. A good abstract of the discussion which followed the reading of this paper, including remarks by Sir Spencer Wells, Mr. Knowsley Thornton, and others, will be found in the 'Lancet,' vol. i, 1880, p. 251.

† 'Brit. Med. Journ.,' i, 1886, p. 921. This paper had already been read before a meeting of the Birmingham and Midland Counties Branch of the British Medical Association on March 11th, 1886 (*ibid.*, p. 698). Characteristic letters on the antiseptic controversy by Lawson Tait will be found in the 'Med. Times and Gaz.,' vols. i (p. 689) and ii (pp. 98, 128, and 164), 1880.

for cystic collections of fluid in the anterior and inferior part of the abdomen. Although his theory that they were allantoic or urachal was based, according to his own admission, on defective evidence, it must, on the other hand, be allowed that in reporting these cases Tait succeeded in turning the attention of surgeons to the pathology and operative treatment of cysts of the urachus.*

One of the boldest and most valuable of the numerous innovations which surgery owes to Lawson Tait is the washing out of the peritoneum with large quantities of hot water for the purposes of cleansing and hæmostasis, to which reference has already been made. The first paper devoted to this subject is entitled "Methods of Cleansing the Peritoneum," and appeared in the 'British Gynæcological Journal,' vol. iii, 1888, p. 185. Though the practice may have been abused and over-rated by some, there are others who have discovered that it acts favourably not only in the manner well understood by the man who introduced it, but in other ways about which he had no suspicion.

During these years of labour, so fruitful in brilliant results, Lawson Tait also taught as Professor of Gynæcology at Queen's College, Birmingham. He took a leading part in transferring the medical school of Queen's College to the Mason College, now the University of Birmingham. He was for several years an active member of the City Council of Birmingham, and shone conspicuously in several biological, philosophical, archæological, and literary societies. He was a fly-fisher and an excellent connoisseur of high art and good wine, and for a time kept up a large country house in the New Forest. Taken as a whole, he was an "advanced" thinker, even from his student days, when disputing on the side of science he

* "Twelve Cases of Extra-peritoneal Cysts," 'Brit. Gynæc. Journ.,' vol. ii, 1887, p. 328. I discussed Lawson Tait's views at length in a communication on "A Case of Cyst of the Urachus, with Notes on Urachal and so-called 'Allantoic Cysts,'" 'Med.-Chir. Trans.,' vol. lxxxi, p. 301.

acquired that ability in polemics of which he made so much use in later life. Nevertheless, like Faust, he tried his hand at "*leider, auch Theologie,*" for he delivered more than one sermon at a chapel. One of these, "The Image of Baal," was published, and had a rather extensive circulation.*

"The applause of listening senates to command" was one of the few definite aims which Lawson Tait failed to obtain; for he contested the Bordesley division of Birmingham in 1886, as a Gladstonian, but was defeated by Mr. Jesse Collings.

Lawson Tait made free use of his pen, which in style was that of a ready writer. He was the author of four books, using the term books in a strictly literary sense. Allusion has already been made to the first, 'Hospital Mortality,' and to the Hastings Essay, best known in its much revised and enlarged fourth edition, published in 1883, and entitled 'The Pathology and Treatment of Diseases of the Ovaries.' In 1888 appeared his 'Lectures on Ectopic Pregnancy and Pelvic Hæmatocele,' and in 1889 the first volume of his unfinished 'Diseases of Women and Abdominal Surgery.' The second volume was never published. These works, excepting perhaps 'Hospital Mortality,' are familiar to us all, and have had a wide influence. His mysterious 'General Summary of 1000 Cases of Abdominal Section,' chiefly known because its title appeared, without further reference, under his name in the 'Medical Directory,' was really an address delivered before the Midland Medical Society on January 21st, 1885, and published in abstract in the 'British Medical Journal.'† His 'General Summary of Conclusions from his Entire Experience in Abdominal and Pelvic Surgery—about 4000 Cases,' much inquired after, as it

* 'Queen's Medical Magazine' (Birmingham), July, 1899, p 29.

† "Abstract of an Address on One Thousand Abdominal Sections, delivered before the Midland Medical Society," 'Brit. Med. Journ.,' 1885, vol. i, p. 218. On October 11th, 1888, he read notes of a "Second Series of One Thousand Cases of Abdominal Section," *ibid.*, vol. ii, 1888, p. 941 (title only given).

also was named in the 'Medical Directory,' never appeared in print. It was read at a meeting of the Midland Medical Society on November 22nd, 1893.* Lawson Tait also wrote a very large number of papers for societies, and original communications to medical newspapers.

Lawson Tait died a Fellow of our Society, which he joined in 1871. He contributed fifteen papers to our 'Transactions.' Among them I may note the "New Methods of Operation for Repair of the Female Perineum," read in November, 1879. It included a demonstration of his now familiar "flap-splitting" perineorrhaphy, and gave rise to active discussion, in which Matthews Duncan and other well-known authorities took part. His notes "On Axial Rotation of Ovarian Tumours, leading to their Strangulation and Gangrene" were read a year later; they have been quoted far and wide. The other contributions were on some of his favourite topics, such as pyosalpinx and myoma. Lawson Tait's last contributions to our 'Transactions' are of importance; they will be found in the thirty-fourth volume. One is an essay on "Growth of the Placenta after Death of the Fœtus in Ectopic Gestation," written in association with Mr. Christopher Martin; a second treats of cases of hysterectomy; whilst the last is a highly valuable report of "A Case of Ectopic Pregnancy, in which the Fœtus seems to have Developed to the Full Time in the Peritoneal Cavity, still retaining its Amniotic Covering." This case bids fair to become classical; it is quoted in Mr. J. W. Taylor's excellent work on "Extra-uterine Pregnancy," and tends to support the theory of the latter authority, that, as a rule, abdominal pregnancy is secondary to tubal pregnancy without any intermediate intra-ligamentary stage, as Tait used to teach. In asso-

* 'Brit. Med. Journ.,' 1893, vol. ii, p. 1328 (title only given). I am indebted to Dr. Kauffmann, and to Messrs. J. W. Taylor, W. F. Haslam, Gilbert Barling, and Christopher Martin for assistance in verifying these references. The summary of the 4000 cases was never published; there is no note of it to be found in the 'Lancet,' 'Medical Press and Circular,' and 'Index Medicus.'

ciation with this case, however, we must not forget that Lawson Tait had already brought forward more conclusive evidence than any other authority to demonstrate the truth that ectopic gestation is almost always, if not invariably, tubal in origin.*

Of recent years Lawson Tait stood a little less prominently before the public. One of his biographers has observed that no great surgical position was ever made more rapidly, nor lost with such pathetic suddenness. He considered that this and several other of the older-established London societies had treated his views with small respect. His complaints, however, were hardly reasonable, for this Society, as I have already reminded you, published over fifteen of his contributions, and if many expressed objections to his views, he was ever permitted to express dissent from the opinions of others. But that warfare is accomplished. His health began to fail when he was about forty-eight years of age. He spent the last three years of his life at Llandudno, where he contemplated the erection of a sanatorium for consumptive patients, having bought with that intent, last May, the "Old Telegraph," just on the summit of the Great Orme's Head. He came up weekly to Birmingham in order to operate and see patients. On June 3rd, 1899, he was suddenly taken ill at Droitwich, and was at once removed to Llandudno. After a temporary improvement, he died on the 13th, having barely completed his fifty-fourth year. His remains were cremated at the Anfield Cemetery, Liverpool, placed in an urn, and according to his last wishes deposited in Gogarth Cave, on the western side of the Great Orme's Head, within his own garden. Thus we can say literally as well as figuratively, "Peace to his ashes."

Gentlemen, I have endeavoured to supply you with an impartial summary of Lawson Tait's life in relation to the

* For arguments supporting the opposite theory see Catherine Van Tussenbroek, "Un cas de grossesse ovarienne," in the 'Annales de Gynécologie et d'Obstétrique,' vol. lii, 1899, p. 537.

profession in general and to the Society in particular. Boldness and dexterity were his strong points. Through boldness he established operations such as cholecystotomy, and valuable aids to the operator, such as cleansing of the peritoneum. True, he acted in most cases on suggestions derived from others, but we must not neglect the claims of a man bold enough to force on surgery necessary innovations which others have introduced, but have failed to establish through lack of certain qualities and opportunities. Their claims must also be regarded when it is pertinent to champion them; to such men, worthy of all honour, I have had occasion to refer this evening.

On medical education and training he often spoke with common sense. He denounced the lecturer whose teaching was pitched clearly too high for his audience. He wrote on this evil in language which recalls Cobbett: "Not many years ago I attended a lecture on physiology given to medical students, which consisted of an explanation of a brass instrument resembling a model of Clapham Junction, intended to explain something about muscular fibre."* On the other hand, whilst thus denouncing pedantry, however unconscious, Tait rightly condemned the debasing of the student's intellectual faculties by memoria technica. He specially exorcised "bodfi" by name.†

In sketching the life of a man who had such wide influence we must nothing extenuate, any more than we should set down aught in malice. That influence on the profession was by no means in all respects satisfactory. He was no man of science, like Huxley, the pure scientist, or Paget, the surgeon who knew how to apply science to surgery. These great men found out the unknown in nature through the known; in other words,

* "Address in Surgery at the Fifty-eighth Annual Meeting of the British Medical Association," 'Brit. Med. Journ.,' 1890, vol. ii, p. 267.

† "Has 'bodfi' ever served any of you at the bedside? Is there any conceivable condition of human accident or ailment in which 'bodfi' could assist you to relieve your patient?" *ibid.*, p. 268.

they understood what science meant. Tait was too eager to make scientific facts appear to support his personal views and justify his practices. We know that far inferior men have lived in the same error, have examined specimens and sections, and argued ingeniously how what they found and wanted to find clearly demonstrated what, at the onset of their labours, they wanted to prove. We are all liable to fall into this kind of intellectual error.

Finally, Tait's example has unfortunately tended to intensify the prevalent error that operating is necessarily surgery, and that recovery proves that the operation was justifiable. Let us trust that it was entirely through that lack of the scientific faculty on which I have dwelt that Tait often over-estimated the danger of leaving a diseased structure and, therefore, was often over-anxious to urge on the patient the necessity for its early removal. His statistical methods, too, were inaccurate, and his manner of conducting disputes was, to say the least, unconciliatory; many of his opponents, however, seemed to have precisely those faults which they were ever ready to condemn in him.

Yet Lawson Tait did great things and will not be forgotten.

Thomas Cargill Nesham,

Lecturer on Midwifery at the University of Durham College of Medicine, Newcastle-on-Tyne, was a member of our Council ten years since, and Vice-President from 1895 to 1897.

His father was Mr. William Nesham, a surgeon of Newcastle, and Thomas Nesham's professional life was intimately associated from the first with the Northern English School of Medicine in his native town. Born in Pilgrim Street, Newcastle, on Christmas Day, 1841, he was educated at Bury St. Edmunds and Merchiston Castle School, Edinburgh. He began his career in 1857 as a

student in the school where he became a teacher, but left Newcastle for Edinburgh University and the Rotunda Hospital, Dublin, and took the degree of M.D. at Edinburgh and the diploma of L.S.A. and M.R.C.S. in London in 1863. By that time he had already returned for good to the banks of the Tyne, having been appointed Medical Tutor to the Newcastle College of Medicine. At the end of three years he was made Lecturer on Anatomy, and in 1875 was finally appointed to the Chair of Obstetrics, which he held till his death, twenty-four years later.

Mr. Rutherford Morison informs me that "Dr. Nesham wrote no papers. On the evening of March 13th, 1884, one of the few occasions on which he came to the meetings of the Northumberland and Durham Medical Society, he introduced a discussion on the more frequent use of the forceps in midwifery. The last sentence of the introduction is the gist of his opinion: 'I maintain, sir, that the more frequent use of the forceps in lingering labour is clearly indicated by the rules of obstetric science, justified by the results of experience, and demanded by the common law.' Dr. Nesham was one of the old school, a typical sporting doctor. He was a skilful cricketer, a keen angler, a good diner, and a very effective after-dinner speaker. He was held to be the best lecturer in the Durham College of Medicine, and was popular with students, colleagues, and patients."

He received the Honorary degree of M.D., University of Durham, in 1872. In July, when on a holiday in the north of Scotland, he was attacked with septic pneumonia, was brought home, and died in his house, in Ellison Place, Newcastle, on July 16th, deeply regretted by colleagues and friends.

Samuel Johnson,

of Stoke-on-Trent, died, aged fifty-three, on November 15th. He received his medical education in Ireland at Galway and Dublin, and became Doctor of Medicine and

Master of Surgery of the Royal University of Ireland in 1870. He held for many years the appointment of Medical Officer of Health for the borough of Stoke-on-Trent, and Medical Officer and Public Vaccinator for the Stoke District of the Poor Law Union. He also practised with great success in the town where he held these appointments. In fact, he was extremely popular at Stoke both for his high private and professional reputation and for his civic virtues, so that his funeral was public, being attended by the mayor and corporation, by representatives of local public institutions, and by a large number of his friends. He became a Fellow of this Society in 1877, but his duties prevented him from attending our meetings. In regretting his death we must feel proud that a gentleman so deeply honoured by all who knew him was once amongst our ranks.

James Ford,

a native of Devonshire, died suddenly on December 20th at Exmouth. He was sixty-eight years of age. He received his education at the Westminster Hospital, qualifying as M.R.C.S. and L.S.A. in 1858, and he took the degree of M.D. of St. Andrews in 1862. For a time he was Resident Physician-Assistant to the Brompton Hospital for Consumption, and afterwards House Surgeon to the North Devon Infirmary at Barnstaple. On giving up that appointment he became a partner of the late Mr. Tidbould, at Chumleigh, North Devon, and after his death carried on the practice by himself and was made Medical Officer to the South Moulton Union—more than ten miles north of Chumleigh,—and to the Crediton Union—about the same distance south of Chumleigh.

We know that such appointments involve great fatigue and bring no renown, yet Dr. Ford discharged his duties cheerfully and with efficiency. In 1875 he joined the late Dr. David King at Eltham, and practised with him

until Dr. King retired in 1892. In 1877 Dr. Ford was elected a Fellow of this Society. Dr. Jeken informs me that Dr. Ford's practice was largely among the poor, although not confined to that class, and his kindly disposition and patience in inquiring into the circumstances attending his patients' ailments, combined with the scientific interest which he took in his profession, brought him well-deserved popularity. He did a great deal of midwifery at Eltham, and in this, as in all other branches of his profession, he was a sound and painstaking practitioner. He always kept on the very best terms with other members of the profession.

He was, no doubt, best known to the profession at large as one of those gentlemen who attend, with great regularity, the Annual Meetings of the British Medical Association. At the end of 1893, having left Eltham, he travelled in the Mediterranean, America, and other distant places, then resided for a time at Crediton, and finally settled with friends at Exmouth, where he died.

This concludes both our death-roll and the Annual Address, which, like most similar productions, and also like Prospero's spirits, will melt into air—into thin air,—and, like his (Prospero's) insubstantial pageant faded, will leave not a wreck behind. I thank you for listening to me with such exemplary patience.

Dr. Champneys moved—"That the thanks of the meeting be given to Mr. Alban Doran for his address, and that he be requested to allow it to be printed in the next volume of the 'Transactions.'" He said that whatever might be Mr. Doran's faults, dulness was not one of them. Indeed, with so extensive a memory and so light a fancy his difficulty surely was in the selection of images and quotations and the rejection of others. The address had been most interesting, and the obituary of Mr. Lawson Tait so concise, discriminating, and fair, that he doubted if it would have failed to appear so to the subject, could

he have heard it. Indeed, he thought many of us might wish that Mr. Doran might be selected to deliver our own funeral oration. In the words of Johnson's epitaph on Oliver Goldsmith, it might truly be said of Mr. Doran, "Nihil tetigit quod non ornavit."

This was seconded by Mr. Butler-Smythe, and carried by acclamation.

MARCH 7TH, 1900.

ALBAN DORAN, F.R.C.S., President, in the Chair.

Present—34 Fellows and 5 Visitors.

Books were presented by the American Gynecological Society, the Glasgow University Court, the Gesellschaft für Natur und Heilkunde in Dresden, Sir Henry W. Acland, and Dr. James Oliver.

Ernest James Hayford, M.D. (Free Town, Sierra Leone), was declared admitted.

The following gentlemen were proposed for election: William Francis Victor Bonney, M.D., M.S., F.R.C.S.Eng., and Henry Heath Pochin Johnson, L.R.C.P.

The following gentlemen were elected Fellows of the Society: Hugo Adolf Levison, M.D. (Columbia Univ.), and Frank Edward Taylor, M.A., M.B.

RE-DESCRIPTION OF THE SPECIMEN OF SPONDYLOLISTHESIS IN THE MUSEUM OF UNIVERSITY COLLEGE.

(See Plates VI and VII.)

By T. W. P. LAWRENCE, F.R.C.S. (introduced by Dr. BLACKER).

THE specimen, which was added to the museum in 1849, was taken from a dissecting-room subject, whose

sex has not been recorded : it consists of the last four lumbar vertebræ, the sacrum, and the first piece of the coccyx. A portion of the lateral mass of the sacrum on the left side, including nearly the whole of the auricular surface, has been sawn off, and a nearly median section divides the specimen, with the exception of the second and third lumbar vertebræ, into right and left halves.

For purposes of description the specimen must be assumed to be in a definite position, that adopted being the one shown in Plate VI, fig. 1. In this position the long axis of the hinder or lower part of the auricular surface is nearly vertical.

The spinous processes of the second and third lumbar vertebræ are thickened, and their upper and lower borders broadened out into surfaces by which the adjacent spines appear to have lain in contact. In other respects these vertebræ are normal, and they need not be again referred to.

The more obvious features of the main part of the specimen are—(1) a forward and downward displacement of the bodies of the fourth and fifth lumbar vertebræ, the body of the fifth overhanging the hollow of the sacrum in front of the body of the first sacral ; (2) great modification of form affecting certain parts of the arches of the fourth and fifth lumbar vertebræ ; (3) marked increase in the curve of the sacrum ; (4) an increase in the antero-posterior measurement of the spinal canal opposite the last two lumbar and first two sacral vertebræ ; (5) marked deformation of the body of the first sacral vertebra ; and (6) extensive ankylosis, the sacrum and the two lumbar vertebræ being fused into a single piece.*

On examining the form and relations of the several bones in detail, it is seen that the body of the *fourth lumbar vertebra* has a normal appearance. It retains its normal relation to the body of the fifth, and is united to it by an intervertebral disc, which has become slightly

* These points are well shown in two figures of the specimen given in vol. xxvi, pp. 152, 153, of the 'Transactions' of this Society.

Fig. 1.

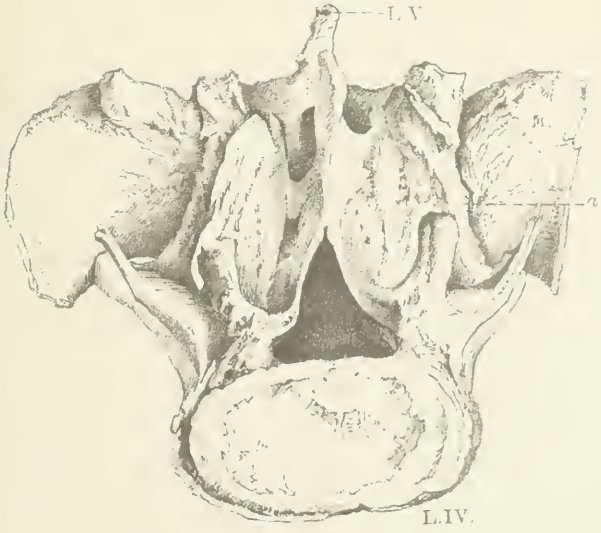

Fig. 2.

Bale & Danielsson, Ltd., Lith.

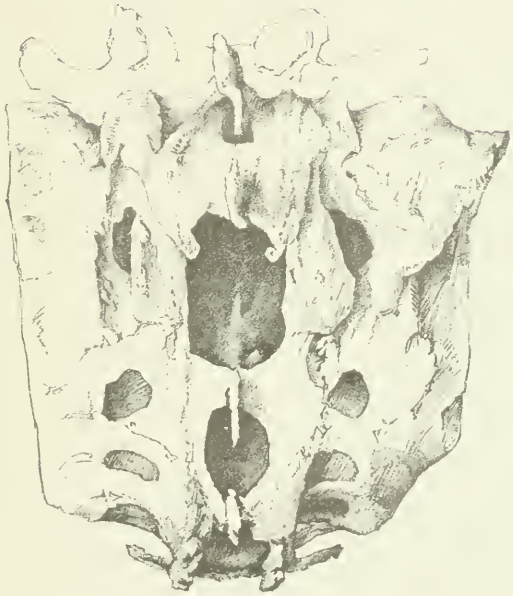

Fig. 3.

Bale & Danielsson, Ltd., Lith.

ossified at its hinder border. The pedicles, transverse processes, and superior articular processes have their normal relations to the body, that is to say, they have been displaced forwards with it, and with the exception of the extremities of the transverse processes, which are directed backwards more than usual, these structures have their normal form. The superior and inferior notches are well marked. The upper aperture of the neural ring is altered in shape (Plate VI, fig. 2); its hinder angle, which is more acute than normal, is prolonged backwards so as to reach nearly to the level of the tips of the upper articular processes; its antero-posterior measurement is 24 mm., the excess over the normal being accounted for by the elongation of the laminæ subsequently mentioned. The spinous process projects horizontally backwards, its extremity lying in the middle line between the superior articular processes of the sacrum, and reaching backwards to about the same level as the latter; its upper border is broadened into what appears to be an articular facet. The laminæ are greatly modified; instead of being directed downwards from their junction with the pedicles they project horizontally backwards, and are at the same time flattened out laterally, so that the distance between their lateral margins measures as much as 4·7 cm. at their anterior part; they are also elongated in a sagittal direction, the left, which exhibits a somewhat greater elongation than the right, measuring 3·3 cm. Posteriorly each lamina is bounded by a free concave border, passing outwards from the spinous process. The greatly elongated outer margins of the laminæ are ankylosed to bony structures lying beneath them, and in consequence of this and of the great modifications of form undergone by this part of the specimen, the inferior articular processes are altogether obscured, and their position can only be indirectly inferred. Thus, on referring to a normal bone, the external border of the lamina is found to present superiorly a smooth portion forming the hinder boundary of the notch, below this a rough area for part

of the capsular ligament, and below this the facet of the articular process. Further, on tracing the free lower border of the lamina outwards from the spine, in the normal bone, it is seen to lead to the articular process. Applying these facts to the specimen, the upper free portion of the outer border of the lamina is distinct, forming the hinder boundary of the notch, but below this the border is hidden by the ankylosed anterior portion of the superior articular process of the fifth lumbar vertebra; but on tracing the hinder border of the lamina outwards from the spinous process it is found to lead on each side to a small irregular mass of bone forming the inner part of a larger mass, which occupies the position of the superior sacral articular processes (Plate VII). From these facts it is inferred that the inferior articular processes of the fourth lumbar vertebra have descended to the level of the superior sacral articular processes, and further, that they have undergone an antero-posterior elongation, the distance from the small mass of bone mentioned to the hinder boundary of the notch being 5 cm. The chief alterations in the fourth lumbar vertebra are, therefore, a descent of the whole vertebra, causing the inferior articular processes to occupy a position between the superior sacral articular processes, a bending backwards and upwards, and a lateral flattening out of the laminæ, an elongation of the inferior articular processes and adjacent part of the laminæ, and lastly, a forward and downward displacement of the body of the bone.

The body of the *fifth lumbar vertebra*, seen from the front, shows little alteration in form; but it is smaller than normal. Owing to its descent it entirely hides the body of the first sacral, the level of the two being the same. It is tilted so that its anterior surface is directed as much downwards as forwards. In the median section the reduction in the size of the body is still more marked, the posterior border, especially, being greatly reduced. The postero-inferior angle rests against the upper surface of the body of the first sacral vertebra,

somewhat anterior to the middle of the latter, and is ankylosed to it, whilst the inferior surface passes forwards and downwards out of contact with the sacral surface, but united to it through a triangular mass of bone, which, doubtless, represents the ossified remains of the disc. The lower border of the body of the fifth lumbar vertebra projects forwards in front of the body of the first sacral for a distance of 1·5 cm. The pedicles, transverse processes, and at least the anterior part of the superior articular processes have been carried forwards with the body, with which they retain fairly normal relations; the pedicles are, however, much drawn out and thinned, and pass upwards and backwards from their junction with the body, and the transverse processes are directed markedly backwards and upwards, and are more slender than normal. The upper notches complete, with the lower notches of the fourth lumbar vertebra, foramina which are somewhat reduced in their antero-posterior measurement. The spinous process is smaller than normal, measuring 1·7 cm. in length; it projects horizontally backwards from the hinder aspect of the sacrum on a level with the upper ends of the highest pair of posterior sacral foramina (Plate VII). The laminæ are small and badly developed, especially in their lower parts, the two together forming a thin plate of bone which closes in the upper part of a large gap in the hinder wall of the sacral canal caused by defective ossification of the laminæ of the sacrum. The inferior margin of the lamina of each side, on being traced outwards from the spinous process, is found to lead to a slender process of bone of about 4 mm. in length, which projects mesially over the margin of the gap in the sacrum before mentioned. These processes appear to be the extremities of the rudimentary inferior articular processes; they lie on a level with the lower ends of the upper pair of posterior sacral foramina. Externally the laminæ rest upon and are ankylosed to the persistent lateral portions of the upper sacral laminæ, a slight groove passing upwards and outwards from each

of the small processes above named, indicating the external boundary of the lamina. Traced upward, each groove leads to the roughened mass of bone which occupies the position of the superior sacral articular process, and which in part must be held to represent the posterior extremity of the superior articular process of the fifth lumbar vertebra. From the inner aspect of each of the roughened masses referred to, a distinct and well-defined surface of the bone passes horizontally forwards (Plate VI, fig. 2, *a*), adjacent to the outer margin of the lamina of the fourth lumbar vertebra, and is continued anteriorly into the outer surface of the anterior part of the superior articular process of the fifth lumbar vertebra, which, as before mentioned, retains its normal position with regard to the body of the bone. This bony surface measures 3·7 cm. from before back, and is about 6 mm. in width, its borders being nearly parallel throughout; it is ankylosed on the one hand to the external margin of the lamina of the fourth lumbar vertebra, and on the other to the sacrum, on which it lies. Posteriorly, however, it is separated from the sacrum by a small oval interval measuring about 6 mm. in length and 2 mm. in height, lying immediately in front of the base of the sacral articular process, and representing the intervertebral foramen. The narrow bony surface described establishes the continuity between the hinder part of the arch of the fifth lumbar vertebra and the displaced anterior portion, and must be held to represent the outer surface of the elongated upper articular process. (Towards its anterior end on each side it presents one or two small pointed osteophytes directed backwards; these probably indicate the points of attachment of stretched ligamentous bands, but they might also be held to indicate a previous fracture in this situation, due either to the lateral flattening out of the laminæ of the fourth vertebra, or to the downward displacement of the body of the fifth.) The intervertebral foramina between the last lumbar and first sacral vertebræ have been referred to; owing to the forward

displacement of the pedicle of the last lumbar vertebra with the body, the anterior parts of the inferior notches form the upper boundaries of narrow slit-like foramina, bounded below by the upper surface of the body of the sacrum. To complete the description of the fifth lumbar vertebra, the upper margin of the lamina may be traced forwards from the base of the spinous process. This margin is seen in the figure of the median section (fig. 1, *a*) as a faintly marked but continuous ridge, passing horizontally forwards between the lamina (*b*) of the fourth lumbar vertebra above, and the sacrum below, ankylosis having occurred here between the three bones; anteriorly this ridge is seen to pass towards the hinder end of the pedicle. The upper and anterior part of the lamina has, therefore, undergone elongation corresponding to the amount of displacement forwards of the anterior part of the upper articular process. The chief changes noted in the fifth lumbar vertebra are, therefore, a maldevelopment of the hinder part of the arch affecting chiefly the inferior articular processes and the adjacent portions of the laminæ, a descent of the laminæ on to the back of the sacrum and of the superior articular processes into a position between the upper sacral articular processes, an elongation of the latter processes, and a forward and downward displacement of the body of the bone.

The *sacrum* presents extensive defects of ossification in its posterior surface. Thus there is complete absence of the central part of the hinder wall of the sacral canal as low as the second pair of sacral foramina; and a second gap, measuring 2·2 cm. by 1·5 cm., exists between the levels of the second and third pairs of foramina. The lateral parts of the laminæ are present, and to them the displaced laminæ of the fifth lumbar vertebra are ankylosed, as above mentioned, the sacral canal being closed in in this situation by the latter bone. In the position of the superior articular processes there is on each side an irregular mass of bone which, on the left side more especially, shows signs of a division into an

outer and an inner portion, in the presence of a pit at its postero-inferior aspect. The part of the mass to the outer side of this pit apparently represents the sacral articular process; that on its mesial side is to be regarded, for the reasons before given, as representing parts of the united articular processes of the fourth and fifth lumbar vertebræ (the base of the process of the fifth and the extremity in the fourth). As far as can be judged the sacral articular processes do not present any appreciable alteration as regards size; the distance apart of their external surfaces is 5·3 cm. In other respects the posterior surface of the bone is normal. The body of the first sacral vertebra is best studied in the median section; it presents a greater degree of deformation than the bodies of the other vertebræ. Its axis is markedly curved, the concavity of the curve being directed downwards and forwards, and in correspondence with this the anterior and posterior surfaces are curved in a similar way, the posterior retaining its normal height, the anterior being very greatly reduced. Through these changes, and through a certain degree of tilting forwards of the body of the second sacral vertebra, the upper surface of the body of the first sacral is directed forwards, its line of section being vertical. The body of the fifth lumbar is ankylosed to it in the manner before described, the upper half of the upper surface of the first sacral being free. There is a considerable break in the line of the posterior surface of the body at its upper part, due apparently to a previous partial fracture in this situation. The body of the second sacral vertebra presents the same general alteration in form, and the same tilting forward of the upper part of its body as the first sacral, but in a much slighter degree. The spinal canal opposite the first two sacral vertebræ presents the same increased sagittal measurement as was noticed in describing the fourth lumbar vertebra; opposite the first sacral it measures 2 cm. This sagittal widening of the sacral canal appears to be due to an actual forward displace-

ment of the bodies of the first two sacral vertebræ, the laminæ being retained in their normal position through their connection with the unaltered lateral masses of the sacrum. The displacement of the bodies has been permitted through the formation of prominent ridges on their hinder surfaces (fig. 1, *c*, *d*), the ridges forming a continuation upwards and inwards of the free upper margin of the pedicles. These ridges approach the middle line superiorly, and thus tend to narrow the canal laterally. The ridges developed in connection with the first sacral vertebra (*c*) are ankylosed to the upper portion of the laminæ of the fifth lumbar vertebra, and at their upper part (*e*) they reduce the lateral measurement of the canal to 1 cm. In consequence of the forward displacement of the bodies of the first two vertebræ, and of their curvature above described, the highest point of the body of the first sacral is considerably below its normal level, and the whole of the upper surface of the body lies altogether anterior to the alæ of the sacrum, which are not altered in any noteworthy degree. The chief points observed in the sacrum are, therefore, the defects in its hinder wall, and the displacement and tilting downwards and forwards of the bodies of the upper two vertebræ.

Beyond the osseous deposits found in connection with the ankylosis of the several bones, there is nothing that can be regarded as callus, nor any indications of fracture except in the two situations already mentioned (p. 80). Apart from the elongation of certain portions of the bones, and the defects in the hinder wall of the sacrum, there is no evidence of any congenital fissure in connection with the arches. The body of the fifth lumbar vertebra is lighter and more porous than natural, as if from atrophy, but otherwise all sign of disease is absent.

To sum up briefly, the specimen exhibits imperfect development of the laminæ of the sacrum and last lumbar vertebra, downward displacement of the laminæ of the last lumbar vertebra on to the back of the sacrum with

associated displacement of the contiguous articular processes of the last two lumbar vertebræ downwards into a position between the sacral articular processes, elongation of the contiguous articular processes of the last two lumbar vertebræ, with flattening out of the laminæ of the fourth lumbar, forward and downward displacement of the bodies of the last two lumbar vertebræ, and to a less extent of the first two sacral, olisthesis of the last lumbar body, and ankylosis of the bones in their new positions.

The study of previous specimens of spondylolisthesis has led to the discarding of certain suggested causes, and to the acceptance of others. *Disease* appears to be excluded according to present views. *Injury* is accepted as a possible cause in the form of fracture of the lamina of the fifth lumbar vertebra, though its presence cannot be said to have been definitely proved in any case. Fracture of the lumbo-sacral articular processes is also of doubtful occurrence. Undue pressure on the column, from overloading, may be included under the heading of injury, and this is accepted as an undoubted cause. *Maldevelopment* affecting the arch of the fifth lumbar vertebra or the lumbo-sacral articular processes is also an admitted cause. Maldevelopment affecting the arch of the fifth lumbar occurs as a congenital fissure through the lamina, and when it has caused spondylolisthesis it has led either to a separation of the two portions of the divided bone, or to an apparent elongation of the osseous tissue in the neighbourhood of the fissure. Maldevelopment affecting the lumbo-sacral processes, appearing as a diminution in the normal size of these structures, has caused, in the single case of spondylolisthesis referable to it, a forward subluxation of the lumbar articular processes (cf. Chiari, 'Zeitsch. f. Heilk.,' 1892, Bd. xiii, p. 222, pl. x, figs. 1 and 2).

In the present instance disease and injury (excepting overloading) may probably be excluded by simple inspection; previous experience would therefore point to overloading or maldevelopment as likely to be the primary

cause, and having regard to the defective development of the sacral and last lumbar laminæ, it is probable that the cause of the spondylolisthesis is to be sought in maldevelopment affecting the lumbo-sacral articular processes and the laminæ of the fifth lumbar vertebra. In view, however, of Chiari's case, above referred to, in which defect at the lumbo-sacral junction led to a forward, instead of, as in the present specimen, to a downward displacement, it is necessary to inquire whether the defect observed in the fifth lumbar vertebra is not due to a secondary atrophy from disuse following a downward dislocation of the normally developed bone, rather than to a primary fault of development. Against this view the extreme rarity of dislocations in the lumbar region in the adult is to be noted, it being stated in the last edition of Hamilton's work on fractures and dislocations that no case has ever been demonstrated. As regards congenital dislocation it is stated by Guérin,* who made a special study of this subject, that dislocation may occur in any joint in the body, and he refers specifically to the spinal column, though not to the lumbo-sacral junction. It is hardly conceivable that a downward dislocation by dorsal extension could occur *in utero;* but whether such a dislocation could occur in normal parturition or artificial delivery is difficult to decide. But supposing such a displacement to occur, it is probable that it would become reduced in the first weeks of extra-uterine life. Whilst, therefore, dislocation of the normally formed bone appears to be improbable, the view that the maldevelopment was primary receives great support from the presence of defective development in the contiguous part of the column below.

Assuming that the maldevelopment was primary, the mechanism of production of the dislocation has to be considered. The alternative factors are evidently the body weight and muscular action. The former may be rejected, as apparently it would have led to a forward dislocation

* 'Recherches sur les Luxations congénitales,' Paris, 1841.

of the lumbar articular processes * rather than to a downward displacement. As regards muscular action, either one of two views may be adopted:—(1) the displacement and ankylosis have occurred as part of the process of development of the lumbar curve; (2) they have occurred at a later date, when the spine would be called upon to bear increased weight, and are due to a forced voluntary extension of the lumbo-sacral spine, arising from a feeling of weakness and insecurity at the undeveloped joints.

Whatever view may be adopted as to the precise mechanism of its production, it would at least appear to be highly probable that the dislocation occurred in early life.

It is generally held that the presence of elongation in the arch of a vertebra must indicate that a solution of osseous continuity has at some time occurred; and if fracture cannot be proved, congenital fissure is assumed to have existed. But it is by no means certain that elongation cannot take place without solution of osseous continuity; the extensible and flexible nature of periosteum, combined with the power of absorption of osseous tissue already deposited renders almost any alteration in the shape of a bone conceivable, especially in growing bones, provided that it can be shown that forces suitable in magnitude and direction are acting on the bone. An example of elongation in two directions, that is to say of increase in area, is seen in the expansion of the shaft of a long bone by a central tumour. This being so, it seems desirable to inquire, with reference to the present specimen, presenting as it does an unusual condition in the displacement of the fifth lumbar laminæ, whether that condition is not sufficient to account for the deformities present, without resorting to the hypothesis of fissures all traces of which are absent.

Assuming that the weight of the trunk, transmitted through the body of the last lumbar vertebra, is distributed partly as a force acting vertically to the upper surface of the sacrum, and partly as a force tending to

* *Vide* p. 84, Chiari's case.

displace the body of the last lumbar vertebra forwards in a direction parallel to the plane of the upper surface of the sacrum; and assuming that the latter force is counteracted by the upper sacral articular processes, it is necessary, in the first place, to consider what effect the displacement of the fifth lumbar laminæ would have on the distribution of these forces.

The dislocation of the laminæ would be effected through a bending backwards of the sacrum, resulting in the upper part of the posterior surface of the sacrum being pushed up beneath the laminæ of the fifth lumbar vertebra. By this movement the upper articular processes of the fifth lumbar vertebra would be brought into a position between the upper sacral articular processes, and the relative parallelism of the adjacent articular surfaces of the bodies of the fifth lumbar and first sacral vertebræ would be greatly altered, in the sense that the hinder borders of these surfaces would be brought almost or quite into contact, while their anterior borders would be widely separated. This altered position of the two bones would have been retained, and probably fixed by ankylosis between the fifth lumbar and upper sacral laminæ, and between the upper sacral and upper fifth lumbar articular processes. In such a position the weight of the trunk passing through the body of the fifth lumbar vertebra could be transmitted to that of the first sacral in only one way, namely, from the postero-inferior part of the former to the postero-superior part of the latter, that is to say, in a manner which presents great mechanical disadvantage as regards the supporting power of the sacrum. Furthermore, the tilting backwards of the sacrum, and more vertical position of its upper surface resulting therefrom, would increase the tendency of the body of the fifth lumbar vertebra to forward displacement. Hence the effect of the displacement of the laminæ upon the distribution of the two forces mentioned is that there would no longer be any force acting perpendicularly to the upper surface of the body of the first sacral vertebra,—this is replaced by one acting vertically

downwards on the hinder edge of that surface ; and in the second place the force to be counteracted by the displaced upper articular processes of the fifth lumbar vertebra (now occupying the position of the upper sacral articular processes) would be increased. If now, through pressure on its hinder edge, the body of the first piece of the sacrum should yield in the way shown in Plate VI, fig. 1, a further redistribution of the two forces takes place, the proportion of the body weight to be sustained by the upper articular processes of the fifth lumbar vertebra being very greatly increased. In these circumstances, any tendency to elongation that may be assumed to exist in the fifth lumbar vertebra should show itself between the hinder surface of the body of the bone and the point where the pedicles are hooked over the base of the upper sacral articular processes, that is to say, in the pedicles and the anterior portion of the superior articular processes ; and it is in these structures that the elongation is exhibited in the specimen.

The conditions are somewhat different in the case of the fourth lumbar vertebra. Here the body of the bone retains its normal relation with the body of the vertebra below, and the whole vertebra, together with those above it, is carried forward as the body of the fifth lumbar advances, except in so far as it is held back by the extremities of its inferior articular processes. Any elongation that might be expected to occur in the fourth lumbar vertebra should, therefore, show itself between the extremities of these processes and the extremities of the inferior articular processes of the vertebra above, that is to say, in the outer part of its laminæ. That an elongation of this nature has taken place in the specimen is shown in fig. 2, the upper edge of the laminæ showing only slight elongation, and the pedicles remaining perfectly normal. With the sinking of the body of the fifth lumbar vertebra the laminæ of the fourth would gradually be rendered horizontal.

The mechanical conditions above described as affecting

the fifth lumbar vertebra would, doubtless, be altered as soon as the body of the bone had been displaced forwards to any considerable extent. The compensatory lordosis which would be established in consequence of the displacement would throw the line of gravity of the trunk back, the spinous processes would probably be brought into use for supporting part of the body-weight and the body of the fifth lumbar, and with it the pedicles would be relieved from pressure, and would commence to atrophy. But at first the main part of the weight of the trunk would still be borne by the upper articular processes of the fifth lumbar vertebra, and it would act on them in the same way as before lordosis was established, that is to say, as tending to elongate them.

The specimen described was stated by Dr. Graily Hewitt and Mr. Shattock, in a communication to this Society in 1884, to have been "discovered in the museum among the specimens of fractured bones by Dr. Neugebauer, jun., in his recent visit to this country." In his work on 'Spondylolisthesis and Spondylizema,' published in 1892, Dr. Neugebauer has inserted a woodcut of the specimen as illustrating the typical osteoplastic deformity of the fifth lumbar and first sacral vertebræ.

The main difference between the foregoing description and that of Dr. G. Hewitt and Mr. Shattock (*v.* 'Obstet. Trans.,' vol. xxvi, 1884, p. 149) has reference to the position of the hinder part of the fifth lumbar arch. In the latter description the posterior part of the arch is regarded as maintaining its normal relation to the sacrum, in the former it is held to have been dislocated downwards on to the back of the latter bone.

SPINAL COLUMN EXHIBITING WANT OF OSSIFICATION IN THE INTER-ARTICULAR PORTION OF THE LUMBAR VERTEBRÆ, ETC.

Shown by Dr. Blacker.

Dr. Blacker showed in illustration of a common cause of spondylolisthesis a spinal column exhibiting want of ossification in the inter-articular portion of the lamina of the fourth and fifth lumbar vertebræ, and also a first lumbar vertebra with a similar defect upon the right side. He thought the Society was greatly indebted to Mr. Lawrence for his description of the specimen of spondylolisthesis. The downward displacement of the laminæ of the fourth and fifth lumbar vertebræ on to the back of the sacrum was undoubtedly present, and had been apparently overlooked when the specimen was first shown. This condition was of the greatest importance in regard to the ætiology of the deformity, and had not hitherto been either recognised or described in any other specimen of spondylolisthesis. While entirely admitting the accuracy of Mr. Lawrence's description so far as the main points were concerned, he could not agree with his interpretation as to what represented the superior articular process of the fifth lumbar vertebra. This was a most important point, because upon it to a large extent rested Mr. Lawrence's theory that the deformity in this particular specimen was due to maldevelopment of the lumbo-sacral articulation. There seemed to Dr. Blacker to be many grave objections to such a view. If the superior articular process of the fifth lumbar vertebra was stretched to the extent described, why had not the superior articular process of the sacrum undergone a corresponding change?

While admitting that the upper border of the intervertebral notch would press upon the superior articular process in the manner described by Mr. Lawrence, he

wished to point out that the inferior articular process would at the same time, in the case of the fourth lumbar vertebra, exercise very marked pressure upon the lamina of the fifth lumbar vertebra; and since deficient ossification of the lamina was a fairly common condition, elongation of it was very likely to ensue as a result of such pressure. If the condition was due to maldevelopment of the lumbo-sacral articular processes, why was the lumbar process alone affected? The deficiency of the laminæ of the upper sacral vertebra might be looked upon as evidence of the likelihood of there being deficient ossification of the laminæ of the lumbar vertebræ, just as much as evidence of want of development of the articular processes of these vertebræ. In the only other cases in which spondylolisthesis appeared due to maldevelopment of the lumbo-sacral articular processes no such deformity as that described in this case had occurred, and, indeed, the possibility of such extreme stretching of the superior articular process of a lumbar vertebra appeared most unlikely.

Mr. Lawrence had adduced no evidence that the atrophy of the inferior articular processes of the fifth lumbar vertebra was primary and not secondary to this disease. For these reasons he thought the specimen was one of spondylolisthesis due to deficient ossification of the interarticular portion of the lamina of the fourth and fifth lumbar vertebræ, together with deficient development of the laminæ of the upper sacral vertebra. He agreed with Mr. Lawrence's view, that the patient probably had a weak spine; that as a consequence of this the shoulders were thrown back and an increased portion of the body weight was transmitted not only through the articular processes, but also through the spines. Evidence of this was to be seen in the presence of an articular facet upon the upper border of the spine of the fourth lumbar vertebra. As a result of the increased pressure upon the spines the laminæ of the fourth and fifth sacral vertebræ underwent elongation and became displaced downwards upon the back of the sacrum at the same time that the

bodies became displaced downwards and forwards, the connecting link between the separated portions in the case of both vertebræ consisting of the elongated laminæ. At a later stage secondary ossification of the laminæ and atrophy of the inferior articular processes of the fifth lumbar vertebra had occurred. That such a cause was possible, viz. deficient ossification of the interarticular portion of the fourth and fifth lumbar vertebræ, was demonstrated by the specimen he had exhibited, and by the specimens of spondylolisthesis in the museums at Berlin and Breslau. The thanks of the Society were due to Mr. Lawrence for the great trouble and care he had expended upon the examination of the specimen, and the drawings illustrating his views. The theory as to the ætiology of the condition which he had laid before them was an extremely ingenious one, and threw a new light upon the possible part played by spina bifida in cases of spondylolisthesis, while it went far towards explaining the occurrence of the deformity in other cases, for which, up to the present time, no adequate explanation had been forthcoming.

TWO CASES OF CONGENITAL MALFORMATION OF THE GENITAL ORGANS.

Shown by H. Macnaughton-Jones, M.D.

Cases of the kind that I desire to place on record through the 'Transactions' of the Society are sufficiently rare to warrant my doing so. I refer to certain congenital malformations of the genital organs. By a strange coincidence I have lately seen within a short period of time two peculiar cases of this nature.

Case 1. *Congenital atresia of the vaginal orifice with absence of the uterus and adnexa.*—A child, three years of age, and well developed, was sent to me by Dr. Harley

for atresia of the vagina. The entrance to the vagina was completely closed. The labia were quite rudimentary, the clitoris was normal, and beneath it a small orifice led to a normal urethra. The occluding membrane had the appearance of integument, and a prolongation of the perinæum. On incising this to the depth of about a quarter of an inch, I came on a rudimentary vaginal canal large enough to admit the point of the little finger. There were rudimentary nymphæ. I dilated the canal until it was large enough to admit the forefinger. Examining for a uterus, I found only a small nodule about the size of a large pea, which represented the cervix uteri, flush with the vaginal roof. I passed a dilator into the bladder, and through the rectum tried to detect a uterus. I could feel a body about three quarters of an inch in length, and less than a centimetre in width, altogether about the thickness of a good-sized quill. I next made a most careful examination, as did two others who were with me, but there was no vestige of adnexa to be found at either side. I enlarged the vaginal opening by a backward incision, and freed the lower portion of the mucous membrane of the small vaginal canal. This I brought down and fixed at the outlet. The urine was drawn off regularly, and the parts were kept perfectly clean. The effect was all that could be desired, and the external parts assumed sufficient of a normal appearance not to be in any way remarkable.

Case 2. *Congenital absence of uterus and adnexa with rudimentary mammary glands.*—A young lady, aged 22, was sent to me for examination under the following circumstances: she had never menstruated, though she had taken various emmenagogues and drunk chalybeate waters at several spas to induce the catamenia. There had, however, never been the least constitutional indication of ovulation. No vaginal examination had been made.

Under anæsthesia it was found that all the external

genitalia, vulva, clitoris, urethral orifice, and vagina were normal. No uterus, however, could be detected; a small knob-like projection could be felt at the vaginal roof. With a finger in the rectum, bimanually, a small body about the size of a marble could be isolated, but no trace of adnexa at either side, by the recto-abdominal, recto-vesical, or otherwise, could be felt, after a most careful examination by myself and those present. There was no difficulty in examination; the patient was comparatively thin, and there was no possibility of any error. The breasts were rudimentary, the nipples being like those of the male. It had been noticed that there had never been any psychical indication of an emotional or sexual nature, and a tendency to avoidance of, or indifference to, the company of the other sex characterised her actions in social intercourse. In other respects she was well developed.

A UTERUS WITH FIBROID TUMOUR UNDERGOING MUCOID CHANGE, SUCCESSFULLY REMOVED BY ABDOMINAL HYSTERECTOMY WITH INTRA-PERITONEAL TREATMENT OF THE STUMP.

Shown by Dr. Lewers.

Dr. Lewers showed a uterus with fibroid tumour undergoing mucoid change, successfully removed by abdominal hysterectomy with intra-peritoneal treatment of the stump from a patient 68 years of age. The tumour was equal in size to the pregnant uterus at seven months.

A RUPTURED UTERUS WITH DERMOID OVARIAN CYST THE SIZE OF A CHILD'S HEAD.

Shown by Dr. Lewers.

The rupture was probably due to the obstruction caused by the ovarian tumour. It extended through the left side of the cervix into the peritoneum. As far as could be ascertained the case seemed to have been one of shoulder presentation, and at all events delivery was said to have been effected by podalic version. Dr. Lewers saw the case some hours after the rupture, and had the patient moved into the London Hospital.

The case was admitted about twelve hours after the rupture had occurred. Dr. Lewers washed the peritoneum out with hot sterilised boric acid lotion, and drained the peritoneum by strips of 2 per cent. iodoform gauze passed through the rent into the peritoneum. The condition of the patient on admission strongly contra-indicated laparotomy, or even an anæsthetic. She died fifty-seven hours after the rupture. He had had one case of ruptured uterus recover under this line of treatment about eighteen months ago at the London Hospital.

Dr. Herbert Spencer thought it hardly fair that the result should throw any discredit on the use of iodoform gauze in cases of rupture of the uterus. In Dr. Lewers's case there was a dermoid ovarian tumour which, no doubt, had been bruised during the delivery, and should have been removed. There may have been special reasons why this was not done in Dr. Lewers's case, but he thought that had ovariotomy been performed the result would probably have been different.

LARGE INFLAMED CYST (? OVARIAN) COMMUNICATING WITH AN INFLAMED FALLOPIAN TUBE.

Shown by C. J. Cullingworth, M.D., and
J. S. Fairbairn, M.B.Oxon.

M. H—, aged 51, married, was admitted to St. Thomas's Hospital February 20th, 1900, with a cystic abdominal tumour which was inflamed. She had been married thirty years, and had had six children, the last one eighteen years ago. There had been no menstruation for the last three years; for the six years previous to this it had been irregular. On one occasion about seven or eight years ago she had a profuse hæmorrhage lasting fourteen weeks. No ovum was seen.

Just before she became pregnant of her last child, *i. e.* rather more than eighteen years ago, she first felt pains in the left side of the lower part of the abdomen. They were occasionally very severe, and she had to apply hot flannels and sometimes to go to bed. The course of pregnancy and labour was unaffected. These pains had continued at intervals ever since. For some years the abdomen had been increasing in size.

On January 21st, 1900, she got overheated and had to sit in damp clothes. The next day she had pains in the abdomen, and called in a doctor, who told her she had diseased ovaries. She tried home treatment for a month and, being then no better, came into the hospital.

On admission to the hospital, a large mobile tumour could be felt, giving distinct evidence of fluctuation. The width of the tumour was estimated at $7\frac{1}{2}$ inches; its highest part was $10\frac{1}{2}$ inches above the pubes. It was nearly central in position, and no part of it dipped into the pelvis. The uterus was normal in size and position, and moveable.

The abdomen was opened on February 22nd, with the expectation of finding an inflamed ovarian cyst. A thick-walled cyst was exposed, adherent to abdominal wall, to omentum, and to a number of coils of small intestine. Most of these adhesions were old. After separating a number of them, the cyst was tapped, and four and a half pints of pea-soup-like fluid, without odour, were removed. The pedicle, consisting of broad ligament and Fallopian tube, the latter much thickened by chronic inflammation, was now sought for, tied, and divided. Lastly, the cyst was peeled off a large, smooth, concave, membranous disc of thickened peritoneum, on which it rested, and to the opposite surface of which were adherent a number of coils of intestine and some omentum.

The right ovary was enlarged to the size of a plover's egg, was cystic and adherent to the left broad ligament. The right Fallopian tube was healthy but adherent. These were not removed.

The patient was making an excellent recovery. Dr. Fairbairn would now exhibit and describe the cyst, which presented points of unusual interest.

Dr. Fairbairn said that the specimen consisted of a cyst with about four inches of Fallopian tube and a small portion of mesosalpinx. The cyst had contained four and a half pints of fluid, and in the collapsed state measured $7 \times 6\frac{3}{4}$ inches. The tube was acutely inflamed, its mucous membrane being swollen and œdematous, and its lumen filled with broken-down epithelial *débris;* its walls were hard and much thickened. The outer surface of the cyst was covered with peritoneum showing beneath a white fibrous sheath. The inner wall of the cyst was covered with a layer of inflammatory lymph, and below this was a red velvety surface suggesting granulation tissue. The tube opened directly into the cyst by an aperture large enough to admit the tip of the little finger, the lining of the tube becoming directly continuous with the lining of the interior of the cyst. Round the opening of the tube were a few tags of mucous membrane, which might represent the remains of the fimbriæ or of the plicæ of the tubal mucosa. The fluid which was removed from the cyst was greenish in colour and viscid. On standing it separated into an upper fluid layer, and a lower layer containing shreds of lymph and showing microscopically many pus cells.

On microscopic examination of the cyst-wall the inner part was seen to be composed of fibrin containing a few cells, next layers of fibrin containing many cells and some blood-corpuscles, and externally layers of very cellular but well-formed fibrous tissue. No evidence of involuntary muscular fibre could be seen. The interest of the specimen lay in the difficulty in deciding whether it was a case of tubo-ovarian cyst or a large pyosalpinx. The continuity of the lining of the tube with that of the cyst rather suggested the latter view, but, on the other hand, the large size of the cyst, its well-marked fibrous wall—which microscopically showed no muscular tissue—and the absence of the ovary were against it. Further, the fact that the peritoneal coat could be easily stripped off the cyst-wall was in favour of its being an ovarian cyst growing between the layers of the broad ligament, for had the wall been formed from a distended tube the various layers would have been too much matted together to allow of this separation.

The specimen was referred to a sub-committee of Mr. Targett, Dr. Fairbairn, and Dr. Robinson, for further examination and report.

FŒTUS WITH ANASARCA AND LARGE PLACENTA.

Shown by Dr. Boxall.

THE ANATOMY AND NATURE OF TWO ACARDIAC ACEPHALIC FŒTUSES.

(See Plates VIII, IX, X, and XI.*)

By Arthur Keith, M.D., F.R.C.S.,
JOINT LECTURER IN ANATOMY, LONDON HOSPITAL MEDICAL COLLEGE.

(1) *The nature of the fœtuses.*—Although no records are to be found of fœtuses exactly identical with those described here, they belong to a well-known class, of which Ballantyne has collected all that is known up to the present date ('Diseases and Deformities of the Fœtus,' vol. i, p. 165, 1892). Interest in them is enhanced by the fact that they show lesions similar to those produced by hatching chicks under abnormal conditions of temperature and position (Dareste, 'Recherches sur la production artificielle des monstruosités,' 2nd edition, 1892). One of the specimens (see Plate VIII), the larger, is that of a full-time fœtus, for the centres are present in the lower ends of the femora. For the opportunity of dissecting this specimen I am indebted to Dr. Lewers. The other specimen is much younger, and corresponds in size and development to a fifth month normal fœtus (Plate IX). Both were females.

These acardiac fœtuses, perhaps better known as allantoidal parasites, belong, as is well recognised, to the series of double monsters. Between a very partial anterior or posterior dichotomy of the blastoderm and a complete division to form fully-developed twins every stage is known, and these parasitic fœtuses belong to the latter end of the series, the division being complete, except the

* All the Plates, except Plate IX and the description, except when mentioned otherwise, refer to the larger specimen.

posterior end of the blastoderm, which afterwards helps to form the allantois. The placenta remains in common, and the parasite draws its blood-supply directly from the placental circulation of the host twin. The parasite is reared and nourished as a bud on the placental circulation of the host. Its circulation is reversed ; the impure blood from an umbilical artery of the host enters the parasite by a single umbilical or hypogastric artery, and is returned to the circulation of the host by a single umbilical vein. The circulation in the parasite is dependent on the heart of the host. There is here the experiment made of rearing a human being as a bud (Plate XI).

The outstanding lesions in a parasitic fœtus are those of imperfect, arrested, and abnormal segmentation, and these lesions may be due in some degree to the abnormal circulation. But from experimental work we know that pathological processes antedate the appearance of an active circulation. The formation of blood islands and the fusion of these into blood-vessels, and the incursion of these vessels to form the leading blood-stems of the body are vitiated. We know, too, that unequal division of segmenting frog ova made artificially leads to formations similar to parasitic fœtus. I therefore regard a parasitic fœtus as the product of the lesser and imperfect part of a twin blastoderm. The origin of the condition is to be sought in the very earliest stages of segmentation of the ovum. Inquiry into the condition of the mother during the weeks following conception might throw some light on the cause.

Besides the similarity in the nature of their circulation, another character in which both specimens agreed was in the condition of the connective tissue of the body. In both it was thickly infiltrated with mucoid jelly-looking material, and greatly hypertrophied in amount. In both the thyroid gland was absent. The veins and arteries were equally thickly coated. Leucocytes were extremely abundant in the connective tissue and in the blood-vessels—

DESCRIPTION OF PLATE VIII,

Illustrating Mr. A. Keith's paper on the Anatomy and Nature of two Acardiac Acephalic Fœtuses.

The larger fœtus with the skin and subcutaneous tissue dissected away on the right side to show the cerebral and osseous systems.

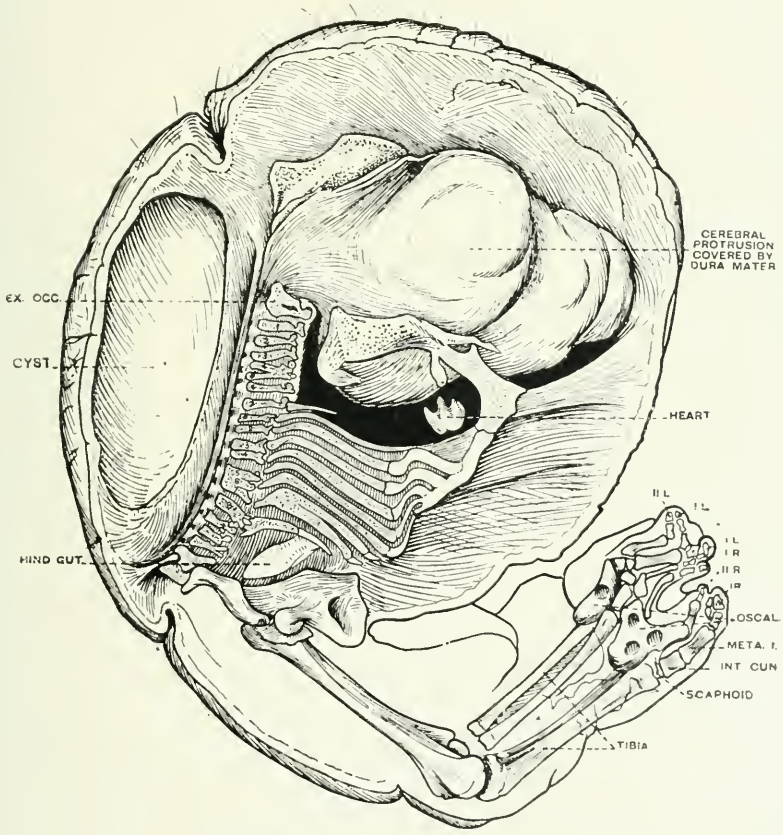

Bale & Danielsson, Ltd.

DESCRIPTION OF PLATE IX,

Illustrating Mr. A. Keith's paper on the Anatomy and Nature of two Acardiac Acephalic Fœtuses.

A mesial section of the smaller fœtus.

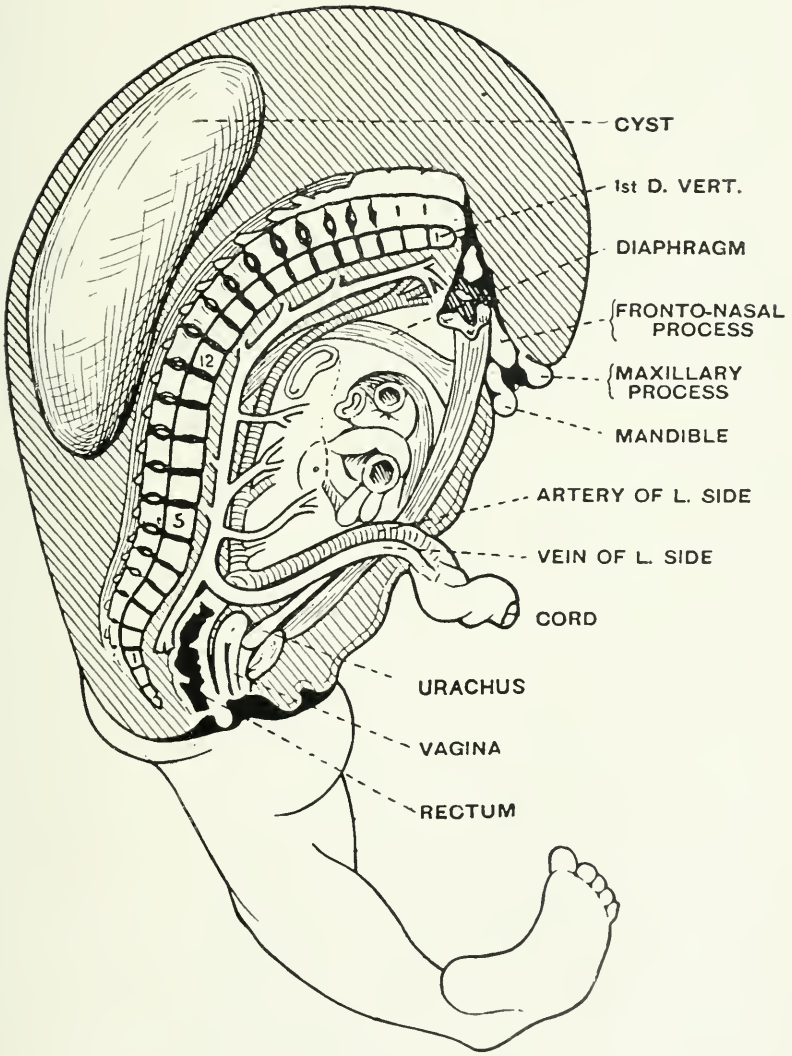

Bale & Danielsson, Ltd.

DESCRIPTION OF PLATE X,

Illustrating Mr. A. Keith's paper on the Anatomy and Nature of two Acardiac Acephalic Fœtuses.

Dissection of the larger fœtus to show the position of the heart and arrangement of vessels. The cerebral vesicle is shown in section.

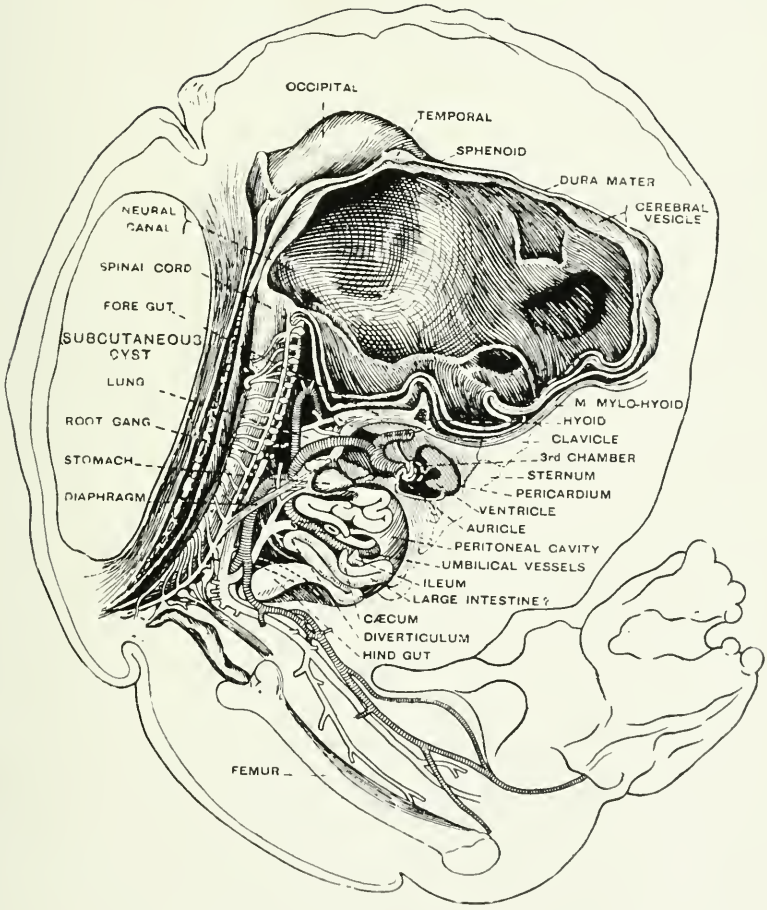

Bale & Danielsson, Ltd

DESCRIPTION OF PLATE XI,

Illustrating Mr. A. Keith's paper on the Anatomy and Nature of two Acardiac Acephalic Fœtuses.

The vascular system of the larger fœtus. In the right hand lower corner the probable connection between the placental circulations of the "host" and "parasite" is shown.

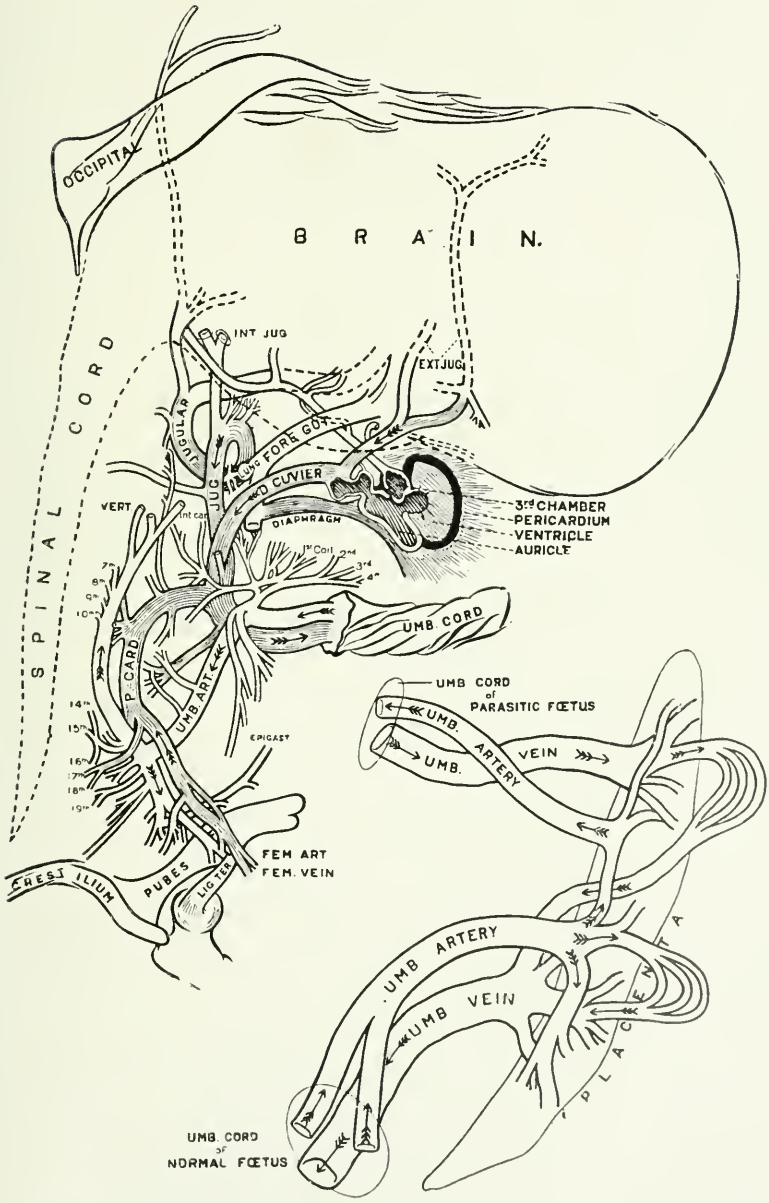

Bale & Danielsson, Ltd.

almost equal in number, or even the leucocytes predominated. Open, loose forms of adenoid tissue occurred abundantly throughout the tissues of the larger fœtus; and in the smaller, lymphatic glands were abundant and in normal positions.

The type of segmentation, the extent to which it has been perverted, is sharply contrasted in the two specimens. In the smaller fœtus (Plate IX) the appearance suggests that the cell or cells of the blastoderm that go to the formation of the anterior half of the trunk were blasted, and arrested in development in the blastodermic stage. The body begins with the first dorsal segment; all the segments in front of that, cervical and cephalic, have never been formed, and hence the absence of the foregut and all its derivatives, of the brain, heart, head, and teeth. Three little processes, shown in Plate IX, surround a depression, probably the stomodæum, and may represent the fronto-nasal, maxillary, and mandibular processes. A small fragmentary mass of fibrous tissue containing bone may represent the basis of the skull. The arm-buds show three segments representing the hand, forearm, and arm, but are short, imperfect, and unshapen. The posterior half of the trunk, from the first dorsal segment onwards, is perfectly developed, each segment producing its neurons and visceral parts perfectly; the only point to be observed as abnormal is the condition of marked inversion of the feet. In the bigger fœtus segmentation has been arrested at both extremities of the body; there is a marked condition of hydrocephalus; vertebræ are imperfectly separated from each other; so are the ribs; the arms are rudimentary; the buds of the hinder extremities, owing to the arrest of the segmentation posteriorly, are left in contact, and a symelian extremity is produced.

(2) *External appearance.*—Both fœtuses present the appearance of inflated commas. The larger measured 40 cm. from end to end, and 17 cm. from back to front. After having been in spirit for some time it weighed

1600 grammes. The small specimen measured half the dimensions, and a quarter of the weight of the larger.

The larger fœtus on its right side presents no opening or structure whatsoever, but on the dorsal margin, where the body meets the conjoined lower extremities, there is a depression which may represent the anal pit or blastopore, and at the bottom of which terminal fibres from the spinal cord and its sheath end. On looking at the left aspect of the fœtus a number of features are to be noted. Near the centre of the cephalic end of this aspect is a wide pit, bounded dorsally by the two eyeballs, which lie side by side, ventrally by imperfectly developed lips and gums that contain the well-developed crowns of all the milk-teeth and the germ of the first permanent molars. Broadly speaking, the skull in front of the coronal suture is almost undeveloped; the fronto-nasal and maxillary processes have been arrested in development, and hence nearly all the bones of the face are absent. The mandibular arch is well formed and complete. The buccal cavity ends blindly behind in a narrow recess containing a small conical tongue, covered with filiform papillæ, and evidently representing the tuberculum impar only, the V-shaped fissure containing the foramen cæcum being situated at its base. This cavity, which represents the primitive buccal cavity and part of the pharynx, terminates blindly at a piece of cartilage evidently representing the hyoid bone. The œsophagus, or more correctly speaking, the foregut, begins blindly at the hyoid. Above the eyes is seen the representative of an eyelid, and at the left extremity of the buccal cavity a fold of skin, in the position of, and evidently representing, the external ear. There is no such process on the right side, and neither on the one side nor on the other is there any trace of an auditory meatus, nor an internal ear. Behind the mouth, and overlapping the umbilical cord as it escapes from the abdomen, is a great flabby fold or process of skin, which may represent an arm-bud, for the vertebral end of the scapula terminates in its posterior dorsal portion, but

the anterior part is attached to the mandibular arch. It contains no definite structure; I failed to discover nerves entering it; it contains merely an amorphous mass of soft fibrous tissue. It is the extensor aspect of its symelian extremity that is seen in viewing the left side of the fœtus.

It will be observed that the fœtus is asymmetrical. The right side of the cephalic extremity especially has become so enlarged that it has thrust the face, the mouth, and the umbilicus almost to the centre of the left side. This asymmetry is mainly due, as may be seen in Plate VIII, to the cephalic part of the neural canal having become distended and burst through the skull wall. It protrudes as a great hernia on the right side, and has thrust the skull, tongue, and thoracic organs to the left side. The skull rests like a small cap on the left side of the great cerebral vesicle. The shoulder girdle of the right side lies on the dura mater over the dilated brain vesicle.

3. *The circulatory system.*—Although nothing is known of the placenta of these fœtuses, yet there can be little doubt, reasoning from the arrangement found in similar specimens, that the relation of the circulatory system of the "allantoidal parasite" to the host fœtus was something essentially like the arrangement sketched in the lower right corner of Plate XI. The form of the heart and the arrangement of blood-vessels are incompatible with an independent circulation in the parasite. There are certain very remarkable and abnormal features in its circulatory apparatus. In the first place, it is nourished on impure venous blood; the placenta, the parasite, and the hind-quarters of the "host" fœtus are supplied with the same quality of blood. In the second place, the circulation in part is reversed; the blood enters the body by a single umbilical artery, and leaves it by a single umbilical vein. The umbilical artery on entering the abdominal cavity gives off three branches (Plate XI), which supply the alimentary canal and septum transversum (diaphragm), and then ends in a median dorsal vessel

(aorta) opposite the seventeenth segment (tenth dorsal). At the point of entrance into the aorta the blood-current divides in two, one current passing backwards in a normal direction into the femoral vessels, the other passing forward in the aorta towards the cephalic extremity of the fœtus. The aorta gives off segmental vessels, and ends opposite the fifth segment (fifth cervical) by giving off a vessel clearly representing the vertebral, and two others, which probably represent the right and left carotid arteries, the right being the larger, and dividing into an external and internal branch. The aorta has no direct connection with the heart. All the structures developed from the second, third, and fourth arches are either absent or present in the most incomplete form; probably the arteries of those arches were never formed, or, if they were, disappeared subsequently; at any rate the heart showed no trace of an aorta, nor could it pump blood into the arteries. The arterial system, from a physiological point of view, may be regarded as part of the host fœtus.

One peculiar character is the presence of a single umbilical artery, giving off mesenteric branches. The explanation of this feature probably lies in the segmentation being arrested at the twentieth vertebra (first lumbar), and hence the hypogastric arteries (in this case conjoined) would arise before the mesenteric arteries are given off, that is, supposing the hypogastric arteries to represent the continuation of the aorta backwards, a theory now commonly accepted. It is possible, however, that the umbilical artery may represent in part, at any rate, the omphalo-meseraic. In the smaller fœtus it is the left hypogastric artery that is present, and the mesenteric arteries arise from the dorsal aorta. The heart is relatively a very small three-chambered organ. Its position is shown in Plate VIII, lying under the brain capsule, close to the hyoid bone, thus retaining a very early embryonic position. The auricular cavity (sinus venosus ?), lying embedded in the septum transversum, has very thin walls and no valves (Plate XI). The ventricle has a

very thick wall, a minute cavity communicating with the auricle by an opening 2 mm. in diameter. The ventricle lies within a serous sac, the pericardium. A third chamber, represented actual size in Plate X, but exaggerated in Plate XI, is obscure in its nature. It is filled with a meshwork of bands, with no distinct cavity, and communicates with the auricle by an opening which allows an ordinary pin to be passed through it, and with the ventricle by a foramen still smaller, and which may have been produced artificially, as its lumen is not distinct. A vessel leaves this chamber and becomes larger as it passes backwards to the base occipital region, where it ends. The small chamber may represent the bulbus arteriosus, and this vessel the primitive ventral aorta, but no communication could be traced between it and the carotid or vertebral branches of the dorsal aorta. With this doubtful exception, the heart is wholly a venous structure, and has no connection with the arterial system, and, as far as it was functional, could only have assisted in forcing the blood along the veins to the placenta. The heart in this case serves the placenta, and not the fœtus. In the smaller fœtus the heart and cephalic arteries were absent.

It is not an easy matter to identify the trunks of the venous system (Plate XI). In the diaphragm (septum transversum) three great veins meet to form the umbilical vein. The posterior one represents the right, or perhaps both posterior cardinal veins, for it receives the vertebral branches of both right and left cardinals. The anterior one may represent both, but more probably the right jugular, and the trunk running from the auricle to the junction of the cardinal and jugular probably represents the duct of Cuvier of the right side. The vein which joins the duct of Cuvier in the neighbourhood of the heart comes mostly from the right aspect of the head over the forebrain, and may represent an external jugular vein. The vein from the alimentary canal joined the duct of Cuvier in the diaphragm.

The outstanding features of the circulation then, are these :

(1) The heart, if functional at all, drives the blood along the veins into the placenta.

(2) It has lost, or never had, a connection with the dorsal aorta, through absence or obliteration of the arteries of the visceral arches.

(3) The main arterial and venous trunks seem all to belong to the right side, those of the left being absent.

In the smaller fœtus the umbilical vein is the left, and its nature is quite obscure. It ends in the left cardinal vein. It runs outside the peritoneum and probably represents the left umbilical vein.

4. *The umbilical cord.*—Its length is not known. Microscopical sections show only one artery and one vein; there is no trace of another vessel, or of the cavity of the allantois. The tunica intima of the artery is enormously hypertrophied, and the lumen almost obliterated. Its muscular coat is extremely thick, the longitudinal fibres being especially marked. The occlusion of the artery is probable that which normally occurs. The wall of the vein is also thick, and the clot that occupies its lumen shows a considerable proportion of leucocytes, probably one to every fifty red blood-corpuscles ; the substance of the cord and its epithelial covering, two irregular layers of cells, are normal in appearance, and it is remarkable that the subcutaneous tissue all over the body shows a remarkable resemblance to Wharton's jelly, macroscopically and microscopically.

5. *Capillary lymphatic circulation.*—The dropsical condition of such fœtuses, the hypertrophied and mucoid subcutaneous tissue, the large cysts that occur throughout this tissue, such as the one shown in Plate VIII—and in this case there were several more, all on the right side—the dilatation of the neural canal with fluid, are commonly regarded as the mechanical results of an imperfect circulatory apparatus. Such a dropsy occurs in fœtuses with a perfect circulatory apparatus. Smith and Birmingham

('Journ. Anat. and Phys.,' vol. xxiii) in a case they examined found no evidence of a lymphatic system, and ascribed the condition to this defect. In the small fœtus the lymphatic glands were well developed. It is improbable that the condition is the result of any simple mechanical cause; it is much more probably, as Dareste's research would lead one to suppose, that there is from the very first some grave lesion in the normal physiology of the cell. The presence of the parasitic fœtus itself is part of the disease. The condition of the arterial system of this fœtus is in conformity with Dareste's observations in the chick. There is a disturbance in the formation of the blood-islands of the area vasculosa; the contents of those islands, in a normal development, reach the embryo by the formation of a vessel which grows into the embryo to form the aorta, the posterior part first, the anterior part, which joins the heart, being formed later. In a dropsical chick this formation is disturbed, and the failure of the aorta to join the heart in this fœtus may be the result of such a primitive maldevelopment of the blood-islands. The neural canal begins to dilate as soon as the neural ridges fold to form it. Too little is known of the manner of secretion and absorption of the cerebro-spinal fluid within the neural canal to hazard an opinion as to the cause of the hydrops, but its early appearance is distinctly against any simple mechanical obstruction.

The extent to which the subcutaneous tissue has hypertrophied and become distended, and its cystic formation may be seen from Plate VIII. Microscopic sections of this tissue, cut in paraffin and stained with carmine and methyl blue, show that it has much the appearance of the substance of the umbilical cord. There are numerous branching connective-tissue cells; fibres are present evidently free from cells; it is impossible to recognise in section the larger arteries from the larger veins; both have very thick walls, the tunica adventitia being markedly hypertrophied. It is doubtful if they contain muscle-cells, although within the tunica adventitia and

outside the tunica intima there is a layer of fusiform nuclei such as occur in non-striated muscle. Small rods of cells with a scarcely recognisable lumen probably represent arterioles. At several points these small vessels break up in trabecular tissue, in the manner usually ascribed to arterioles in the spleen. The capillary system appears to be represented by the dilated irregular spaces of this trabecular tissue. In the neighbourhood of blood-vessels there are numerous leucocytes, and in the neighbourhood of certain round spaces, evidently the beginnings of veins, are colonies of leucocytes arranged in compartments that radiate round the centre space. Leucocytes are being formed. Giant-cells containing four to five highly stained large nuclei may be seen, and stages between these broken-down giant-cells, and free and scattered leucocytes. Red blood-corpuscles are seen only in the larger blood-vessels. Here, then, there seems to be a very primitive arrangement of tissue; it is impossible to distinguish microscopically the capillary spaces from the lymph spaces; at any rate they are in free communication. With the exception of three or four quite small glands in the mesentery, nothing of the lymphatic system was apparent to the naked eye. One would not expect the ordinary arrangement of thoracic ducts in such a fœtus, and if one were present it would be almost impossible to detect it among the fibrous tissue of the prevertebral region. No lymphatic duct was seen, but it may easily have escaped even minute search. But lymphoid tissue was abundant, not only throughout the subcutaneous tissue, but numerous follicles occurred in the submucous coat of the intestine, stomach, and trachea. Teased preparations of the bone-marrow from the lower end of the femur, stained in logwood, showed the Haversian space crowded with rounded cells with large round deeply stained nuclei. Amongst these cells, but much less numerous, were rounded unstained cells containing hæmoglobin. The fusiform bone corpuscles, with oval nuclei, could be seen within the spicules of

bone, and a layer of similar but irregular corpuscles were ranged round the walls of the Haversian spaces. There was no trace of the spleen, thymus, thyroid, or tonsil. There was much evidence that leucocytes were being produced abundantly. It is also of interest to note, in connection with the hæmopoietic functions of this fœtus, that the liver was not formed, and the kidney very small.

6. *Signs of arrested and abnormal segmentation.*—Segmentation, a process that appears so early in the life of the blastoderm, had been interrupted and taken place irregularly. Evidence of that is seen in the imperfectly separated laminæ of the fourth and fifth cervical vertebræ (Plate VIII). Again, it is seen in the third and fourth and the fifth, sixth, and seventh dorsal vertebræ. It is also seen in the imperfect cleavage of the seventh and eighth ribs. Segmentation posteriorly has been arrested at the twelfth dorsal vertebra, the sacral cartilage lying over the united pelvic bones being wedge-shaped, and unsegmented. The vertebræ corresponding to the lumbar, sacral, and coccygeal regions are undifferentiated, and it is from the sides of this part of the body that the leg buds spring. The limb buds when they appear are not separated but in continuity, and hence the symelian extremity. It has been already seen that development was arrested at the cephalic extremity of the fœtus, the frontal bones being small, the bones formed in the fronto-nasal and maxillary processes being absent. The structures derived from all the visceral arches, with the exception of those derived from the mandibular, are only partially developed or absent.

7. *The respiratory and alimentary tracts and derivatives* (see Plate X).—The buccal cavity has been described with the external configuration. It ends in a blind recess, thrust over to the left side, and in this recess lies a papilla representing the tongue. There is no trace of the palate, nor upper teeth, but in the lower gum lie the dental sacs of all the milk teeth, the crowns of the incisors being

completely formed. The enamel germs of the permanent teeth are also present. On the floor of the mouth, between the gum in front and the small tongue behind, was a median fold, the frænum linguæ, and on each side a fold, in the substance of which were five little buds of the size of millet seeds, lying closely one behind the other, evidently the "Anlagen" of the sublingual and submaxillary salivary glands. Nothing of the parotid gland was seen.

The tongue is fixed on an irregular piece of cartilage, seen in the anterior end of the foregut in Plate X, representing the hyoid bone. It was joined on the left side by a cartilaginous stylo-hyoid ligament. Muscles passed between the hyoid and mandible (mylo-hyoid and genio-hyoid) and were pulled out into long bands over the greatly distended cephalic vesicle. The genio-glossus is small but developed. When a microscopic examination was made of the foregut it was seen to have the structure of trachea and not œsophagus. There is a connective-tissue coat; well-developed cartilages forming two thirds of a circle; greatly developed submucous coat with large mucous glands opening into the trachea by widely dilated mouths. They also seemed to suffer from hydrops. The cilia of the lining epithelium are very evident. There is no trace seen of an œsophagus in such a section. On what appears to be the dorsal aspect of the foregut, but which, owing to the asymmetry of the fœtus, is in reality the ventral, there is a diverticulum ending in a solid string, which branches irregularly, and is lost in the connective tissue lying above the diaphragm and inside a curve of the jugular vein. I identify this as the "Anlage" of the lung, but a microscopic examination of the tissue in which the process ends shows only irregular spaces, many of them venous or lymphatic, and none of them with a characteristic epithelial lining. There is no pleural cavity. Between the basis cranii and the peritoneal cavity there is a considerable septum of connective tissue; the part bounding the peritoneal cavity contains muscle and the auricle of the heart, and represents the

diaphragm. The looser tissue in which the lung bud ends is the "Anlage" of the mesoblastic tissue of the lung and connective tissue of the neck and thorax.

As the foregut passes through the diaphragm it dilates. In part the dilatation is probably stomach, but in part of it at least, villi are distinctly present, and it must be regarded as belonging to the duodenum. In the diaphragm, or rather just as it enters the diaphragm, there is a slight fusiform enlargement, and this is undoubtedly stomach. If that is so the stomach is entirely developed within the septum transversum, and part of the duodenum too. A bud of very small size has grown into the septum from the foregut between the gastric and duodenal enlargements. There is another smaller process of the alimentary canal arising at the point at which the foregut leaves the diaphragm to enter the small peritoneal cavity. It lies in the substance of the diaphragm, and may represent one of the pancreatic buds. The gut is bound closely to the left wall of the small peritoneal cavity by a short mesentery. There is an opening in the peritoneal cavity at the umbilicus, through which the umbilical vessels escaped, and through this opening, which may have been caused by pulling on the cord, the cavity of the peritoneum communicated with that of the amnion. There is no trace in the peritoneum of any diverticulum which might have become the pleura. The gut is divided into an anterior and posterior part, having evidently been broken across at a very early stage, as the ends that ought to be in continuity are conical and closed. There are two cæcal diverticula at the proximal end of the posterior division of the gut. The larger of these has a valvular mouth, and represents the ileum; the smaller is the cæcum. Another very small diverticulum occurs on the posterior portion of the gut; it has probably no morphological significance. The gut has broken across or failed to develop at the point at which the yolk-sac was attached. The rupture in the gut may be due to the abnormal development of the intra-abdominal part of the

umbilical artery. The hind gut terminates in an enlarged cæcal extremity, covered on its ventral aspect by peritoneum; it is embedded dorsally in connective tissue within the cavity of the pelvis, but it has no continuity with any tissue or structure in its neighbourhood; it could be removed from its natural bed with great ease. It terminated over an inch from the anal depression. The lining cells of the great gut were distended with mucus, merely their outlines being visible. In the small gut the villi were present, and in stomach, small intestine, and great intestine, the usual tubular glands were seen. Solitary follicles were abundant, and there were a few lymphatic glands in the mesentery. In the smaller fœtus the gut began blindly; the foregut and its derivatives were absent; there was no liver, no pancreas, no spleen. There were two cæcal processes, one probably representing Meckel's diverticulum. The rectum was normal.

8. *The genito-urinary system.*—This system was well and normally developed in the smaller fœtus, the suprarenal bodies being very large. In the larger fœtus, besides the anal depression shown in Plate VIII, there was no evidence of external genital organs. No trace of bladder, urachus, or allantois could be found either in the abdomen or in the umbilical cord. If they had been formed they must have completely disappeared. The kidney lay in front of the twelfth or thirteenth vertebræ (fifth and sixth dorsal). The right kidney lay to the outer side of the ventral aspect of the posterior cardinal vein; the left kidney on the left wall of the peritoneal cavity at some distance from the cardinal vein. The renal arteries were derived from the umbilical; the veins joined the posterior cardinal. The left kidney is the more instructive of the two. The short ureter is seen to join a duct leaving the ovary (the Wolffian duct), the kidney being known to be derived embryologically from the Wolffian duct, and hence the connection. The ureter and its pelvis are represented on the right side by a membranous sac, which is closed, and almost equals the

kidney in size, into the centre of which it protrudes. A section through the right kidney shows the pelvis in the centre, made up of spindle-cells, many with the rod-like nuclei of non-striated muscle; the outer coat, which here and there runs into the substance of the kidney, is undoubtedly muscular. In the centre of the kidney, surrounding the pelvis, are densely packed tubules of various sizes, and some of the larger can be seen perforating the pelvis. The outer half of the kidney is composed of cortex, the greater part of which is made up of glomeruli; the tubules are but slightly convoluted; glomeruli are being formed under the capsule; no loops of Henle could be distinguished.

The hilum of the supra-renal body, which opened on the surface turned towards the kidney, was seen on section to be lined with large cells, many of them apparently encapsulated, grouped in alveoli, each alveolus being surrounded by a circular sinus. The cells in the alveoli stained more deeply than those of the cortex, which ran in irregular rows towards the surface, except where secondary radiations took place round veins. The central alveolar groups evidently represent the sympathetic "Anlage." The renal ganglion was very large.

The genital glands lay within the peritoneal cavity suspended by a mesentery, and showed the typical structure of fœtal ovaries. The ova were large, many were in a process of division; others were being encapsulated by the round-celled and fusiform-celled stroma. The ova were especially large and closely packed towards the hilus or attachment of the mesovarium. In the mesovarium lay many Wolffian tubules, with very thick walls made up of fusiform short cells and lined by a single layer of non-ciliated epithelium. A hydatid body, belonging to the Wolffian tubular system, projected over the caudal pole of the ovary. The Wolffian duct was present in it proximal part only; it ended and became lost in a slight band of fibrous tissue.

9. *Bones and ligaments.*—In monsters of this kind the

hind limbs are commonly developed, while the fore-limbs are not present or only partially developed. That is so in this case, and the limbs of the left side are less well developed than those of the right. The fore-limbs are represented only by the shoulder-girdles (Plate VIII). The supra-scapular cartilage is large, and sends a process into a fibro-muscular band representing the teres major. The infra-spinous part of the scapula is well developed; the supra-spinous part is absent; the spine is present and ends in an acromion process. The process is connected by a ligamentous band with a bone which may be a clavicle or primitive form of coracoid reaching the sternum. This coracoid is bound closely to the proximal end of the right sternal bar by fibrous tissue, while at its outer end it is in cartilaginous continuity with that part of the scapula representing the glenoid cavity. This bone undoubtedly occupies the same position as the meta-coracoid of the ornithorhynchus. But it must not be forgotten that the shoulder-girdle has been raised by, and stretched out upon, the greatly distended brain capsule, and this distension may not only have altered the shapes of the bones but altered their primitive relationships. The prolonged end of the scapular spine may represent the clavicle. There is, however, a small nodule of cartilage lying below the position of the glenoid cavity, and connected by ligamentous bands with the surrounding bones, one of which may be the costo-coracoid ligament. This cartilaginous nodule may represent the coracoid or humerus. It was surrounded by a loose mass of friable connective tissue in which some vessels and nerves ended.

In the shoulder-girdle of the left side there is a large dorsal piece of cartilage, the supra-scapular. It has in its ventral part a round plate of bone developing in it, and this plate of bone is in continuity with—although a line of union is quite visible—an oblong plate of bone developed in membrane. Its lower (ventral) end is suspended in fibro-muscular bands representing the pectoralis major,

sterno-mastoid, and sterno-hyoid muscles. The proximal end of the sternum is not developed.

The pelvic girdle has fused into a solid piece, under the truncated sacral-like termination of the vertebral column. The part belonging to the right side is double the size of that belonging to the left. The limbs have united so that the extensor surfaces form a combined dorsal surface, great trochanter of femur lying against great trochanter, and external condyle against external condyle. The two ossa innominata have fused together; the gluteal surfaces form the dorsal aspect; the ischia are united; the cartilaginous pubic rami form one mass. A foramen, representing the combined great sacro-sciatic foramina, allows two great sciatic nerves to escape together from the pelvis.

Fibula is turned towards fibula. In the right leg the tibia is much larger than the fibula, and enters alone into the formation of the knee-joint, which is furnished with a normal ligamentous apparatus. But the left tibia and fibula are of equal size and enter equally into the formation of the knee-joint, a plate of fibro-cartilage, evidently the "Anlage" of the semilunar cartilages separating the femur from the lower two bones. The feet are united along their fibular (outer) borders, the soles forming a continuous plantar surface. It is difficult to separate the os calcis of one side from that of the other; they are closely bound by fibrous tissue (Plate VIII). The os calcis in its distal part has undergone division or dichotomy. The left is undivided. The astragalus is present on both sides and shows no trace of division. In front of the astragalus and right division of the os calcis of the right limb are three blocks of cartilage representing the scaphoid and inner two cuneiform, which support two digits, the great toe and the second. The great toe has undergone dichotomy. The other division of the right os calcis carries two digits, one a great toe, the other a second, but in this case the great toe has not undergone dichotomy. The left foot is made

up of os calcis, astragalus, scaphoid, internal and middle cuneiforms, two digits, the great toe dividing as shown in Plate VIII. The right leg, although only one tibia and fibula are present, carried two sets of extensor muscles, in agreement with the divided foot.

The vertebræ, ribs, and sternum.—There is evidence of nineteen vertebræ, the nineteenth being a composite sacral-looking body, with fused nodules of bone embedded in its cartilage. The two sides are not symmetrical. For instance, on the right side, between the bodies of the second and third vertebræ, a nodule of bone is intercalated with a corresponding lamina and nerve, representing a vertebra wanting on the opposite side. The irregularities in the complete segmentation of the laminæ of one side do not show an exact correspondence with the irregularities of the opposite side. The neural plates of the atlas are connected ventrally by a cartilaginous mass of tissue, in which is situated, adherent to the body of the axis, a nodule of bone representing the body of the atlas. At the body of the tenth vertebra evidence of two ossific centres for each body appear; at the thirteenth segment the centres are separated by a mesial band of cartilage which passes from one intervertebral cartilage to another. The bodies of the fourteenth and fifteenth vertebra have a centre on each side and one in the middle, three in all for each body. The sixteenth vertebra is present only on the right side. The body of the 17th vertebra has only one centre, the eighteenth two, and the nineteenth shows evidence of five centres in all, one central and four lateral.

The fifth, sixth, and seventh vertebræ carried small spicular ribs, connected by cartilage with the transverse processes. The transverse processes were perforated by the vertebral artery. The eighth to the sixteenth vertebræ carried ribs, the three posterior failing to reach the sternum, as shown in Plate VIII. On the left side the sixth and seventh vertebræ carried spicules, representing ribs; the eighth to the fifteenth carried larger, although

irregularly developed, ribs. On the left side there was no sternal bar. The sternal bars were unfused in the smaller fœtus.

The skull.—The two parietal bones and supra-occipital are readily identified. The right exoccipital is shown in Plate VIII, but no bone representing the left exoccipital was recognised, unless a small nodule over the atlas represents it. The form and connections of the inferior mandible are remarkable. The two halves are completely united at the symphysis by bone. Alveolar borders have risen up in the neighbourhood of the symphysis and form six dental pits. The jaw is flattened on the brain capsule, its symphysis being pulled out into a beak by a wide band of fibres, which ends in the subcutaneous tissue. On the left side the mandible ends in a flat plate of bone overlying a reticulated plate of bone representing the left half of the sphenoid. This mandibular plate is evidently the palato-quadrate bone. A foramen separates it from the thicker horizontal part of the mandible, which abuts against that part of the sphenoid lying beneath the opening for the eye. A nodule of bone situated in a recess beneath and behind the palato-quadrate, and continuous through fibrous tissue with the mandible, is probably the malleus. The squamous and petrous parts of the temporal are also represented. On the right side the proximal end of the mandible terminates in a nodular composite plate, corresponding evidently to the elements on the left side. The sphenoid is represented by a complicated reticulated plate of bone on each side, the lateral halves being connected under the jaw by a fibro-cartilaginous plate. This is due to the fact that the brain capsule has broken through the skull at the space occupied by the right petrous bone, thrusting the basi-occipital, the basi-sphenoid, and ali-sphenoid of the left side away from the ali-sphenoid and squamous part of the temporal on the left. The body of the pre-sphenoid has been stretched into a flat plate of bone, lying in fibro-cartilage, under the optic foramen.

A thin fibrous septum separates one optic foramen from the other. Immediately over this septum is a thin capsule of cartilage, containing the two olfactory bulbs. Above these, again, are two small plates of cartilage, one containing a nodule of bone representing the frontal.

The nervous system.—Unfortunately the central nervous system was scarcely in a state for microscopical examination, and such an examination would have been very difficult, for there was great distortion in its cephalic part, and at places distension had been so great that merely the fibrous tissue of the membranes represented the wall of the cerebral vesicle. Both olfactory bulbs and both optic vesicles were present, lying in contact, but each had its own stalk. A mass of epithelial *débris* within the eyeball was probably the remains of the lens. A mass of fibrous tissue connected the buccal cavity and the base of the skull, but no structure was identified as pituitary body. Not one of the motor cranial nerves was seen, but the fifth and ninth were made out, both being very small and irregular. It was found impossible to trace out the fifth nerve owing to the complication of structures in which it lay. The ninth nerve ended superficially on the two tubercles representing the basal parts of the tongue. No trace of auditory nerve or capsule was seen. There were twenty pairs of spinal nerves (Plate X). The posterior root ganglia were well developed, so were the ganglia of the sympathetic system. The anterior roots were very small, varying from one fourth to one half of the posterior roots. The neural canal in the spinal cord contracted as it approached the sacral end; in the cervical region it measured 10 mm. in diameter.

The nerves of the right side attain a much more extensive development than on the left. The first seven nerves on the right side form a plexus. From the loops between nerves I-II-III-IV pass off three trunks to end in the greatly distended scalp of the right side. They represent the large and small occipital and great auricular.

On the left side nerves I-V united into a single small trunk which ended as the great occipital. It sent branches towards, but not quite to, the area of skin surrounding the primitive buccal cavity. The phrenic nerve arose from the loop between I-II. A large trunk was formed by V-VI-VII and passed out to end in the muscles and connective tissue round the shoulder girdle. Nerves VIII-XIV are intercostal and small. The roots of the middle numbers of this group are horizontal; the roots of the upper ascend, the roots of the lower descend. Nerve XV ends as the external cutaneous, but also sends a twig to XVI, which with XVII, XVIII, and XIX, form the anterior crural and obturator nerves.

A twig from XIX and XX ends as cutaneous nerves in the region of the anal depression; XVIII and XIX send also a considerable trunk to join with nerves from the right side to form the sciatic nerve which passes through the single sacro-sciatic foramen. On the left side nerves V and VI are small and end in the muscles connected with the shoulder; VII-XIII are intercostal; XIV represents in distribution the last dorsal nerve; XV and XVI are large trunks, and end as the anterior crural nerve of the left side; XVII and XVIII send off the great sciatic nerve and cutaneous branches to the skin of the thigh region; XIX is small and terminates in the skin near the anal pit.

The muscular system.—Not a single muscle was clearly differentiated from the surrounding connective tissue. They were arranged in ill-defined sheets; at some points the muscles became fused and inseparable from the subcutaneous tissue; deep muscles disappeared in parts of their course in bands of tissue; all the trunk muscles were represented, but attempts to keep accurate records of their arrangements were given up.

The PRESIDENT congratulated Mr. Keith on his excellent demonstration of a difficult teratological subject. He himself had prepared a communication on acardiac monsters, published in the Society's 'Transactions' for 1880 (vol. xxxi), based on a specimen sent by Mr. Trestrail, which he now believed to be

rather an "acardiacus acephalus monopus" than an "acardiacus mylacephalus." It consisted of one complete lower extremity, the fellow being rudimentary, one kidney, a piece of intestine, well-developed external female organs, and the os sacrum. In acardiac twins œdema was always more or less marked; Dr. Boxall's specimen, unlike Mr. Keith's in every other particular, was highly œdematous, and turned our attention to the precise significance, not as yet determined, of fœtal œdema under different conditions. In acardiacs it was clearly due to the same disturbances in the fœtal circulation which caused, more or less directly, the monstrosity itself. In cases like Dr. Boxall's it was otherwise. Was it not sometimes due to constitutional disease in the mother?

A CASE OF EXTRA-UTERINE GESTATION IN WHICH FŒTAL DEATH OCCURRED AT TERM AFTER SPURIOUS LABOUR, AND ABDOMINAL SECTION WAS PERFORMED FOUR TO FIVE MONTHS LATER.

By John Phillips, M.A., M.D., F.R.C.P.,

OBSTETRIC PHYSICIAN, KING'S COLLEGE HOSPITAL; LECTURER ON PRACTICAL OBSTETRICS IN KING'S COLLEGE; EXAMINER IN MIDWIFERY, ROYAL COLLEGE OF PHYSICIANS.

(Received February 16th, 1900.)

(*Abstract.*)

The patient, aged 31, with three children, the youngest nine years ago, menstruated last normally in November, 1896 (the exact date being uncertain). About a month later she was seized with severe abdominal pain, and was ill for fourteen days. Subsequently all the symptoms of a normal pregnancy developed; she had, however, frequent and prolonged attacks of pelvic and abdominal pain. At term a spurious labour occurred, and subsequently the signs of pregnancy became less marked and the abdomen less distended. From four to five months afterwards she was seized with much pain and fever after a rigor. The abdomen was opened, and a full-term dead fœtus removed from an extra-uterine sac. The placenta, which was putrid, was removed without hæmorrhage. The patient made a good recovery, and is now in good health.

The patient, Mrs. C—, æt. 31, has three children, all alive, the youngest born nine years ago. She has always been a strong, healthy woman, and has never had inflammation of the bowels or complained of dysmenorrhœa.

She menstruated regularly up to and during November, 1896; she cannot remember the exact dates of the appearance and cessation of the flow; it was, however, (she is sure) a natural period in every way.

On December 14th, 1896, the patient noticed a discharge of blood from the vagina; this was followed by an attack of severe abdominal pain, mostly in the left side; so severe was it that she could not move for some time from the chair on which she was sitting; she was ill for fourteen days and began to suffer from morning sickness.

During January, 1897, there was no further hæmorrhagic loss, nor any more abdominal pain, but in February the abdominal pain recurred and was almost continuous; she went to the Soho Hospital for Women and became an in-patient, remaining there for ten days. After consultation and several examinations she was discharged, without any operative treatment.

On March 17th, 1897, a hæmorrhagic discharge, like menstruation, appeared and lasted from two to three days; during this time she suffered much abdominal pain. She felt movements, and thought she had quickened. About this period she applied to a doctor for advice, as her legs were much swollen; she was told she was pregnant and that her labour should take place in August.

In April (the exact date is uncertain) the patient had retention of urine necessitating the passage of the catheter; this only occurred once, but for the remainder of her pregnancy she had difficulty with micturition and could only pass urine with very much straining. The breasts were becoming larger and the abdomen was noticed to be increasing in size.

No further symptom arose beyond a gradual increase in size of the abdomen; but she was so very large that her friends remarked upon it. On August 5th there was a show of blood and mucus and labour pains began. Her medical man and two others who were called into

consultation by him, could find no cervix, but they waited with her the whole night. The pains gradually ceased, the breasts became full of milk, and a lochial discharge appeared lasting for some days. After that no further fœtal movements were felt, the breasts became gradually less in size and the abdomen smaller. She was in great abdominal pain for a month, and remained in bed. No evidence as to the temperature could be obtained.

In October the patient noticed that she was becoming smaller; the pains in the abdomen continued so severe that she was unable to leave her room, and stayed in bed most of the time. She saw three doctors at different intervals, and various opinions were expressed. In November the pain gradually became less and the abdomen still smaller; she remained, however, in her room. Twice she saw a hæmorrhagic discharge, lasting two or three days.

During the first three weeks of December she seemed much better and got out; on the 29th, however, she felt ill, complained of headache and fever, and retched several times; on the 30th she was found in great pain, the abdomen was very tender and distended, and there was constant retching. Blood and mucus were passed by the rectum, the pulse becoming smaller and more rapid and her general condition more grave.

December 31*st*, 1897, 1.15 *p.m.—Present condition:* Patient was lying in a crouched-up position on the right side, moaning with pain; on turning her into the dorsal decubitus, the knees (especially the left) are persistently drawn up; the face is drawn and pinched, the tongue brownish and dry; pulse 148, temp. 103° Fahr.

The breasts are flabby, and show no signs of activity; darkened areolæ.

Per hypogastrium.—The abdomen is much distended by a rounded swelling, reaching three fingers' breadth above the navel, the swelling being more marked towards the right than the left.

It is composed of two portions:

1. A central hard, rounded swelling, reaching four fingers' breadth above the brim of the pelvis, and which feels like an enlarged uterus; it distinctly hardens and softens at intervals.
2. An ill-defined rounded swelling before mentioned; tympanitic all over, but giving a peculiar resistent sensation on palpation. Flanks resonant. No fœtal heart-sounds to be made out, but crackling sounds on auscultation.

Per vaginam.—Violet staining of the mucous membrane well marked, blood-red discharge going on, but no clots or shreds. The cervix uteri is felt pushed upwards and forwards and flattened out somewhat behind the symphysis pubis; the os uteri externum is patulous and transverse (bilaterally lacerated), and admitting the index finger easily up to the internal os uteri; the sound passes forward directly into the swelling in the lower hypogastrium three and a half to four inches; free hæmorrhage occurred on its withdrawal. The left and posterior portion of the pelvis is occupied by a fixed semi-elastic swelling containing some slightly mobile body.

Rectal examination indicated a mass like a fœtal foot low down in the pelvis.

1.30 *noon.*—Anæsthetic given; a more complete examination was made. The large abdominal tumour was clearly defined, but resonance was elicited on percussion all over its surface.

The diagnosis was made of a full-term child, extra-uterine, dead about four months and putrid.

Operation, 1.45 *p.m.*—The skin of the abdomen was prepared in the usual way, and after discussion it was thought advisable to make a small abdominal opening before deciding whether to operate by vagina or abdomen. A small opening was therefore made midway between the upper edge of the lower swelling and the navel. On cutting into the peritoneal cavity some (ascitic?) fluid

escaped with yellowish flakes. Intestine was seen adherent to a pinkish-walled mass, and on passing a fine trocar into this a large amount of somewhat offensive gas escaped.

The incision was enlarged upwards and downwards. The lower swelling was then found to be uterus and of a deep red colour, with its anterior surface looking somewhat to the left as well as forwards. Its posterior and lower two thirds surface was attached intimately to the large cyst already mentioned. The tubes and broad ligaments on both sides were quite healthy, and showed no signs of scar tissue or recent rupture.

The tumour at the back of the uterus was found to reach above the level of the navel, and on puncturing it (as already stated) fœtid air escaped. On exploring with the finger external to the capsule upwards and laterally many recent adhesions were found, and were undisturbed. The large intestine (ascending and part of transverse colon) was found incorporated in the wall of the sac for from six to eight inches. The abdominal wound having been carefully packed all round with gauze, the patient was turned on her right side and an incision made into the sac, which was pink in colour with an irregular glistening surface. Fœtid yellowish-green material escaped to the amount of about two pints; as much as possible was washed out and the finger inserted into the cavity. An arm and hand (left) came through the opening, and it was then found that the fœtus was lying obliquely across the mother's abdomen, its head under the edge of the ribs on the right side, and the breech in the left iliac fossa, the feet lying in Douglas's pouch. The child's right side was towards the maternal vertebral column. Delivery could not be effected by traction, and I therefore amputated the head with large scissors and extracted the body; delivery was then quite easy.

The placenta was found attached to the left and fundal portion of the sac, the incision into the latter just missing

its edge. The membranes were adherent all over the sac, especially in the left iliac fossa where the breech lay. These were peeled off and the placenta removed; slight venous oozing occurred, but no hæmorrhage sufficient to require interference.

The sac was irrigated with 1 in 4000 solution, and the sac walls sutured to the peritoneum. A glass tube was placed in the peritoneal cavity above the upper border of the sac, and into the latter a long strip of pink gauze reaching to the bottom.

The duration of the operation was one hour and twenty minutes. The condition of the patient was perhaps more satisfactory than before interference commenced.

Description of the fœtus.—A full-time, well-nourished child, twenty inches long, and weighing eight pounds. The skin covering the abdomen was decomposed, and patches of gangrene were present on the foot and buttocks; elsewhere the skin was white but somewhat sodden. There was no deformity present. The skull was soft, with a biparietal diameter of four inches. The brain was diffluent.

The *placenta*, flattened, almost circular, eight inches in diameter, was of yellowish-brown colour, and smelling very putrid, and no microscopical examination could be made. The cord was central and twenty inches in length, also putrid. The placenta was shown at a meeting of the Obstetrical Society held on January 5th, 1898 (*vide* vol. xl, p. 3).

Treatment consisted in free administration of nourishment, first in the form of nutrient enemata and later by the mouth, and by the frequent washing out of the putrid sac with an antiseptic lotion (boracic acid).

Subsequent progress. January 7th, 1898.—The lochia ceased to-day; the sac has contracted, and the discharge is no longer offensive. The uterus is apparently mobile and smaller. Much *débris* has been washed out of the sac night and morning.

February 10th, 1898.—Considerable difficulty in keep-

ing the bowels open. Directly constipation ensues she has a rise of temperature, sweats, and a shiver. This has occurred three times since the operation, the temperature rising to 103·5° F. during the last attack. Each attack has lasted for from one to three days, and rapid improvement has taken place as soon as the bowels have been freely open. The condition of the wound normal; it is syringed out daily and packed to the bottom with gauze. The sinus is four and a half inches long, and just admits the nozzle of an ordinary glass syringe.

I have seen her three times since, the last occasion being on January 15th, 1900. I then found she was in perfect health, menstruating regularly and normally, and much fatter than before her illness. No difficulty with the bowels.

The abdominal scar on examination proved quite sound; vaginal exploration showed a normally situated and mobile uterus, and nothing remaining of the fœtal sac.

Remarks.—The history of this case seems fairly typical; she must have menstruated early in November, and the rupture have taken place on December 14th. She had no previous history of pelvic inflammation, but for nine years had remained sterile although living with her husband throughout. This factor is often insisted upon as predisposing to the production of a tubal gestation.

At the operation both tubes were found to be quite normal, and presented no signs of cicatrices; this is important as showing either that all signs of rupture may disappear before four to five months after the death of the fœtus, or that in this case the fœtus may have been expelled through the abdominal ostium. From the position and arrangement of the facts found at the operation the case was evidently one of intra-peritoneal rupture. At no time during the illness were any portions of decidua passed. I was not surprised at finding the placenta could so easily be removed and without hæmorrhage, as Dr. Cullingworth reported a case ('Obstet. Trans.,' vol. xxxv, p. 155) in which abdominal section was performed

four weeks after the presumed death of a fœtus of eight months' growth, and there was also no difficulty experienced. He says (p. 160), "Notwithstanding that the placenta was of large size, and that the operation was undertaken at the comparatively early period of four weeks after the cessation of fœtal movements, the circulation in the placenta had ceased, and the process of separation was carried out easily and without any hæmorrhage." If abdominal section is performed and an attempt made to remove the placenta during the life of the child the placenta is best left *in situ*, or alarming hæmorrhage may occur. Cases recorded by Sir John Williams and Dr. Champneys ('Obstet. Trans.,' vol. xxix, pp. 456 and 482) are instances of the rectitude of this line of treatment.

In 1893 I read a case very similar in character to the one at present under discussion ('Obstet. Trans.,' vol. xxxv, p. 162), but in which the term of pregnancy was six months, and the operation performed two and a half months after the spurious labour.

I have fully recorded this case, as I believe this variety to be rare, and by so doing I trust to elicit recital of other cases throwing further light on the behaviour of the tubes under this pathological condition.

The PRESIDENT considered that the theories on abdominal pregnancy remained unsettled. Tait and Bland Sutton held that it was a tertiary condition resulting from the rupture of a broad ligament fœtal sac, itself a secondary result of rupture of a tubal sac. But Bland Sutton also believed in the escape of an ovum out of the ostium of the tube, leaving no trace of gestation in the tube; the ovum might then survive and develop in the peritoneal cavity. J. W. Taylor held that abdominal pregnancy was due to rupture of a tubal sac, probably at a point where there was no placental tissue likely to bleed, the ovum surviving after escaping into the peritoneum. The President's case would shortly be published; the pregnancy was of the posterior ligamentary type, and the fœtus putrid from infection from the rectum. The patient did well for six weeks, then sank slowly from marasmus rather than obstruction,

dying in the ninth week. He asked Dr. Phillips whence the putrid infection was derived in his case.

Dr. Cullingworth said that one of the most interesting points in the case was the normal condition of both Fallopian tubes. Mr. Bland Sutton had called attention to the analogy between the behaviour of the Fallopian tube after having expelled an ovum and that of the uterus under similar circumstances, and he (the speaker) had been able to corroborate Mr. Sutton's observations by exhibiting to the Society a Fallopian tube that, within ten hours of the occurrence of rupture and extrusion of an early ovum, had entirely resumed its normal size and appearance. Indeed, had it not been for the rent in its wall and the identification under the microscope of chorionic villi in the fragment of clot adherent to the edges of the wound, it would have been impossible to recognise it as having recently contained an ovum. He thought that the author's theory was probably correct, namely, that there had been a complete tubal abortion, and that the ovum had preserved its vitality after being extruded into the abdominal cavity, and had continued to develop there. In that case the sac containing the fœtus would, he presumed, consist entirely of the fœtal membranes. He would be glad to hear if any portion of the sac had been examined. He would also be glad to hear details as to the site of implantation of the placenta. It had been stated that the placenta always retained its connection, wholly or partially, with its original site within the tube. This case seemed to show that there were at least exceptions to that rule.

Dr. John Phillips, in reply, said that a piece of the sac wall had been excised, and microscopical examination had showed it to consist of fibrous tissue; the colon was incorporated in its walls, and hence the putrefactive changes which took place.

APRIL 4TH, 1900.

ALBAN DORAN, F.R.C.S., President, in the Chair.

Present—38 Fellows and 2 visitors.

Books were presented by the St. Thomas's Hospital Staff, the Boston (U.S.) Lying-in Hospital Staff, La Société d'Obstétrique de Paris, and Dr. Macnaughton Jones.

William Warburton Wingate, M.B., B.C.Cantab. (Cambridge), was declared admitted.

The following gentlemen were elected Fellows of the Society:—William Francis Victor Bonney, M.D., M.S., F.R.C.S.Eng., and Henry Heath Pochin Johnson, L.R.C.P.

The following letters were received from Sir William O. Priestley and Dr. James R. Chadwick on their election as Honorary Fellows of the Society.

17, HERTFORD STREET,
MAYFAIR, W.;
February 13th, 1900.

MY DEAR DR. PHILLIPS,

I am very proud and very grateful to the Obstetrical Society of London for the high honour it has conferred upon me. Will you be the means of conveying my thanks to the President, Council, and Fellows of the Society for this mark of their regard for me, and of their sympathy with me in my severe illness?

Believe me,

Yours sincerely,

WILLIAM O. PRIESTLEY.

270, Clarendon Street,
Boston, Mass., U.S.A.
March 2nd, 1900.

My dear Sir,

Your letter informing me of my election to be an Honorary Fellow of the Obstetrical Society of London has just been received. I hasten to express to you my recognition of the high honour done me thereby, the highest which could come to one whose life has been devoted to the study and practice of that branch of medicine which your Society fosters.

It may interest you to know that, as the (admitted) founder of the American Gynecological Society twenty-five years ago, I drew its constitution after that of your Society, and based my hopes for the future success and usefulness of our Society on the manifest achievements of the London Society.

I beg you will transmit to the Council and Fellows of your Society my heartfelt thanks for this unexpected courtesy.

I am, very faithfully,
James R. Chadwick, M.D.

Dr. John Phillips,
Secretary of the Obstetrical Society of London.

INCARCERATED FIBRO-MYOMA OF UTERUS IN AN UNUSUALLY YOUNG SUBJECT.

Shown by C. J. Cullingworth.

The specimen consisted of an interstitial fibro-myoma, 5 × 5¼ inches, developed in the fundus of a retroflexed uterus, and consequently lying for the most part in the pelvis. Once the patient had had retention of urine, but her main symptom was irregular uterine hæmorrhage. The interest of the case lay in the patient's age. Dr. Spencer's paper in the Society's 'Transactions' for 1898

showed that fibro-myoma of the uterus is rare in patients under twenty-five. He had only been able to collect forty well-authenticated instances. The patient from whom the specimen before them had been removed afforded another example, for she was only twenty-three. This circumstance (of the patient's exceptional youth) had influenced the diagnosis, which was to the effect that the tumour was solid, and that though it might either be a solid tumour of the ovary or a fibro-myoma of the uterus, the former was the more likely. As if for the very purpose of throwing one off the scent the cervix was put on the stretch, and elongated to such an extent that its canal measured exactly two and a half inches. It was therefore thought that the entire uterus lay in front of the mass, and that the mass was in all probability a solid tumour of the left ovary.

When the tumour was lifted out of the pelvis, what had been the lowest and most dependent part became the uppermost. An attempt was made to treat the case by myomectomy, *i. e.* without removing the uterus itself, but this was found to be impracticable. The operation of abdominal hysterectomy was performed on February 20th. The patient had done well.

PEDUNCULATED SUBSEROUS FIBRO-MYOMA OF UTERUS WHICH HAD UNDERGONE MYXOMATOUS AND CYSTIC DEGENERATION.

Shown by Dr. Stabb.

Dr. Stabb showed a pedunculated subserous fibromyoma of uterus which had undergone myxomatous and cystic degeneration. The chief interest attaching to the tumour, however, was the doubt as to whether it was also sarcomatous. The growth was removed from a single woman aged thirty-eight, with a history of only two and

a half months' enlargement of abdomen, her last menstrual period being accompanied by pain over the tumour; no menorrhagia. At the operation several recent adhesions were found, and one more dense to mesentery, which required ligature before division: there was no hydroperitoneum. The surface of the tumour was irregular, and studded with small elevations the size of split peas, and on section there was one large cyst found containing upwards of a pint of mucoid fluid, and several smaller cavities. Microscopic sections, prepared by Dr. Rolleston, showed areas of rapid proliferation with numerous young connective-tissue cells approaching in type those of a spindle-celled sarcoma. It was this microscopic appearance of the growth, and the difficulty of its true interpretation, which was the reason Dr. Stabb brought the specimen before the Society.

The PRESIDENT found that simple mucoid degeneration of a uterine myoma often presented the most suspicious appearances under the microscope. The opinion of an experienced general pathologist was advisable for purposes of prognosis.

The specimen was referred to a sub-committee consisting of Drs. Robinson, Eden, William Duncan, and Stabb, for further examination and report.

TUBAL MOLE; FŒTUS THREE QUARTERS OF AN INCH IN LENGTH, IN PERFECT PRESERVATION.

By ALBAN DORAN, F.R.C.S.

(With Plate XII.)

C. G—, aged 24, consulted my colleague, Mr. Butler-Smythe, on November 28th, 1899, for violent hypogastric pains.

She had been married six years, and had borne two

children; the youngest was over three and a half years in age (born March, 1896): no miscarriages. Her health had been uniformly good; indeed, she had never been laid up except at her confinements. The catamenia appeared at intervals of from four to five weeks; the show was never free. They had ceased for fourteen weeks; and seven weeks after the last period severe hypogastric pains set in, accompanied by a free show of dark blood nearly every other day. The breasts grew larger. A clot was expelled on November 27th—the day before she consulted Mr. Butler-Smythe, who detected a mass in the pelvis to the left of the uterus, and, on the strength of the clinical evidence, diagnosed tubal pregnancy, and sent her into my wards at the Samaritan Hospital.

The patient was well nourished but anæmic. On bimanual palpation a body of the size of an orange could be felt behind and to the left of the uterus. It was not freely moveable; the uterus was a little enlarged, the fundus rising above the pubes; its axis was normal.

The breasts were small, the glandular substance rather firm. The areolæ were well marked (the patient was black-haired), the follicles distinctly enlarged, the nipples prominent.

On November 29th, the day after admission, a severe attack of hypogastric pain set in, with continuous escape of dark blood. A big clot passed during defæcation. The evening temperature on the preceding day was 99·4°, on the morning of the 29th 98·2°, in the evening 99·4°. Next day, and until the operation, it remained under 98·4° morning and evening.

I operated on December 2nd with the assistance of Mr. Butler-Smythe. Ether was administered by Dr. Probyn-Williams. The patient was placed in the Trendelenburg position. There was no free blood in the peritoneal cavity. The uterus, enlarged and soft, lay rather high; the left tube and ovary, perfectly normal, lay still higher. They were pushed up by the dilated

right tube, which had fallen behind the uterus and developed towards the left side. I raised the tube; a few drachms of tea-coloured blood spurted out of the ostium, and there were some soft adhesions to Douglas's pouch. The corresponding ovary was normal. There was a short pedicle, easily secured. No drainage was necessary. The abdominal wound was closed with deep interrupted silkworm-gut sutures, and the sheath of the recti with continuous No. 1 silk.

I noticed, when dividing the tube near the right cornu of the uterus, that there was no blood or mucus in its canal, which was not much dilated at this point; nor did any run, after removal, out of the cut end from the blood in the dilated portion. I also noted that there had been free show of blood on the morning of operation, and that it came on again a few hours after the tube had been removed, and continued for four days. The patient made a speedy recovery.

Description of the tubal mole.—The tube measured three and a half inches by two inches. It was sent to the Royal College of Surgeons, and after being carefully hardened in spirit was divided vertically. Mr. Shattock then placed it in glycérine and afterwards in formalin. It has been prepared, in fact, so as to make a most instructive specimen, added to the museum.*

The greater part of the tube is dilated in the usual fashion, the uterine third remaining almost undilated, whilst the outer and affected portion is bent under it at a sharp angle, passing below the ovary. On section a thick lining of clot is seen adherent to the walls of the dilated portion. This clot surrounds a large ovoid cavity, deepest in vertical measurement at the uterine end; near that end it contains a well-formed fœtus three quarters of an inch long, with a straight but irregularly bulbous umbilical cord half an inch long. The lining of the cavity is perfectly smooth. The layer of clot which bounds it is of irregular thickness, being three quarters of an inch

* Pathol. ser., No. 4695 L.

DESCRIPTION OF PLATE XII.

Illustrating Mr. Alban Doran's specimen of Tubal Mole.

The plate (life size, from a photograph) shows fœtus three-quarters of an inch in length. Below is seen the cut surface of the ovary, and more to the left the canal of the Fallopian tube cut across, near the uterus, at the operation.

The parts are inverted; the mole lay in Douglas's pouch under the ovary.

Illustrating Mr. Alban Doran's Specimen of Tubal Mole.

Bale, Sons and Danielsson, Ltd.

thick at the outer end of the tube, whilst just above and below the fœtus it is under an eighth of an inch thick. The ovary contains no corpus luteum of recent date.

This case is chiefly remarkable for the appearances seen on making a section through the tube; they show the nature of the abnormal gestation as clearly as though the section were an artificial diagram. The fœtus was in perfect preservation, and was luckily so placed that the knife, in making the usual longitudinal section of the tube, did not mutilate it or tear it from its attachments. The fœtus remains in the tube, so there has been no tubal abortion. The amnion is perfect; had it been torn by the hæmorrhage the fœtus would most probably have been destroyed. The clot which forms a thick wall lies between the amnion and chorion.

The blood which escaped from the vagina was probably uterine from first to last. The uterine end of the tube showed no sign of fluid or clotted blood, and was quite cut off from the mole. There had been bleeding a few hours before operation, and it recurred a few hours afterwards when no sac or tube was left to bleed from: the remaining tube was quite healthy.

The clinical history was so clear as to serve for educational purposes, but it was free from any interesting or puzzling anomaly. I must note, however, that there was no evidence of old or recent disease of the appendages. There was some interval of time between this and the previous pregnancy, as is so frequent in ectopic gestation. The show of dark blood with hypogastric pain is characteristic.

Von Strauch declares that these crampy pains are due to actual contraction of the tube.* He describes a case where a woman had two characteristic fainting fits after two months' amenorrhœa. On operating he found an ovum half extruded from the ostium. This ovum was held by a broad pedicle (placental) to the tube high up

* 'Centralblatt f. Gynäkologie,' 1899, p. 1294.

the canal. Outside the tube was a deep depression corresponding to the attachment of the pedicle. This depression, von Strauch contends, could only have been produced by contraction of the tube to expel its contents. Intra-tubal hæmorrhage or mechanical dragging could not have made a depression of this kind. This evidence is reasonable, though perhaps not conclusive. But von Strauch declares that in another case he could feel tubal contractions through the parietes during labour-like pains which occurred daily for several months after rupture of the tube in the fifth month. At length he operated and removed a mummified fœtus encapsuled in omentum. The placenta lay in the tube, which was very thick-walled; the ostium was dilated widely enough to admit a finger. About von Strauch's opinion on this case we must demur, yet the possibility of detecting tubal contractions at the second or third month may be reasonably entertained.

The sac in my case, though developed in the right tube, lay to the left as well as behind the uterus, which was pushed up, together with the left tube and ovary. On this point Taylor and others have dwelt, but I have often observed the same peculiarity in cases of unilateral hydrosalpinx, and even when a small, heavy ovarian tumour lies in the pelvic cavity.

A distinct rise of temperature, evidently corresponding to hæmorrhage, has been noted by Routier in a case where there was a pelvic tumour.* The rise occurred twice in six days, and on each occasion the tumour distinctly increased. He suspected a suppurating hæmatocele, but on operating he found a ruptured five months' pregnancy. He relates cases of rise of temperature in hæmatothorax, and bleeding into joints where no septic germs could be found. In my own case, however, the hæmorrhage four days before operation, accompanied by a slight rise of temperature, was, it would appear, purely

* Routier, 'Bulletins et mém. de la Soc. de Chirurgie de Paris,' Nov. 14th, 1899.

uterine, though it might have been intra-tubal, between the chorion and the amnion.

Dr. Cullingworth thought the statement as to tubal contractions having been felt bimanually must be accepted for the present with reserve. The possibility must be borne in mind of the spasmodic pains complained of in these cases of ectopic gestation being due not to *tubal*, but to severe and therefore painful *uterine* contractions. In a case of advanced ectopic gestation with dead child, which he brought before the Society some years ago (see 'Trans.,' vol. xxxv for 1893, p. 156), the uterus was displaced forwards, and, being visible beneath the abdominal wall, could be seen as well as felt to undergo alternate contraction and relaxation. It was true the contractions in that case were not painful, but if contractions powerful enough to be visible to the bystanders through the abdominal wall took place when the child was dead and the uterus empty, it was not difficult to conceive of the possibility of the contractions being severe enough to be painful when the stimulus was greater, as when the ovum had recently undergone sudden enlargement from hæmorrhage, or when the decidua had not yet been expelled from the uterine cavity.

The President said, in reply to Dr. Cullingworth, that a few ounces of blood had escaped into the pelvis, the ostium being open. He agreed with those who doubted von Strauch's theory, and believed that the attacks of crampy pain in tubal gestation represented uterine, and not tubal contraction. He had shown that in the present case the later hæmorrhages at least, and therefore, no doubt, the crampy pains which accompanied them, were uterine.

A SOLID TUMOUR OF THE OVARY REMOVED FROM A WOMAN AGED THIRTY-SIX.

Shown by Dr. Addinsell.

Dr. Addinsell showed a solid tumour of the ovary removed from a woman aged 36. A "lump" had been noticed for eighteen months, with a sense of weight, but no pain, on the left side. There was no ascites. The menstrual rhythm was not disturbed. The tumour was freely moveable.

On removal it was found to measure 6½ inches in length, 4½ inches in width. The surface was uneven but smooth.

On microscopical section it proved to be a fibroma.

Dr. Addinsell pointed out the fact that different interpretations are placed upon the histological appearance. Thus some regarded this as a myoma, others a fibroma, whilst Mr. Bland Sutton was inclined to regard all these cases as sarcomata with varying degrees of malignancy. Before pronouncing in favour of malignancy the clinical aspects should always be carefully considered, such as the age, and especially the rapidity of growth, and these in conjunction with the histological appearances.

The PRESIDENT was still of opinion that, in the case of ovarian tumours, fibroma was oftener taken for sarcoma than sarcoma for fibroma. He had expressed this opinion in his paper on the subject read before the Society in 1896. The woman aged fifty-two when he operated in 1889, and the girl aged twenty-four when he operated in 1895, were both living. One feature of these cases was the smallness of the pedicle. He had never heard any explanation of the fact that in this kind of tumour the great hypertrophy of the tube and mesosalpinx, so common in the more familiar ovarian cyst, did not occur. This shortness of the pedicle sometimes proved troublesome to the operator.

OVARIAN CYSTOMA COMPLICATING PREGNANCY; INFECTION OF THE CYST FIVE DAYS AFTER LABOUR; OPERATION ON THE FORTY-THIRD DAY; EXTENSIVE PERITONEAL AND BOWEL ADHESIONS; RECOVERY.

Shown by Dr. MACNAUGHTON JONES.

THIS case is of sufficient clinical and operative interest to warrant my recording it. The patient was thirty-one

years of age, and had been nine years married. Previous to 1898 she had not conceived. Early in 1897 she noticed an increase in the size of the abdomen, and this continued until June of that year, after which time it remained stationary. She had neither pain nor discomfort of any kind, and the catamenia were regular. She conceived at the end of January, 1898, and on the 30th of October she was delivered of a healthy male child. Nothing was noticed during the pregnancy, save that the abdomen was unusually large, and she did not suffer much. On the evening of the third day after labour her temperature rose to 100°, and there was a corresponding increase in the pulse, which varied between 120 and 130. Early in the morning of the fourth day there was a rigor, followed by intense abdominal pain, and the temperature rose to 103·4°. On the fifth day the temperature rose in the evening to 105°, and fell the following morning to 100°, rising again in the evening to 102·2°. Vomiting now set in, and continued for some twenty-four hours. For the week following, the temperature range varied between 100° and 103°, the exacerbations being nightly; and during this time there was severe abdominal pain with considerable flatulence, the pulse varying between 100 and 120. On the eighteenth day after labour the temperature fell to 100°, and the pulse became normal. All through there was a considerable vaginal discharge.

The pyrexial range altered on the 1st of November, and again there was a period of hyperpyrexia.

On the 2nd she was admitted into the Stanmore Cottage Hospital, and was there treated until I saw her for the first time on the 9th of November. The evening temperature was then 103°, and the morning 100°. I decided, with Dr. Allen, that we were dealing with a suppurated ovarian cyst. The abdomen had recently rapidly increased in size; measurements taken from the trochanter to the umbilicus at the right side, and from corresponding points at the left, were respectively nineteen and twenty-five inches.

I operated on the morning of the 11th of November, every possible aseptic precaution having been taken both before and during the operation. On operating, after the usual incision, I found that the cyst wall was quite adherent to the parietal peritoneum. Having separated the adhesions anteriorly and at either side, the cyst was tapped with a Wells' trocar, and an enormous quantity of pus was evacuated. The abdominal wound and surrounding parts were protected with sterilised cloths. When the cyst was emptied it was found to be adherent all round to the intestine, which was matted on it in coils, and also deeply in the pelvis, especially at the left side to the sigmoid, where it had its short and broad pedicle. A large portion of omentum was attached to the cyst.

So great were the adhesions that I confess that at first I almost despaired of being able to remove it in its entirety without irreparable damage to the bowel, and possibly most dangerous hæmorrhage. However, gradually freeing portion by portion, and using forcipressure and ligature for control of hæmorrhage, I isolated the cyst, being compelled to cut away a portion of the omentum, which was so firmly adherent that I could not detach it from the wall. When the cyst was removed, not the least troublesome part of the operation remained from oozing of the omental and intestinal vessels. However, all these were finally secured with fine silk ligatures or by forcipressure, the abdominal cavity was carefully dried, and the abdominal toilet completed with the insertion of a drainage-tube.

The operation was necessarily a prolonged and difficult one. The pus was inodorous. There is not much to record after the operation.

On the third day the temperature had fallen to normal, and though it rose again slightly for some days there was nothing unusual in the convalescence, and the patient left the hospital at the end of January perfectly recovered.

Though of course suppuration of ovarian cystoma is

not very uncommon, its coincidence as a post-partum complication is, and I am not aware of a similar case being on record.

I am indebted to Dr. Hamilton Allen for the abstract of the notes of the case previous to my seeing her.

Dr. Herbert Spencer was surprised to hear that these cases were uncommon. He regarded labour as one of the commonest causes of suppuration in ovarian cysts. The cause was not always easy to ascertain—whether infection from tears in the genital tract or from the intestine when the vitality had been lowered by injury or by twisting of the pedicle. He had removed five ovarian tumours which suppurated after labour.

A CASE OF MYXO-SARCOMA OF THE VAGINA IN A CHILD AGED TWO AND A HALF YEARS.

Shown by Arnold W. W. Lea, M.D., B.S., F.R.C.S.

Dr. Lea related a case of primary sarcoma of the vagina, and showed masses of growth removed together with microscopic sections.

The clinical history was briefly as follows:

The patient, aged 2½, was first seen in March, 1899. For some months previously a watery, and at times hæmorrhagic discharge had been observed. Several polypi projected from the vulva. Around the vaginal entrance and the urethra were numerous masses of firm growth. A pyriform elastic tumour was felt in the abdomen, reaching the umbilicus.

Under anæsthesia the vagina was found to be enormously dilated, reaching almost to the umbilicus. It was filled by polypoid masses of soft growth, many being pedunculated. A small firm body was felt at the summit of the abdominal swelling, which apparently was the uterus. The recto-vaginal septum and the wall of the

bladder were involved in the growth ; complete removal was impossible. Masses of the growth were curetted away at intervals with temporary relief.

The patient became gradually weaker, and died January, 1900, thirteen months after the tumour was first observed. No autopsy was obtained.

Microscopic examination : the polypoid growths are seen to be covered completely with stratified epithelium ; beneath this is myxomatous tissue with masses of round cells, evidently a myxo-sarcoma. The growths around the vaginal orifice are much smaller and firmer. They present a similar structure, but contain a considerable amount of fibrous tissue. Numerous large thin-walled vessels are present. There was no evidence of ulceration at any time.

The case is a typical one of this rare type of sarcoma occurring in children. Few instances have been recorded in this country. Mr. D'Arcy Power described a case some years ago in the 'St. Bartholomew's Hospital Reports' (1895). In his paper he gives a brief summary of twenty-four other cases collected from various sources. The cases are characterised by the formation of numerous polypoidal outgrowths resembling clusters of grapes, which arise from the walls of the dilated vaginal canal. The malignancy is usually local only, although sometimes the inguinal glands become enlarged.

The treatment of these cases is very unsatisfactory. They have usually come under observation when too advanced for a radical operation, such as extirpation of the vagina. Repeated curettings give temporary relief, but most cases are fatal in one to two years after the onset of symptoms.

Dr. Charles Morris said he had a case recently of primary sarcoma of the vagina in an adult, and on looking up the subject he found that many cases were reported of myxomatous papillomata being present at the orifice of the vagina and primary sarcoma in the deeper parts. This condition, however, was only found in children, the myxomatous growths being absent in

adults. A most interesting paper on the subject was published by Mr. D'Arcy Power in the 'St. Bartholomew's Hospital Reports.'

Dr. Roberts referred to a very similar specimen in St. Bartholomew's Hospital Museum (3030 A) which occurred in a child of two years and four months, in which numerous polypoid growths protruded from the vagina very similar to those Dr. Lea now showed. They bled easily and were very œdematous. At the necropsy a large mass of growth was found between the rectum and the bladder, and the whole anterior and posterior vaginal walls were covered with numerous polypoid masses. The tumour was a typical mixed-celled sarcoma. The specimen is figured and described in the 'Trans. Path. Soc.,' 1896, vol. xlvii, by Mr. D'Arcy Power. Dr. Roberts thought that if the disease occurred in children, polypoid growths protruding from the vulva were the chief features of the case, the prognosis was hopeless.

THREE CASES OF INCARCERATION OF THE RETRO-DISPLACED GRAVID UTERUS AND ONE OF EXTRA-UTERINE PREGNANCY SIMULATING THAT CONDITION.

By J. M. Munro Kerr, M.B., C.M., F.F.P.S.G.,

ASSISTANT TO THE CHAIR OF MIDWIFERY, GLASGOW UNIVERSITY; ASSISTANT PHYSICIAN, MATERNITY HOSPITAL; DISPENSARY PHYSICIAN FOR DISEASES OF WOMEN, WESTERN INFIRMARY, GLASGOW.

(Received March 17th, 1900.)

(*Abstract.*)

It is pointed out that three varieties of backward displacement of the gravid uterus may be met with, viz. "retroflexion," "retroversion," and "partial or incomplete retroversion," and that each form is illustrated by one of the cases.

Case 1.—An incarcerated, retroflexed, gravid uterus, which after several fruitless attempts at replacement righted itself. This occurrence is pointed out to be not very uncommon.

Case 2.—This case was reported in full by Prof. Murdoch Cameron, in the 'British Medical Journal,' October 31st, 1896. It was one of incarceration of the retroverted gravid uterus, in which the uterus could not be replaced until Prof. Cameron opened the abdomen, then performed cystotomy and emptied the bladder of a large quantity of blood-clot. He then stitched up the bladder and abdomen. The pregnancy continued to full time. The treatment adopted in this case is briefly discussed.

Case 3.—Partial retroversion (sacculation) of the gravid uterus caused by a myoma in anterior wall. Reduction of the

displacement; continuance of pregnancy. The causes of this form of retro-displacement are described.

Case 4.—Extra-uterine pregnancy simulating and mistaken for a retroflexed gravid uterus. Some reported cases are referred to, and the differential diagnosis of the two conditions is discussed.

The following three cases of incarceration of the retro-displaced gravid uterus and a case of extra-uterine pregnancy, which presented all the symptoms of a retro-displacement, and was at first mistaken for the latter, have appeared of sufficient interest to warrant me in bringing them under the notice of this Society.

I propose with each case to give a brief outline of the conditions present, and to add a few remarks on the more important points connected with it.

The term "retro-displacement" has been used. It is the most comprehensive, as it includes the three distinct forms, "retroflexion," "retroversion," and "partial or incomplete retroversion." In this I am fortunate that each of the three cases brought forward to-night is an example of one of these varieties.

Case 1. *Incarcerated retroflexed gravid uterus, which after several fruitless attempts at replacement righted itself.*—H. H—, iii-para, aged 31, was admitted to Ward 7, Western Infirmary, in August, 1894. Professor Murdoch Cameron being from home, I was summoned to see her. She stated she was about four months pregnant. She complained of great pain in the abdomen and difficulty of micturition, with an almost constant dribbling of urine of about four weeks' duration. Her first pregnancy was normal in every respect, but her last, in 1887, terminated in a miscarriage at the third month. She last menstruated on April 28th, just about four months before her admission to hospital. The symptoms of dysuria, etc., came on, therefore, at the end of the third month of pregnancy.

On examination the abdomen was much distended and tender to pressure. The bladder being emptied (sixty ounces of urine were drawn off) the distension and tenderness of the abdomen disappeared. On bimanual examination the cervix was found raised and pressed against the symphysis pubis with the body very much enlarged in Douglas's pouch.

The diagnosis of retroflexion of the gravid uterus made by her medical attendant prior to admission was confirmed. Attempts were made to replace the organ but failed, even when she was placed in the genu-pectoral position. The distended organ could be pushed up to a certain extent, but it always sank back again. I therefore advised the house surgeon, Dr. Webster, to keep the bladder empty by passing the catheter every few hours, to see that the bowels were thoroughly emptied, and to prepare the patient for chloroform for the following day, when further attempts would be made to rectify the displacement. The woman was told to lie well round on her face, and to sometimes assume the genu-pectoral position.

After my attempts at replacement she expressed herself as feeling much relieved, and she was able to pass urine quite freely, so that the catheter was not used.

On examining on the following morning, prior to giving her chloroform, great was my surprise to find the uterus in normal position. She was dismissed a few days later feeling perfectly well.

In all respects this case presented the usual features of a backward, displaced, incarcerated gravid uterus. The displacement was a retroflexion, the most common variety. The bimanual examination made this clear, and the onset of the dysuria occurred at the time, the end of the third month, when one usually finds it making itself felt.

The only point of special interest was that after several unsuccessful attempts at bringing about replacement, the organ should right itself. A similar occurrence has been frequently observed, however. We had an example of it

some years ago in the Western Infirmary, when the late Professor Leishman had charge of the Gynæcological Ward. A woman was sent up from the out-patient department after several attempts had been made to replace a similarly displaced gravid uterus. On the following day when Professor Leishman, prior to making further attempts at replacement examined the patient, he found the uterus in its normal position.

Case 2. *Incarcerated retroverted gravid uterus; abdominal section; cystotomy and replacement of uterus; recovery, and continuance of pregnancy to full time.*— This unique case was fully described by Professor Murdoch Cameron at the Annual Meeting of the British Medical Association in July, 1896. The full details regarding it will be found in the 'British Medical Journal,' October 31st, 1896. Briefly told the case was as follows:

Mrs. M—, five-para, aged 35, when eighteen weeks pregnant was seen by Professor Cameron in consultation with her medical attendant, on December, 12th, 1895, and was afterwards conveyed to the Western Infirmary to be under his care. The pregnancy presented nothing abnormal until the beginning of the fourteenth week, when a difficulty in passing urine began to be experienced. This continued for three weeks before the catheter was passed. When this was done for the first time, on December 3rd, eighty ounces of urine were withdrawn. On the following day the distension was as great as ever, and again a large amount of urine was removed. Mixed with the urine, however, there was a large quantity of blood. This hæmaturia continued until her admission to hospital. When admitted to Ward VII it was found that the abdomen was greatly distended by a doughy swelling. *Per vaginam* the os could only be reached with the patient under chloroform, and was found situated above the symphysis pubis; the posterior lip seemed continuous with the large bulky mass com-

pletely filling and firmly impacted in the pouch of Douglas. The patient's condition being so critical Professor Cameron performed abdominal section on the following day. Previous to the operation the bladder was repeatedly washed out. Numerous blood-clots, shreds of mucus, etc., came away in the washings, and once a narrow cast fourteen inches long of the thickness of a quill pen.

After cutting through the abdominal parietes the bladder was opened and emptied of its blood-clots, when the organ contracted like a puerperal uterus. The retroverted uterus was then with difficulty replaced by Prof. Cameron pulling it up from above while I pushed from below. The bladder wound was then stitched with silk and the abdominal wound closed with silkworm gut.

The woman made an uninterrupted recovery. She was delivered with forceps at full time of a large healthy male child.

This case, it need hardly be said, is of most peculiar interest and value. Many points might be referred to, such as the long continuance of the dysuria prior to a diagnosis being made, the enormous distension of the bladder, the occurrence of free hæmorrhage into its cavity after catheterisation, and the expulsion from it of a blood-cast, presumably of the ureter, etc.

All these, however, sink into insignificance compared with the brilliancy of the conception and execution of the operation adopted by Prof. Cameron.

Until quite recently the only treatment for irreducible cases of retro-displacement was to empty the uterus through the cervix, or, if that was impossible, to puncture the fundus, as Hunter taught; or to incise and empty it from the vagina, as Sänger suggested ('Centralblatt für Gyn.' 1894, p. 174); or to extirpate the organ, as suggested and carried out by Olshausen and others. Laparatomy for this condition was, of course, suggested years ago. Burns, for example, in the tenth edition of his text-book, published in 1843, says, p. 298 :—"It has also been asked

whether it would not be allowable to make an incision into the abdomen and pull up the uterus. The section of the symphysis has also been proposed."

As far as can be gathered, however, Cameron in this case, in 1896, and Jacobs in the 'Journal d'Accouchements,' April 10th, 1898 (reference to this paper will be found in the Epitome, 'Brit. Med. Journ.,' June 4th, 1898), are the two who have brought the operation within the range of practical obstetrics. Others, especially Mann, in America, have since written on the subject. Jacobs, in the paper mentioned, informs us that he has performed the operation eleven times. In ten of the cases pregnancy continued to full time, and once abortion followed the operation.

Case 3. *Partial retroversion (sacculation) of the gravid uterus with myoma of the anterior wall.*—Mrs. M—, aged 25, was admitted to Ward VII on December 19th, 1899. She complained of a "bearing down" pain in the abdomen of two days' duration. Menstruation, which began at the age of fifteen, had always been regular. Her last period occurred four months ago, just a week prior to her marriage.

The breasts were full, and some secretion could be expressed from them. There had been morning sickness for some weeks. On examination the abdomen was found distended to the extent of a six months' pregnancy by a tumour, hard in consistency, and rather fuller on the right than the left side. No fœtal heart-sound could be heard. The tumour was only very slightly moveable.

On the day following admission the case was examined by Prof. Cameron, myself, and others. On making a bimanual examination the cervix was felt displaced upwards and towards the symphysis pubis by a firm elastic tumour, which projected down into the pouch of Douglas. The tumour was continuous with the one above the brim of the pelvis. A distinct depression could be felt between the cervix and the swelling projecting into the pelvis,

although the posterior lip of the cervix seemed to be continuous with the lowermost wall of the tumour.

The question arose whether the case was one of myomata complicating pregnancy, or a "partial" retroversion of the gravid uterus. Under chloroform the diagnosis became clear, and the sacculated projecting portion of the uterus was pushed up by Prof. Cameron. It was then found that there also existed a myoma of the anterior wall.

The patient was dismissed a few days later perfectly well. Prior to her dismissal I examined her and found the cervix normal in position and no trace of the sacculation of the posterior wall.

This case is of interest because it is an example of the rarest of all backward displacements of the gravid uterus, viz. the partial or incomplete variety. Probably the sacculated condition of the posterior wall was caused in this case by the myoma on the anterior wall not only preventing the anterior wall expanding, but also leading to a retroversion of the organ. This retroversion was also undoubtedly favoured by the rigidity of the abdominal parietes; the woman was a primipara.

Partial retro-displacement, it would appear, may result from a pregnancy occurring in a retroflexed or retroverted uterus, and where as the pregnancy advances the organ only partially rights itself. It may be caused also by the posterior wall of the uterus being fixed by adhesion in the pouch of Douglas, and the anterior wall becoming more and more distended. Lastly, it may result from the presence of tumours—an ovarian tumour, as in a case reported by Croom ('Edin. Med. Journ.,' vol. xl, p. 289), or a myoma, as in the case just described by myself, and in the case of Dührssen ('Centralblatt für Gynäkologie,' No. 51, 1889).

Case 4. *Extra-uterine pregnancy simulating a retroflexion of the gravid uterus.*—J. C—, aged 30, iii-para, was admitted to the Western Infirmary, March 11th, 1898, while I had charge of Ward VII in Prof. Cameron's

absence. The patient complained of pain in the right side, and difficulty of micturition and defæcation of four weeks' duration. She had had two children, the last eight years ago. Menstruation had always been regular since age of fifteen. Her last period was on November 12th. About four weeks prior to admission she began to have pain in the lower part of her abdomen. A week later she took to bed, where she remained until transferred to hospital. While confined to bed she had considerable difficulty in passing urine and very obstinate constipation.

On bimanual examination the cervix was found pressed against the symphysis pubis and *higher* than normal. This was caused by a large tumour filling up the pouch of Douglas and extending slightly above the brim. There seemed to be a certain amount of mobility in the tumour. On careful palpation the anterior wall of the uterus seemed to be continuous with the upper part of the tumour, and the posterior lip of the cervix with the lowermost part.

I had no hesitation in making the diagnosis of retroflexion of a gravid uterus, a diagnosis that the patient's medical attendant had made before sending her to hospital. Attempts at replacement under chloroform were made, but although the tumour could be raised it was impossible to get it completely above the promontory of the sacrum.

For some days after these manipulations there were bleeding and pain in the lower part of the abdomen. These symptoms, however, disappeared with rest and morphia suppositories. Some ten days later she was again carefully examined under chloroform, when I began to be doubtful about the correctness of the diagnosis. The condition of the parts was exactly the same as on her admission.

On the day following the second examination, Prof. Cameron having returned, we saw the case together, and he quite agreed that it had all the appearances of retroflexion of the gravid uterus. However, as the patient's condition was not very satisfactory, he advised passing

the sound, which was done. It passed into the organ about three inches in the normal direction. The case was therefore cleared up. The abdomen was opened, and a large sac of an extra-uterine pregnancy moulded to the posterior wall of the uterus removed. It was adherent to the surrounding parts, and was situated exactly in the middle line deep in the pouch of Douglas. The pregnancy had advanced to almost the fourth month to judge by the fœtus contained in the sac.

This case has been brought forward along with the others to illustrate an error in diagnosis that sometimes occurs, viz. the mistaking an extra-uterine pregnancy for a retro-displaced gravid uterus.

If search is made of the literature on the subject, many examples of this mistake will be found. Most of the text-books on midwifery mention it, and not a few monographs and communications to various societies exist on the subject. For example, in vol. xxxix of this Society's 'Transactions,' two cases will be found reported by Dr. Giles, and in the 'Edinburgh Obstetrical Transactions' there are two communications by Dr. Barbour, the last in vol. xix, p. 156.

As illustrating the danger of the mistake, I would mention the case reported by Van der Hæven, and briefly described in Epitome No. 318, 'Brit. Med. Journ.,' 1898, vol. i. The case was that of a primipara three months pregnant, where a diagnosis of retroversion of the gravid uterus was made. After the tumour in Douglas's pouch was apparently replaced, profound collapse came on, and a retro-uterine hæmatocele formed, evidently from rupture of a gravid tube.

Undoubtedly the diagnosis between the two conditions is often difficult. Indeed, judging by the reported cases the symptoms may be almost exactly similar. The fact, however, that with extra-uterine pregnancy one usually gets a history of irregular discharges of blood, that the retention of urine is seldom so complete, that the contour of the sac is less uniformly smooth, and that the cervix is

seldom so much displaced upwards, will usually clear up the diagnosis.

Barnes, in his 'Lectures on Obstetric Operations' (fourth edition), speaking of the subject at p. 276, lays special stress on the position of the cervix. He says:—"One general fact of great service in forming a diagnosis is this:—Almost all bodies which get into Douglas's pouch come from above, and so push the uterus not only forwards, but at the same time downwards, thus bringing the os uteri within easy reach and pointing downwards. On the other hand, retroversions of the uterus lift the os upwards and tend to throw it forwards." Theoretically that may be correct, but in practice it is not always so, as witness Barbour's case, where the cervix was "above reach," and the case I have reported, where it was distinctly higher than usual.

The irregular discharges of blood so helpful in the differential diagnosis, as pointed out by Barbour, are not always present, as in my case they occurred only after manipulative attempts at replacement. Undoubtedly the point that is of the greatest importance in the diagnosis of obscure cases is that with extra-uterine pregnancy the retention of urine is never so complete as with a retro-displacement.

In conclusion, I desire to express my thanks to Prof. Cameron for so kindly placing at my disposal the cases I have described.

The PRESIDENT once examined a case where the cervix lay to the right and a soft elastic mass filled Douglas's pouch and the left fornix. He at first suspected extra-uterine pregnancy, but kept the patient at rest for a day or two instead of opening the abdomen. Then he found that the pelvic mass had risen into the abdominal cavity. Delivery afterwards occurred at term. When exploring a doubtful case of this kind under anæsthetics the surgeon is naturally careful lest he should burst a gravid tube after taking it for a reducible displaced uterus. The President referred to Unterberger's case ('Monatsschr. f. Geb. u. Gyn.,' March, 1900) where a gravid uterus, displaced by a bad

fall in the first month, obstructed the bladder, which became distended and forced open the urachus. The urine then passed entirely through the umbilicus. Rupture of an ovarian cyst through the umbilicus was diagnosed, but Unterberger emptied the suspected cyst by passing the catheter first through the umbilicus and then through the urethra. The uterus, retroverted and retroflexed, sacculated and partially incarcerated, righted itself, and delivery occurred at the fifth month.

Dr. Arthur Giles said that as Dr. Munro Kerr had referred to the two cases he had recorded in the Society's 'Transactions,' in which an extra-uterine gestation was mistaken for retroversion of the gravid uterus, he need not dwell on these; but he called attention to a case in which, as in the President's case, a retroverted uterus simulated ectopic gestation. He had seen the case with Dr. Martin, of Clapham Junction. Under an anæsthetic the mass in Douglas's pouch was reduced, and it then appeared to be distinctly bilobed; the mass on the left felt like a gravid tube. The patient had had sharp pain on the left side. He advised watching the case for a fortnight, and at the end of that time the uterus had resumed its normal shape. The patient miscarried about two months later.

Dr. Lewers said that the case in which Prof. Cameron had opened the abdomen for retroversion of the gravid uterus with retention of urine was one that seemed to him to call for some comment. He thought it would be a matter of regret if abdominal section for this condition should be acquiesced in by the Society as being a recognised mode of treating cases of this kind. In his experience at the London Hospital, extending over a period of nearly fifteen years, he had seen some three cases per annum of retroversion of the gravid uterus with retention of urine. In many of these cases the retention had been extreme; in many more than five pints of urine had been drawn off, and in two of the cases at least the urine withdrawn had been obviously mixed with blood. Yet in all these cases, forty or more, there had never been the least ground for suggesting such a severe mode of treatment as abdominal section. The treatment adopted after emptying the bladder had been either immediate replacement, generally under anæsthesia—and Dr. Lewers believed anæsthesia was of great value in facilitating the manual replacement of the uterus—or, as an alternative, rest in bed and the regular evacuation of the bladder for a few days. The uterus then rose up spontaneously. The author of the paper had mentioned that in one of his cases this treatment had been adopted, and that to his surprise the uterus had gone up into its place. Dr. Lewers believed that the treatment in question had been recognised and taught by most London teachers of obstetrics for many years. In Prof. Cameron's case he suggested that the urethra might have been dilated, and the

clots removed from the bladder with polypus forceps and irrigation, and that if the bladder had then been kept empty for a few days with the patient at rest in bed, spontaneous replacement of the uterus would probably have occurred.

Dr. Boxall wished to emphasise the advantage of rest, and specially of chloroform, in reducing the impacted uterus. In his experience many cases yielded to such treatment even when at first they had presented unusual difficulty, and in all cases the use of an anæsthetic enabled reposition to be effected with the employment of less force, and, consequently, with less risk of damage to the uterine contents. Indeed, in not a few cases the uterus regained its position spontaneously. Quite recently a case had been under his observation which well illustrated this point. It was a case of retroverted gravid uterus with a fibroid in the posterior wall simulating and mistaken for an extra-uterine pregnancy. When the case first came under observation the uterus was impacted, and no reasonable amount of force, *i. e.* considering the risk of damage likely to result, gave relief; but a few days in bed, followed by an anæsthetic, allowed the uterus to spontaneously regain its position. Then the true nature of the case at once became apparent.

Dr. Charles Morris referred to a case he saw in Dr. Matthews Duncan's wards, in which the pressure on the urethra had caused extreme retention of urine with copious hæmaturia; this was followed by the passage *per urethram* of the whole mucous membrane of the bladder in one piece. The patient recovered with complete power over the bladder. Even with such an amount of pressure abdominal section was not required, and he thought few cases would call for such an operation. When firm adhesions existed which bound down the uterus in its abnormal position perhaps abdominal section might be required, but he imagined that in such cases abortion would probably occur at an earlier period than operation would be considered necessary.

Dr. Roberts asked Dr. Kerr with regard to the fourth case related, in which the extra-uterine pregnancy simulated and was mistaken for retroflexion of the gravid uterus, if it was one of extra-peritoneal hæmatocele? Dr. Roberts pointed out that with care, and especially if an anæsthetic were given, the dangerous mistake might be avoided, although the conditions appeared similar, for in intra-peritoneal hæmatocele the one distinguishing sign is the presence of the body of the uterus lying above the pubes and in front of the swelling, whereas in retroversion the body of the uterus is, of course, absent from this situation. Dr. Cullingworth had particularly pointed this out in his paper on "Tubal Gestation with special reference to its Early Diagnosis and Treatment," read before the Oxford Medical Society, November 12th, 1897. With regard to the case (No. 2)

which Dr. Munro Kerr related, where the abdomen and bladder had been opened in order to release the incarcerated retroverted gravid uterus, Dr. Roberts could not see why such a proceeding should ever be necessary; he certainly had never seen or heard of a case; and among a large number of cases treated at St. Bartholomew's Hospital such treatment had never yet been adopted.

Dr. Amand Routh had seen a case of impacted retroverted gravid uterus diagnosed as hæmatocele, but an examination under anæsthesia would always clear up the diagnosis. He had not yet seen a case incapable of reposition without abdominal section. He had now in his ward at Charing Cross Hospital a case where retention of urine with this condition had persisted, with overflow, for the fourteen days before admission, and where 154 ounces of urine had been drawn off. It had taken three weeks for the bladder to nearly recover its muscular tone, and even now there was about an ounce of residual urine, and pus was still present in the deposit.

Mr. Butler-Smythe asked how long the efforts at reduction had been kept up previous to the operation in Case 2? He thought abdominal section in such cases was uncalled for, and an unnecessarily severe procedure, inasmuch as it added much danger to the result so far as the patient was concerned. He quite agreed with those who criticised the operative treatment resorted to. Personally he had never met with a case which required such treatment.

Dr. Herbert Spencer had seen a good many cases of retroversion of the gravid uterus, but had not met with one in which it had not been possible to replace the organ. He had, however, known several cases in which the replacement had not been effected at the first attempt, others in which the organ had righted itself after ineffectual attempts at replacement, and others in which the replacement had at first not been complete (possibly owing to slight adhesions), in which, by the exercise of a little patience and by keeping the bladder empty, the uterus had been enabled to return to its normal position. He considered that the only cases requiring abdominal section were those cases in which the retroverted organ was fixed by strong adhesions.

Dr. Munro Kerr remarked that it was no argument for Dr. Lewers and others to question the advisability of performing abdominal section for irreducible retro-displacement, because they had never met with such cases. They might criticise the alternative treatment, but there was absolutely no doubt that sometimes the uterus could not be replaced by the ordinary means. In support of this he referred to Hunter's historical case, when, on post-mortem examination, the fundus could only be raised after the symphysis had been divided, to the treat-

ment considered necessary by Olshausen and others of extirpating the organ because they could not replace it, and to a case of Jacobs, when, after opening into the abdomen, the latter could only raise the fundus after separating the adhesions that fixed it in the pouch of Douglas. Finally, he said he was perfectly well aware that cases of irreducible retro-displacement were very rare indeed; but all he claimed was that they occasionally were to be met with, and that abdominal section should be performed instead of extirpating or incising the uterus, etc.

MAY 2ND, 1900.

ALBAN DORAN, F.R.C.S., President, in the Chair.

Present 28 Fellows.

Books were presented by the Society of the New York Hospital Staff, the New York Obstetrical Society, the Société des Sciences Médicales de Lyon, Dr. Robinski, and Dr. Heywood Smith.

William Francis Victor Bonney, M.D., and Hugo Adolf Levison, M.D., were admitted Fellows of the Society.

LARGE FIBRO-MYOMA OF THE CERVIX REMOVED BY ENUCLEATION, FOLLOWED BY VAGINAL HYSTERECTOMY.

SHOWN BY DR. WALTER TATE.

THIS specimen was removed from a patient aged 49, who had had eight children and two miscarriages. The last child was born fifteen years ago. Five years ago she suffered from severe hæmorrhage, and a tumour was removed *per vaginam* at St. Mary's Hospital. After this the periods were regular till October, 1898, when she began to have severe floodings, and the periods were greatly prolonged and excessive. She kept about her work for a time, but became so weak and ill that she

had to go into the Marylebone Infirmary for six weeks, where she was treated medically. Operation was advised, but the patient was unwilling to submit to it, and left the Infirmary. After this she rested at home for about five months, the hæmorrhage being more or less continuous all the time. She then managed to do a little work for three months, but on October 21st, 1899, she was suddenly seized with violent pain in her back and inability to pass water. The following day she managed to pass a large quantity of urine, and came up to see Dr. Tate at the Samaritan Hospital in the afternoon. On examination there was a firm tumour reaching up to the umbilicus; *per vaginam* the anterior and left lip of the cervix was greatly thinned and stretched over a smooth rounded tumour, which had expanded the right and posterior portion of the cervix, bulging down the vaginal roof, and filling the posterior part of the pelvis. This tumour in the cervix was continuous with the tumour felt on abdominal examination. The patient was admitted under the care of Mr. Malcolm on December 1st. She remained in the hospital for some time resting, as she had a very profuse period after admission, and then had an attack of influenza. After this she was sent to a convalescent home for a fortnight, and on her return to the hospital had another very profuse flooding. After consultation between Mr. Malcolm and Dr. Tate, it was decided that it would be safer to endeavour to remove the tumour by the vaginal route by enucleating, being prepared to completely remove the uterus, if it seemed advisable. On February 27th, 1900, incision was made over the expanded posterior lip down on to the surface of the tumour. Free hæmorrhage occurred during enucleation, and the abdominal aorta was compressed by an assistant to control the bleeding. After a large mass of the tumour had been removed, it was seen that removal of the whole uterus would give the patient the best chance of recovery, so an incision was made through the vaginal reflection in front of and

behind the cervix, the bladder separated in front, and the uterine arteries tied. It was then necessary to enucleate more of the tumour to diminish its bulk, and to allow ligation of the middle and upper parts of the broad ligaments. The patient bore the operation well, and made an uninterrupted recovery. The tumour removed weighed 2 lbs. 6 oz. After removal of the uterus, the cavity from which the fibroid had been enucleated was seen to be very thin-walled and as large as a fœtal head. The cervical canal passed upwards along the anterior and left aspect of the mass. The tumour appeared to have expanded the cervix up to the level of the internal os, but if the level of the peritoneal reflection anteriorly can be taken to represent the level of the internal os, the tumour did not appear to have invaded the body of the uterus. The latter can be clearly made out of normal size lying on the top of the expanded cervix.

In reply to Dr. Heywood Smith, Dr. Tate said, that he did not decide to remove this uterus on account of the free hæmorrhage which occurred in the early stage of the operation, but because he considered that when such an extensive enucleation was necessary, leaving a large cavity, and probably portions of bruised fibroid tissue, the risks of sloughing of any retained portions of fibroid tissue followed by septic infection, were greater than the slightly increased risk of the complete extirpation of the uterus.

Dr. Heywood Smith would ask Dr. Tate on what grounds he concluded, that the fibroid shown was a cervical fibroid which had grown upwards. Part of the tumour was evidently sessile at the fundus, and, inasmuch as fibroids of the body are more frequent than of the cervix, was it not more probable that it began there? or perchance that the tumour was a multiple fibroid, part of which was developed in or was pushed down to the cervix.

Dr. Herbert Spencer thought that cases of cervical fibroids should usually be treated by enucleation. He had recently operated thus in a case of interstitial cervical fibroid

of the size of a duck's egg, afterwards sewing up the cavity, which healed by first intention. In Dr. Tate's specimen, in which the tumour was large and invaded the body, the capsule of the tumour was so thin that he thought hysterectomy was the more suitable treatment, especially as severe hæmorrhage occurred, and the tumour had not been completely enucleated.

Mr. Butler Smythe, who had assisted at Dr. Tate's operation, considered that the extirpation of the uterus was absolutely necessary, owing to the uncontrollable hæmorrhage which occurred during the enucleation of the fibroid. He thought such a tumour could have been removed *per abdomen* with much less risk.

Dr. Galabin formerly was reluctant to undertake abdominal hysterectomy for a large cervical fibroid, but had modified his opinions of late. In one case recently he had found the operation answer well, when enucleation would have been very difficult or impossible. Two years before he had partially detached the tumour, which reached down to the external os, hoping that the uterus would expel it, and believing it to be a fibroid involving body and cervix together. He found it so difficult to arrest hæmorrhage, that he desisted from further attempts *per vaginam*, and the tumour re-united where it had been separated. Lately, the patient returned extremely blanched by hæmorrhage, and the tumour was found to have grown outwardly into the upper part of the broad ligaments. On opening the abdomen, he found a normal uterus above the top of a large cervical fibroid, which filled the pelvis and stripped up the peritoneum from the whole of it, occupying both broad ligaments. He succeeded in enucleating it and performing panhysterectomy, but could not secure the uterine arteries supplying the tumour till the tumour had been removed, long Doyen's clamps being placed beneath it. The vessels were then tied individually, and the peritoneum sewn together above. The patient suffered very little shock, though the operation lasted over two hours, and was recovering well.

CASE OF SUPPURATING OVARIAN CYST OBSTRUCTING LABOUR, REMOVED BY ABDOMINAL SECTION EIGHTEEN MONTHS LATER.

Shown by Dr. Walter Tate.

The patient from whom this specimen was removed was a married woman aged 29. She was delivered

of her first child at full term in April, 1893, without any difficulty. In January, 1894, she attended Vincent Square Hospital for prolapse, and was told she had a tumour as large as an orange behind the womb. The second pregnancy ended in a miscarriage at five and a half months in February, 1896. She was attended in the maternity department of St. Thomas's Hospital, and the Obstetric House Physician on this occasion discovered a tumour lying in the pelvis which he took to be a fibroid. In February, 1897, when seven months pregnant, she attended the out-patient department of the Westminster Hospital, and thinks something was done to bring on labour. Shortly after this labour came on, and was completed without any difficulty. She became pregnant again for the fourth time in November, 1897, and labour came on in August, 1898. As the clerk was unable to make out the presentation, the Obstetric House Physician was sent for, and found a tumour in the pelvis obstructing the passage. Under an anæsthetic the tumour, which was thought to be a fibroid, was pushed up with considerable difficulty, and a living child was delivered with forceps. The patient made a good recovery, but ever since this time she has had a dull aching pain in the lower part of the abdomen, and the prolapse has been more marked. In February, 1900, she came to see Dr. Tate in the out-patient department at St. Thomas's Hospital. There was marked prolapse with hypertrophic elongation of the cervix. Behind and to the left of the uterus was a tense swelling, slightly depressing Douglas's pouch, and somewhat fixed. It was diagnosed to be a dermoid cyst of the ovary. On the 28th February, 1900, she was anæsthetised with ether, and a supra-vaginal amputation of the cervix was done. After this the abdomen was opened, the tumour, which was adherent to the back of the left broad ligament, was removed, and the uterus fixed to the abdominal wall by means of two silkworm-gut sutures. The tumour proved to be a suppurating cyst of the left ovary containing eleven ounces of

slightly offensive pus. The inner surface of the cyst was covered with calcareous spicules, and in two places there were perforations in the cyst-wall owing to the wall of the cyst having been the seat of "dissecting inflammation." It is difficult to say whether the suppuration in the cyst preceded, or whether it resulted from injury during the last parturition. The case shows the serious danger that may arise where any considerable force has to be used to push a tumour, obstructing labour, out of the pelvis.

FIBROID TUMOURS OF THE UTERUS WITH GREAT DISTENSION OF THE FALLOPIAN TUBES FROM TUBERCLE (FRESH SPECIMEN).

Shown by P. Horrocks, M.D.

The lady from whom this specimen was removed was fifty-three years of age and single. Her menstrual periods, which had been rather profuse, had only begun to cease during the last few months. She complained that the abdomen seemed to be getting larger and to swell up at times, and that she was in pain. On examination a smooth, moveable tumour could be felt rising out of the pelvis higher than the navel.

Per vaginam and *per rectum* a mass could be felt, to which an impulse was given from the tumour above.

The chief point of interest lay in this, that the diagnosis seemed to be clearly that of a fibroid of the uterus, and considering her age, and that she had practically attained the change of life, it seemed good advice to recommend no operation. But owing to the pain and the increase in size she was advised to submit to abdominal section with a view to hysterectomy. The opinion of Dr. Herman was obtained, and he agreed, but thought it worth while

waiting a few months to see if she improved. The patient, however, preferred not to wait, and so the operation was done.

It proved to be extremely difficult, and took three hours to perform. The left Fallopian tube was found to be enormously distended into a somewhat pear-shaped mass. This was removed first. Then the tumour was pulled forwards as far as possible, and the right Fallopian tube, similarly distended, was carefully dissected out of the bottom of the pelvis and cut from its attachments to the bowel.

The tumour and uterus were then removed, leaving a portion of the cervix behind. It was then found that there was another fibroid tumour in the right broad ligament as big as an orange; this was shelled out, and the peritoneum sewn over the extensively exposed cellular tissue.

Fortunately the two tubes were removed intact, and as there was no tubercle to be found on the peritoneum, it is to be hoped there will be no further development of it.

Of course the question of tubercle can only be decided by further investigation.

The PRESIDENT observed that hydrosalpinx was not rarely observed in association with large fibroids, nor was pyosalpinx unknown. A hydrosalpinx might, under these circumstances, suppurate, through infection from the intestine. Secondary infection with tubercle was possible in Dr. Horrocks' case.

Dr. CULLINGWORTH mentioned a case that he thought did not quite fit in with the President's theory of an infected hydrosalpinx. The patient had both Fallopian tubes distended with pus, which Mr. Shattock had little doubt was of tuberculous origin, and the uterus was studded over its surface with subperitoneal fibroids. But the fibroids at that time (they afterwards grew much larger) were of too insignificant a size to be supposed capable of even indirectly producing hydrosalpinx. The fibroids and the tubercular disease of the tubes seemed in that case, at least, to be quite independent affections.

Mr. BUTLER-SMYTHE thanked Dr. Horrocks for mentioning the time occupied in the removal of these tumours—three hours. Nowadays it was commonly stated that hysterectomies were performed within the hour by the improved methods. He, Mr.

Butler-Smythe, could well imagine that Dr. Horrocks' operation could not have been completed under the time stated.

CASE OF MYXOMA OF CHORION NOT DISCHARGED TILL THE SEVENTH MONTH.

Shown by Dr. C. Hubert Roberts.

K. S—, woman aged 45. Had had seven children, three miscarriages. Last full-term child seven years ago. Two and a half years ago a missed labour at sixth month, the retained dead fœtus was removed.

August, 1899, again pregnant.

October, 1899, had some losses of blood.

December, 1899, something came away but uterus seemed proper size; breasts were active.

March 5th, 1900 (then seven months pregnant), after a few heavy losses had a severe hæmorrhage. Her doctor had put in tents but could feel no child, neither could I. Admitted to hospital same day, very ill.

The uterus then was felt two inches above the navel.

March 6th, temperature 106°; rigor, severe loss, and mass expelled; mole. A large mass was emptied out of uterus under anæsthetic.

Remarks.—Specimen shows nothing very important, but careful search has been made to see if anything like new growth could be found in connection with the mole retained for some seven months. There is none.

Sections show very well the healthy plasmodial layer of villus and buds. There is nothing like malignant proliferation.

The myxomatous changes affect the stroma (mesoblastic portion of the villus). The compact layer of the decidua serotina is well seen.

Sections of myxoma of chorion are of value in relation to the present question of deciduoma malignum.

IMPERFORATE RECTUM AND CONGENITAL PROLAPSE OF THE UTERUS.

Shown by Dr. H. R. Andrews.

Dr. H. R. Andrews showed a specimen of imperforate rectum and congenital prolapse of the uterus, for which he was indebted to Dr. Herman.

At birth the child presented no unusual appearance. A few hours later a red swelling appeared at the vulva. When seen forty-eight hours after birth there was a tumour in front of the anus very much resembling prolapse of the rectum. It was about the size of a Tangerine orange, deeply congested, bleeding rather readily on examination, and presenting swollen folds of mucous membrane separated by deep sulci, covered with blood-stained mucus. At first it was thought to be a case of inversion of the bladder, as the finger could be passed into the vagina behind the mass, but after careful examination the meatus urinarius was found in front of the tumour.

The tumour, which was proved to be the much-swollen cervix, could not be pushed up into the vagina.

The abdomen was much distended. The anus admitted the tip of the finger, but the rectum was found to be imperforate. Left inguinal colotomy was performed. After this the cervix was able to be pushed up. It came down, however, almost immediately, and was then returned, and pressure put on with gauze and strapping. After a week the uterus remained up in position without any pressure.

The child presented no other abnormalities.

The child died on the twelfth day.

The specimen shows the cervix still considerably swollen.

Cases of congenital prolapse of the uterus are rare.

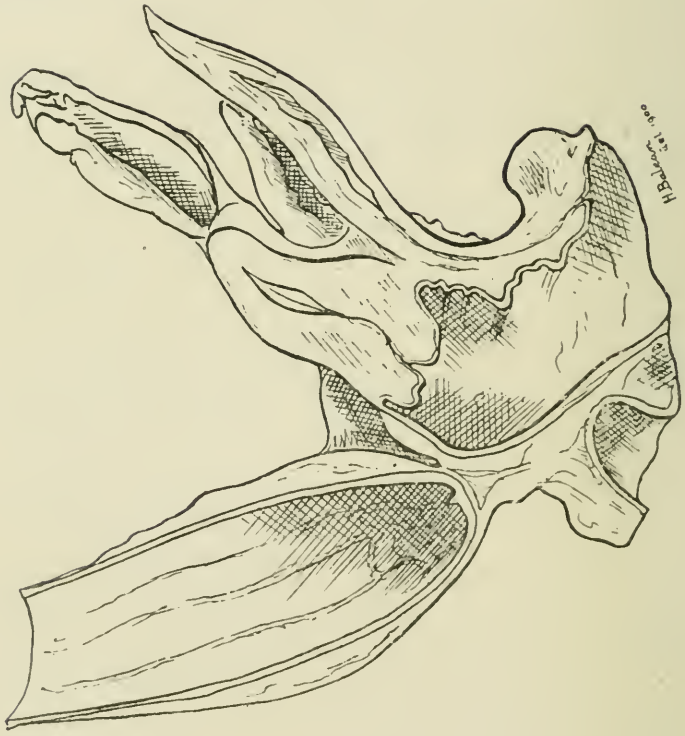

Ballantyne and Thomson, in the 'American Journal of Obstetrics,' February, 1897, collected eight cases, viz. :

1. Schultz. "Prolapsus uteri congenitus," 'Verhandl. d. ver. pfälz. Aerzte,' 1856, Kaiserslantern, p. 48, 1857.

2. Krisling (N.). "Prolapsus uteri completa hos et nyfodt Barn," 'Norsk Mag. f. Laegeridensk.,' 4 R, iv, p. 265, Christiania, 1889. Also "Prolapsus uteri completa bei einen neugeborenen Kinde," 'Arch. f. Kinderh.,' xii, p. 81, Stuttgart, 1890–91.

3. Schaeffer (O.). "Bildungs Anomalien weiblicher Geschlechtsorgane aus dem fötalen Lebensalter, mit besonderer Berücksichtigung der Entwickelung des Hymen," 'Arch. f. Gynäk.,' xxxvii, p. 244, 1890. Also in F. von Winckel's 'Die Königliche Universitäts-Frauenklinik in München in den Jahren 1884–90,' p. 537, 1892.

4. Heil (K.). "Ein Fall von angeborenen Prolapsus uteri et vaginæ incompletus," 'Arch. f. Gynäk,' xlviii, p. 155, 1894.

5. Remy (S.). "Spina bifida—ulcérations péri-anales —Prolapsus complet des organes génitaux internes," 'Arch. de Tocol.,' xxii, p. 904, 1895.

6. Krause. Case reported and figured by F. L. Neugebauer in his "Kilka slow o Mezkiem owlosienin u. Kobiet," 'Gaz. lekarska,' xvi, p. 1223, Warszawa, 1896.

7. Ballantyne and Thomson. 'American Journal of Obstetrics and Diseases of Women and Children,' vol. xxxv, p. 161.

8. McVicar (C.). Ibid.

In all except the first of these cases there was also spina bifida.

Radwansky — 'Münch. med. Wochenschrift,' xlv Jahrg., No. 2—records a ninth case, in which there was no spina bifida.

The present case, in which there was no spina bifida, brings the number of recorded cases up to ten.

Dr. Andrews wished to express his thanks to Dr. Blacker for his kind assistance in searching for the above records.

Besides the clinical interest of this case the specimen is interesting as showing, as Dr. Keith pointed out, the development of the perinæal body from two lateral outgrowths which form a septum across the proctodeum, separating the anus from the vaginal opening. The exact manner in which this separation takes place is not considered by embryologists to be settled.

In this specimen, at any rate, the separation has not taken place by a downgrowth from above, but by union of lateral outgrowths.

Dr. Andrews also showed a second specimen, in which the rectum opened into the vagina, the cloacal opening not having been differentiated into anal and vaginal openings.

Dr. Arthur Giles said that it might not be generally known to the Fellows of the Society that there was a very interesting specimen of a cloacal opening in association with a double uterus and vagina in the London Hospital Museum, numbered 2183, of which the following was a description:—The right vagina, the urethra, and the rectum opened into a common cloaca. The normal right half-uterus opened into this vagina. The left vagina had no external outlet, nor could a probe be passed from it into the small left uterus, which measured one and a half inches in length. The left Fallopian tube was not patent at the uterine end; its external half was dilated to a sac the size of an orange, filled in the recent state by thick chocolate-coloured fluid. The left vagina contained a similar fluid. The obliteration of the two extremities of the left uterus was therefore secondary. The woman was aged fifty-six, and had borne two healthy children. The cloacal condition was discovered shortly before death by the house physician, who had ordered an enema. The double uterus was found by Dr. Sutton at the autopsy.

The President referred to his dissection of a monotrematous girl of eleven, which he had exhibited at a meeting of the Society in 1880.* The vagina and rectum both opened into the vulva; the ovaries and uterus were normal. This dissection is to be seen in the Teratological Series in the museum of the Royal College of Surgeons (No. 669).

* "Congenital Communication between the Rectum and the Genito-urinary Tract," 'Trans. Obst. Soc.,' vol. xxii, p. 79.

DOUBLE TUBERCULOUS PYOSALPINX WITH INTERCOMMUNICATION OF THE TUBES.

By A. L. Galabin, M.D.

(With Plate XIII.)

The patient was aged twenty-nine, and had been married nine years but never pregnant. Five years ago she had a severe illness, with great abdominal pain, and was then told by a doctor that she was six months pregnant. There was no amenorrhœa, and the supposed pregnancy came to nothing. She did not herself definitely notice a lump in the abdomen till two and a half years ago. Of late she has had darting pains and great tenderness of the abdomen, and at times considerable difficulty in micturition. Menstruation has been regular and not profuse; duration four days; latterly severe pain for two days before the onset of the flow. Last period three weeks before admission. Has had leucorrhœa for some years, but there is no history of gonorrhœal infection.

The lower half of the abdomen was found distended by a tumour reaching a hand's breadth above the umbilicus, and more prominent on the left side. Its surface was not uniform, but owing to obesity of the abdominal wall the outline of the tumour was not easily defined. A thrill was obtained, though with difficulty. The cervix uteri was pushed forward by a large elastic swelling behind it, which appeared to be continuous with the abdominal tumour, and a distinct impulse was transmitted to the pelvic swelling by pressure on the abdomen. The sound passed four and a half inches in front and to the left of the pelvic tumour. A diagnosis of ovarian cyst which had become inflamed was made, and there was no reason to suspect pyosalpinx. Abdominal section was performed. The following account of the operation and the description of the specimens has been contributed by Mr. Targett:

At the operation signs of acute peritonitis were found; there was lymph on the intestines, increased vascularity, and excess of fluid in the peritoneum. The nature of the tumour was not apparent until quite the end of the operation, and its anatomical relations were complicated by extensive adhesions, which had to be separated before the tumour was exposed. Thus on the left side the sigmoid flexure, with its thickened appendices epiploicæ, covered it, and on the right the appendix cæci was adherent. The omentum was lying in front, and was glued to the abdominal wall just above the bladder. The portion of the tumour which was first exposed proved to be a right pyosalpinx, which was pushed forwards and, indeed, over to the left side of the abdomen by a second swelling, which was the left pyosalpinx, occupying Douglas's pouch. The relations of the right broad ligament were greatly distorted owing to this displacement to the left, and the consequent rotation of its attachments along with the uterus. The bladder was free, but the upper (right) pyosalpinx was much adherent to the fundus and front of the uterus, as well as the utero-vesical pouch. Most of these adhesions, being recent, were easily separable. The whole tumour, consisting of the united Fallopian tubes, had to be drawn out of the abdomen before the chief parts of their thick pedicles could be tied. The left ovary seemed normal, and was not removed. The pouch of Douglas was very deep owing to the pushing up of the uterus and stretching of the broad ligaments, but the rectum was almost free, and the left pyosalpinx, which occupied the pelvic pouch, had evidently not been adherent to any important extent. No pus escaped from the tubes during the operation, and after the abdomen had been carefully sponged out a Keith's tube was passed to the bottom of Douglas's pouch and the incision was closed. The drainage-tube was removed at the end of the third day, and a good recovery ensued, though there was some pyrexia for a fortnight.

Description of the specimen.—The specimen consists of

DESCRIPTION OF PLATE XIII.

Illustrating Dr. Galabin's specimen of Double Pyosalpinx intercommunicating.

A. Upper (right) pyosalpinx rotated over to left side.

B. Cut edge of right pedicle.

C. Lower (left) pyosalpinx which filled Douglas's pouch.

D. Adhesions of omentum and appendices epiploicæ.

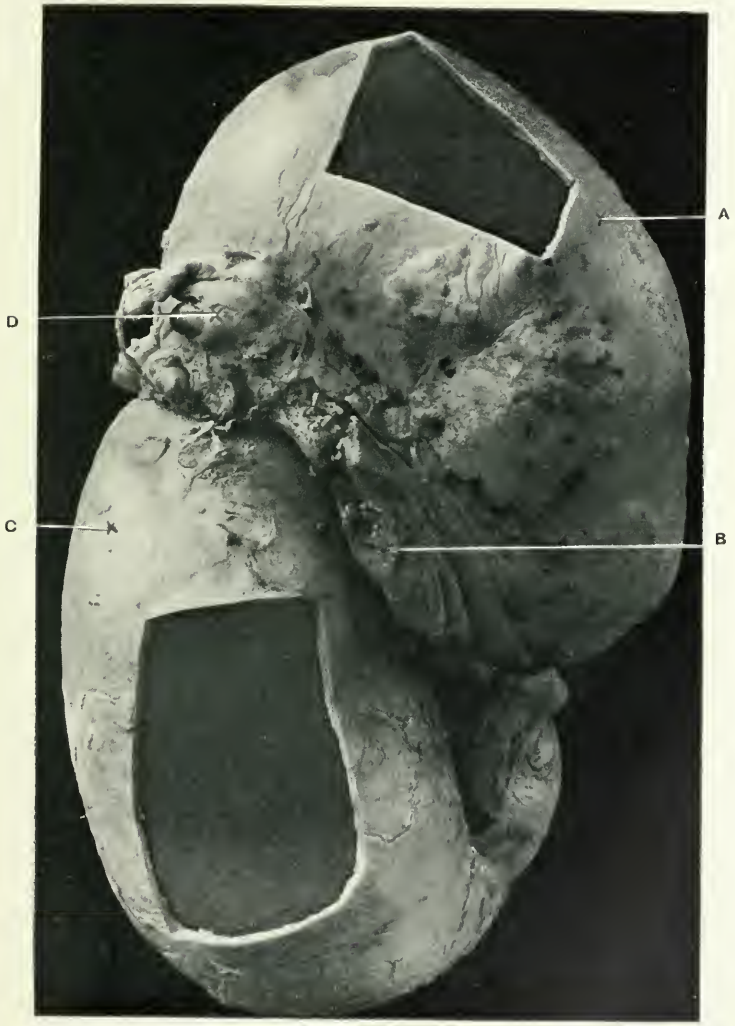

Illustrating Dr. GALABIN's Specimen of Double Pyosalpinx Intercommunicating.

Bale, Sons and Danielsson, Ltd.

two enormously dilated Fallopian tubes, which are firmly united at their broader ends, where a communication has formed between them. The lower sac, which occupied Douglas's pouch and is the dilated left tube, measures seven inches in length and four inches in the shorter diameters. The uterine end of the tube at the line of amputation is not dilated, but beyond this it swells into a tortuous cylindrical canal, three inches in length and one and a half inches in diameter, and then becomes a large pyriform cyst with the above dimensions. The fimbriæ springing from its closed abdominal ostium are healthy. The interior of this pyosalpinx shows much destruction of the mucous membrane in the form of rounded ulcers undermining the coat and thinning the wall. The ulceration is specially marked where the two tubes are in close apposition, and the process has terminated in perforation of their walls, so that the tubes communicate through an aperture one inch in diameter. Their fibrous adhesions are widely distributed over the serous surface of the pyosalpinx, though they are not dense nor very abundant. The upper sac is the right tube, and it corresponds so closely in size and shape with the left tube that it needs no further description. The grooves between the bulbous ends of the dilated tubes are filled with adhesions and small collections of serous fluid.

In the recent state the united tubes contained three pints four ounces of thin pus, which was found to be sterile. Microscopical sections of the wall of the pyosalpinx showed that the mucous membrane had disappeared, and that the muscular coat was lined with granulation tissue containing a few giant-cells. Sections were also prepared from the thickened but undilated uterine end of the pyosalpinx, and these revealed abundant evidence of tuberculous salpingitis. The mucous coat was crowded with grey tubercles presenting well-formed giant-cell systems, and the usual round inflammatory cells infiltrated the stroma, but the columnar epithelial lining was still *in situ*.

THE RELATIONS OF ORGANIC AFFECTIONS OF THE HEART TO FIBRO-MYOMA OF THE UTERUS.

By Dr. Thomas Wilson, Birmingham.

(Received March 10th, 1900.)

(*Abstract.*)

The author calls attention to the necessity for attempting to arrive at a just estimate of the natural history and dangers of fibro-myomata of the uterus, and remarks that in every case that comes under notice it is important to look out for the possible evil effects on the other organs of the body that may have been caused by the growth of the uterine tumour. The symptoms and signs of serious organic affection of the heart are not unfrequently found in association with the presence of a uterine fibroid, and the conjunction is sometimes casual, the tumour of the womb growing in a patient already the subject of heart disease. In an appendix to the paper short notes of three cases belonging to this class are given, and it is pointed out that the heart symptoms may be greatly aggravated.

In a much larger number of cases the connection between the diseases of the two organs is causal, the heart affection being set up by the growth of the fibroid, or both being dependent on a common cause. Occasionally the heart may be affected directly by the pressure of a very large cystic fibroid, or indirectly by a tumour pressing on the ureters and so leading to renal degeneration, that in its turn leads to cardiac changes. Much more commonly a fibroid of moderate size leads through menorrhagia to anæmia, and thus to cardiac dilatation or degeneration; or, again, in the early stages of the growth of a tumour

cardiac hypertrophy may be found, and this latter may give place to dilatation and degeneration. It is not at present understood how the hypertrophy is brought about, but the condition is in some degree analogous to the enlargement of the heart found in pregnant women; there is the important difference, however, that the causing affection, pregnancy, in the latter case is definite in duration, whereas the period of active growth of a fibroid is indefinite.

The history is described in detail of a patient who had symptoms of an interstitial fibroid for four and a half years; there had been several attacks of retention of urine, and the symptoms of cardiac weakness were decidedly increased by ergot. Double oöphorectomy was performed, and was followed by alarming heart failure lasting several days. The patient made eventually a good recovery, and the condition of the heart showed a gradual but very marked improvement. Six other cases which occurred in the author's practice, and in which organic disease of the heart was apparently caused by the growth of fibroids, are shortly related in the appendix to the paper. The nature of the cardiac affection, the varieties of uterine fibroids which were present in the cases, the cardiac symptoms and signs, and the course and prognosis are then in turn considered, and it is pointed out that after a successful operation the heart tends to recover its tone in a really remarkable degree.

The presence of the cardiac disease favours the occurrence of thrombosis both before and after operation; it forms a contra-indication to the use of ergot in the treatment of the fibroid, and it may be an important and even urgent indication for operative interference. When an operation is undertaken every effort must be made to reduce as far as possible the severity of shock and the risk of subsequent heart failure. Ether is usually the best anæsthetic, and the free use of strychnia hypodermics and saline subcutaneous infusions, or even venous transfusion, may be required. The risk of sepsis is distinctly greater than usual, and early stimulation and feeding are of the utmost importance. Six of the seven cases related recovered from the various operations which were undertaken; the seventh, after going on well, died suddenly and unexpectedly

on the tenth day from perforation of a latent duodenal ulcer. Of the other six cases four were examined after a sufficient interval had elapsed after the operation, and in every one of the four there were distinct evidences of improvement in the condition of the heart.

The advance in operative methods and the gradual improvement in results obtained during recent years in the radical treatment of fibro-myomata of the uterus render it more than ever necessary that no effort should be spared to arrive at a just estimate of the natural history and dangers of these tumours. The tendency in the past appears to have been for medical men rather to underrate the magnitude of the risks and discomforts which may attend the growth of a fibroid, and to lull themselves and their patients into what has frequently proved to be a false sense of security by oracular and sweeping generalisations on the changes which might be expected to take place in the tumour after the menopause. It is true that in many cases where marked symptoms arise through the growth of a fibroid, both the symptoms disappear and the tumour shrinks with the advent of the menopause. It is equally true, as is proved by comparing post-mortem observations with clinical experience, that a much larger number of fibroid tumours of the uterus run their course without giving rise to any discoverable, or at any rate to any discovered symptoms. But it is not less true that many of these tumours give rise either directly or indirectly to serious and even fatal effects.

The ways by which a fibroid may give rise to grave troubles are many and varied, and sometimes devious, and require to be borne in mind when our opinion is sought in any given case. The tumour may continue to grow after the menopause, or may postpone the onset of the menopause for years beyond the usual time, even to the age of fifty-eight, as in one of my own cases. Hæmorrhage due to the presence of the tumour may directly lead to a fatal issue, as happened in a case reported by me in the 'Bir-

mingham Medical Review' for November, 1894, page 290. Thrombosis sometimes occurs, and sudden death from embolism has been known to happen, especially in fibro-cystic tumours. Serious mechanical effects, such as strangulation of a pedunculated tumour, or pressure causing intestinal obstruction, may lead to the death of the patient. Various degenerations may occur and cause serious consequences. A metamorphosis of the tumour into a malignant sarcoma is believed occasionally to take place. Inflammation and its consequences, suppuration, sloughing, and gangrene, may be set up by labour or abortion, or by traumatism. And in the last but by no means least place, fibroids of the uterus may give rise to grave secondary affections of other systems and organs, more especially of the kidneys, of the heart, and of the blood. It is necessary, therefore, in every case of fibroid that comes under our notice, to pay careful attention to the possible evil effects on the other organs of the body that may be produced by the growth of the uterine tumour.

I propose in the present communication to deal with the large and important group of cases in which organic affections of the heart are found in association with uterine fibroids. In any given case where this association is found there are four possibilities. In the first place, the two affections may arise independently, the heart disease usually being first in order of time. In the second place, it may be, as has been suggested by Strassmann ('Arch. f. Gyn.,' vol. lvi), that both the myoma and the heart affection are symptoms of a disease depending on vaso-motor disturbances, such as we see, for instance, in exophthalmic goitre. In the third place, the fibroid may cause the heart affection, and in the fourth the heart disease may cause the fibroid. This fourth possibility may be at once set aside, since nothing is known to support the idea of such a relation.

Fibro-myoma in Patients already the Subject of Heart Affections.

When in a patient the subject of organic disease of the heart a fibroid of the uterus begins to grow, very serious consequences may follow. Any large tumour growing in the abdomen tends to raise the blood-pressure, and thus to increase the work that has to be done by the cardiac muscle; and this appears to be especially true of fibroids. I have seen three cases in which cardiac affections have apparently preceded the growth of fibroids, and a short summary of the notes of these cases will be found at the end of this paper (Cases 8, 9, and 10). In one of them there had probably been mitral stenosis for twenty-five years, and the growth of a multinodular fibroid had in the course of eighteen months enormously increased the gravity of the cardiac symptoms. In the second case (Case 9) the patient had probably had pericarditis in an attack of rheumatic fever ten years before the removal of a fibroid which had been growing for two years; the operation of hysterectomy was followed by the development of a double murmur and rapid pulse, which persisted for some days. In the third case (Case 10) it appears to be at least possible that the heart affection helped to account for the rapidly fatal termination of an inflammation which attacked a fibroid of fourteen years' standing when the patient was fifty-nine years of age.

Among the other consequences of the growth of fibroids in a patient already the subject of cardiac disease it appears that the tumour may lead to an erroneous diagnosis, and so to treatment which may have a prejudicial effect on the heart. Thus in a case reported by Dower in the 'New York Med. Journ.,' 1884, vol. xxxix, p. 505, a married woman aged thirty-six was the subject of a fibroid that was mistaken for pregnancy; attempts to procure abortion failed; the patient was the subject of heart disease, and died suddenly in an attack that began with precordial pain. The autopsy showed the presence

of mitral stenosis and aortic regurgitation with hypertrophy, and evidence of recent endocarditis. In the uterus was a small pedunculated subperitoneal fibroma, and several small interstitial ones.

Heart Affections caused by Fibro-myoma of the Uterus.

Cases in which cardiac disease arises in consequence of the growth of a fibro-myoma are much more frequent and important, and appear to me to call for greater consideration, than has been accorded to them in the past. The affection of the heart may be brought about in various ways, direct and indirect. The tumour may press on the ureters and lead to degeneration of the kidneys, and this may in turn lead to cardiac hypertrophy followed by dilatation and degeneration. The heart again may be directly pressed upon by a very large cystic fibroid just as by any colossal abdominal tumour. Fenwick ('Brit. Gyn. Journ.,' May, 1887, vol. ii), in a paper on "Intra-abdominal Tumours as a Cause of Cardiac Degeneration," cites among other cases three large fibro-cysts of the uterus. In these large tumours increased pressure on the pleural cavities interferes with the oxygenation of the blood, and thus leads to fatty degeneration of the heart. The injurious effect is increased by pressure on the heart itself, on the afferent and efferent vessels, and on the nutrient vessels. Sebileau ('Rev. de Chir.,' pp. 284, 339), in a paper on the same subject, mentions among other cases of heart affection in large abdominal tumours, three patients with large fibroids.

Cardiac disease brought about in either of the two ways just mentioned is comparatively rare in cases of fibro-myoma. A very much more frequent link in the chain of causation is found in the anæmia which is often set up by excessive and repeated losses of blood; the anæmia leads to defective nutrition of the heart, as of the other organs of the body; the heart's action, therefore, becomes

weakened, its cavities dilated, and its walls after a time degenerated. This is probably the most common sequence of events in patients who become the victims of serious heart disease as a result of the growth of a fibroid of the womb. There is, however, still another group of cases which appears to me to lend a certain support to Strassmann's theory of a common cause for the uterine fibroid and the cardiac condition. In this group, to which belong Cases 2, 5, and 7 in the Appendix, hypertrophy of the heart arises while yet the tumour is of moderate size, and after a time the hypertrophy is followed by dilatation of the cavities and degeneration of the muscular walls of the organ.

The origin of the heart affection in this last group of cases calls to mind the, in some respects, similar affection of the heart which arises in pregnancy. During pregnancy, according to Spiegelberg ('Midw.,' New Syd. Soc. transl., vol. i, p. 85), more blood circulates and the heart is called upon to do more work; hence arises concentric hypertrophy of the left ventricle. This occurrence of hypertrophy and enlargement of the heart has been confirmed by Angel Money in a series of observations of pregnant women. Pregnancy is, however, a physiological process of limited duration, and the heart soon returns to its normal condition and size after delivery. In the case of fibroids, on the other hand, the growth is apt to be peristent for an uncertain time, and hypertrophy of the heart once begun is apt to lead to serious consequences.

The nature and frequency of serious affections of the heart in the cases we are considering has been dealt with by, among others, the following observers. Hennig ('Festschrift der Gesellsch. f. Geb. und Gyn.,' 1894) mentions four cases of fibroids with palpitations, dyspnœa, and pains in the chest. In one patient there was distinct hypertrophy, but in the other three there was no evidence of organic cardiac disease. In two patients the symptoms disappeared after the removal of the tumours, and in the other two they disappeared spontaneously when the

fibroids ceased to grow. Hofmeyer ("Zur Lehre von Shock," 'Ztsch. für Geb. und Gyn.,' 1885, vol. ii, p. 366) gives seven cases of myoma in which death took place suddenly before or after operation. In two of the cases there was fatty degeneration, and in the other five brown atrophy of the myocardium. Strassmann and Lehmann in a recent paper give the results of their observations on a series of seventy-one cases of uterine myoma, in twenty-three of whom there were objective pathological changes in the heart or its functions. In the post-mortem examinations of nineteen cases of myoma some affection of the heart was observed in nine.

The case that first forcibly drew my attention to this connection between fibroids and grave affections of the heart was the following:

Case 1. *Multiple interstitial fibroids, four and a half years, giving rise to attacks of retention of urine, and to symptoms of cardiac weakness increased by ergot. Double oöphorectomy, followed by alarming heart failure; eventual good recovery.*—A. H—, a thin, worried-looking widow of thirty-seven, had borne three children, all at the seventh or eighth month, the last one thirteen years before her first visit to the General Hospital on October 5th, 1894, when she attended complaining of retention of urine and flooding. The present complaints had lasted about a week, and there had been several previous similar attacks in the preceding four and a half years. After forty-six ounces of urine had been drawn off by the catheter, the uterus was found to be enlarged into a hard irregular tumour extending upwards to a little above the umbilicus, and at the lower part filling up the pelvic brim: the bladder, when distended, was felt to lie entirely above the brim. The use of the catheter was required daily until October 27th, after which micturition was again performed voluntarily.

The patient was somewhat anæmic, and suffered from occasional attacks of faintness and palpitation: these

attacks were markedly increased in frequency and intensity by the administration of ergot, which had to be stopped in consequence. There was no history of rheumatic fever.

The woman was admitted into the hospital on December 4th, 1894, and on the 11th, during an examination, an attack came on, in which she became pale and livid, and appeared dazed; the pulse during the attack was very weak, and the breathing shallow and catchy. Similar attacks occurred at frequent intervals during the patient's stay in hospital. The heart's apex-beat was felt in the normal position; the area of dulness was not increased; there was no murmur, but the first sound was weak and not quite clear. The daily amount of urine from December 7th to 13th inclusive varied from thirty-six to forty-eight ounces; the quantity of urea passed on three of these days measured 176, 288, and 216 grains respectively.

The woman was sent to the Jaffray Hospital, where she remained until February 15th, 1895, when she was re-admitted to the General Hospital with a view to operation. From February 17th to 21st the daily amount of urine varied from thirty-two to forty ounces, and the amount of urea on two of these days measured 360 and 323 grains. The patient's general appearance had not notably improved, but there had been no fainting attacks during the latter part of the stay at the Jaffray Hospital.

On March 7th, 1895, both ovaries were removed. Chloroform was first employed as the anæsthetic, but soon had to be changed for ether. The operation presented no unusual difficulties; at its close there was a fair pulse, but after the patient was returned to bed the pulse became weaker and could not be felt at the wrist. Five hours later there was still no radial pulse, but the lips and mucous membranes were of fair colour; the breathing was hurried; the patient restless but perfectly conscious. Enemata containing one ounce of brandy were ordered to be administered every two hours to alternate with

hypodermic injections of five minims of Liq. Strychniæ, also to be given every two hours. In addition a subcutaneous injection of one fifth grain of morphia was given at 10 p.m. At 9 a.m. on March 8th the patient was somewhat better; the pulse, 120 to the minute, was perceptible at the wrist; the temperature had only once reached 98° since the operation, and only nine ounces of urine had been passed in the twenty-four hours.

The subsequent convalescence was slow but on the whole steady, free stimulation being continued and only very gradually diminished. There was no vomiting after the first twenty-four hours; flatus was passed for the first time in twenty-four hours, and urine naturally thirty-six hours after the operation. A few days after operation a bedsore formed over the sacrum, and was not quite healed when the patient was discharged to the Jaffray Hospital on the forty-third day. Some distension was noted on the ninth day, and continued, becoming somewhat more marked, until discharge from the hospital; the abdomen remained soft and flaccid.

On the ninth day after operation the breathing was still somewhat hurried. Dr. Short kindly examined the woman for me, and reported that the lungs were clear, and air entering freely. The first sound of the heart was somewhat rough, and there was occasional reduplication of the same sound at the apex. Dr. Short thought that the condition was due to weakness of the cardiac wall and not to any pulmonary trouble. The patient was now passing a large quantity of dark urine.

The tumour, which at the time of the operation extended nearly to the umbilicus, had receded three inches below that point by September 17th. At that date the woman still complained of feeling weak, and had had some more fainting attacks lately.

At the beginning of June, 1896, a small fibroid sloughed out through the middle of the abdominal scar, leaving a sinus that still remained open on January 6th, 1897, twenty-one months after the operation. At this latter date the

patient was looking very well and had been working hard; the cardiac sounds were normal at the apex; a soft systolic murmur was heard at the base, and over both the aortic and pulmonary cartilages.

On October 22nd, 1897, Dr. Short again examined the patient, and reported that the heart was somewhat dilated and hypertrophied, the apex-beat being in the nipple line; the impulse was good, heaving, and regular; the first sound was prolonged, but no murmur was present. The pulse was of fair quality, 88, and quite regular. Since then the woman has gradually improved in strength and appearance; she was last seen a few months ago, when she had been for some time earning her living as a hard-working housekeeper.

The points to which I wish especially to draw attention are the symptoms and signs of cardiac degeneration presented by the patient—the attacks of faintness and palpitation; the increase in these attacks produced by the administration of ergot; and the decided diminution in the amount of urea excreted by the patient whilst under observation before operation. Further the alarming heart failure after the operation, the hurried breathing which persisted for more than nine days afterwards, the formation of a bedsore in spite of careful nursing, and the development of slight but persistent distension of the abdomen. The recovery from such a grave condition of illness as was presented by this woman at her first attendance at the hospital was most gratifying.

Since this case was under treatment I have had six other patients, making seven in all, in whom a direct causal connection between fibro-myoma of the uterus and serious organic disease of the heart appeared to me to be convincing. A short *résumé* of the notes of each case is appended to this paper. I have not brought into consideration the numerous cases in which a soft murmur or reduplication of the heart-sounds were present, or in which there existed symptoms, slight in degree, that might have been put down to the heart.

With regard to the nature of the affection of the heart in these seven cases, signs of hypertrophy were found in two, signs of dilatation in three, and evidence of degeneration in the other two. In one of the cases of hypertrophy (Case 2) an interstitial fibroid, weighing after removal 3 lbs. 11 oz., had been giving rise to symptoms for two years; in the other (Case 5) a submucous fibroid the size of a fœtal head had been growing for two and a half years. In one of the three cases of dilatation (Case 3) a cervical interstitial fibroid the size of a child's head was removed by vaginal hysterectomy after it had given rise to symptoms for one and a half years; in a second (Case 6) an interstitial fibroid that had been growing for six and a half years and that weighed 3¼ lbs. was removed by hysterectomy; and in the third (Case 7) numerous interstitial fibroids had been giving rise to symptoms for one and a half years before total abdominal hysterectomy was performed. The woman died suddenly on the tenth day after operation from the perforation of a duodenal ulcer, and at the autopsy dilatation of the heart with brown induration and some fatty degeneration of its walls were found. Of the two cases of cardiac degeneration, in the one above related at length (Case 1) multiple interstitial fibroids had been giving trouble for four and a half years, and in the other (Case 4) a submucous tumour extending to 1½ inches above the umbilicus had been causing symptoms for six years before it was removed by total abdominal hysterectomy.

Turning now to the characteristics of the uterine tumours in the cases under consideration, it will be noted, in the first place, that although the symptoms due to the heart affection in several of the patients were of considerable gravity, the growth of the uterine tumour had only attained a moderate size. The largest tumour only extended to 1½ inches above the umbilicus, while in two cases the tumour measured only about the size of a fœtal head. In most of the cases only one tumour and that of

considerable size was found, but in at least two instances multiple small interstitial tumours were present.

As regards the variety of the fibroid, according to its locality of growth, it will be noted that one patient had a cervical fibroid, and the other six corporeal tumours. The cervical tumour was an interstitial one ; of the six affecting the body two were submucous, and four interstitial. In the two cases of hypertrophy one patient had a submucous, and the other an interstitial fibroid. It appears, therefore, that hypertrophy followed by dilatation and degeneration of the heart may arise in consequence of the development of either cervical or corporeal fibroids, whether they be submucous or interstitial ; but no instance of cardiac disease in a patient with a subperitoneal tumour was observed.

The duration of the growth of the fibroids before coming under observation varied ; the average duration in the cases in which the heart was hypertrophied was decidedly shorter than in the cases of dilatation and degeneration. In the two cases of hypertrophy the duration was two and two and a half years respectively. In the five cases of dilatation and degeneration the duration was only one and a half years and two years respectively in two cases with marked evidence of serious heart affection ; in a third, the one above related at length, symptoms of the fibroid existed for four and a half years ; in the other two patients the duration was six and six and a half years respectively. The average duration, therefore, in the cases of hypertrophy was two and a half years, and in those of dilatation and degeneration a little more than four years.

Symptoms and physical signs.—Among the symptoms to which the heart affection may give rise are palpitation, spontaneous or on exertion ; attacks of faintness, of syncope, and of giddiness ; hurried breathing, which may be persistent for some time, and dyspnœa coming on especially after exertion. As the disease advances nutrition becomes seriously interfered with, there is decided wasting, marked general weakness, and the complexion assumes a muddy,

dirty hue. The pulse becomes frequent, feeble, and excitable. The physical signs that were observed were visible diffusion of the apex-beat; strong and heaving, or weak and slapping impulse, felt over a larger area than normal; increased area of cardiac dulness; weakness of the sounds of the heart, and especially shortening of the first one; and the presence of murmurs, usually soft in character.

Course and prognosis.—It seems to me probable that in not a few cases of fibro-myoma of the uterus the heart may become gravely affected in this way, and that after a time the tumour may undergo regressive changes, leaving the heart affection permanent. In such circumstances due significance may not be attached to the presence of the uterine tumour, and it is easy to conceive that the cardiac affection may lead to the death of the patient and be erroneously supposed to be the primary cause of the fatal issue. In other words, fibro-myoma of the uterus may lead through the heart indirectly to the death of a patient without obtaining the credit for that death which it deserves.

The causation of heart disease by fibroids of the uterus has a most important bearing on the question of operation in certain cases. The heart should always be carefully examined in cases of fibroid disease, and evidence of hypertrophy should be looked upon as one of the most important indications for operation. Where dilatation or degeneration is already present, and where the disease has not already advanced too far, the indication for the removal of the tumour is even more stringent, care being first taken to bring the patient into as good condition as possible, by rest in bed and nourishing food.

When operation is undertaken the risks are markedly increased by the concurrent disease of the heart. Shock is apt to be excessive and may be prolonged, as is well illustrated by the case already related. Great care may be required to guard against the formation of a bedsore after the operation, and even the most skilful nursing

may be insufficient to prevent it in severe cases. At a later stage of convalescence there seems to be more than the usual risk of thrombosis of some or other veins of the lower extremities, an accident favoured also by the anæmia which is usually present. Thrombosis occurred in two of my cases; in one there was marked anæmia, and the determining cause was a septic invasion of the wound in the vagina; in the other patient there had been a previous attack of thrombosis before the operation, and the cardiac affection may fairly be put down as at least a strongly predisposing cause. The risk of sepsis following operation is also markedly increased by reason of the diminished resistance offered by the enfeebled and badly nourished tissues.

The outlook as regards the affection of the heart after the tumour of the womb has been successfully removed by operation is distinctly favourable. In four out of my six cases after recovery from operation it was possible to learn something of the patients after a sufficiently long interval had elapsed, and in every one of the four there was distinct evidence of improvement in the condition of the heart. In some of the cases the improvement was very marked, as, for instance, in the woman whose history has already been given at length.

Treatment.—A few words about the treatment must suffice. Where there is hypertrophy of the heart, unless after a short trial of medicinal means the tumour ceases from growing and from causing symptoms, operation should be urgently recommended. At a later stage, when there is evidence of heart failure, the patient should, as far as possible, be built up by rest in bed and nourishing diet, and the tumour should then be removed. In the presence of cardiac affection it may be in the highest degree dangerous to give ergot, on account of its depressing effect on the heart, as was well seen in the case above related.

When an operation is undertaken the greatest care must be exerted to prevent shock, by minimising the loss

of blood and loss of heat from the patient as far as possible. The best anæsthetic will usually be ether; but it is to be borne in mind that, although the patient may apparently bear the proceeding well, yet collapse may set in and be severe after the effect of the ether has passed off. In the course of the operation it may be necessary to give hypodermic injections of strychnia solution, and this should be done freely. The injection of saline fluid is also frequently of the utmost service, and may be given under the skin or, in the more severe cases, into a vein. After the operation the patient must be well wrapped up in warm blankets, the head being enveloped as well as the rest of the body. Nutrient enemata containing brandy should be administered every four hours from the first, alternating, if the patient's condition seems to require them, with hypodermic injections of strychnia; the strychnia and brandy should be gradually left off in the course of a few days as the patient's condition allows. Early stimulation and feeding are of the greatest importance in the post-operative treatment of these cases.

In conclusion, I may perhaps be permitted shortly to sum up the points that I am especially desirous to emphasise. In a certain not inconsiderable number of patients who have fibro-myomata of the uterus of only moderate size, serious organic disease of the heart is present. Sometimes the cardiac affection has been present before the fibroid began to grow, in which cases the heart symptoms are apt to be made worse. In a larger number of cases the heart disease is secondary to the growth of the uterine tumour, and arises in one of two ways; either the tumour may lead to menorrhagia and so to anæmia and malnutrition of the heart, or hypertrophy of the heart may at first be set up in a way that we do not at present understand. In either case the ultimate result is dilatation of the cavities and fibroid and fatty degeneration of the walls of the heart.

Disease of the heart, when present in any given case of uterine fibroid, is a serious complication, and may form

an important or even urgent indication for operative interference. When an operation is undertaken special precautions are required in order to avoid, as far as possible, the occurrence of severe shock and of subsequent heart failure. After the removal of the uterine tumour has been successfully carried out the heart affection tends to improve, and the organ may recover its tone to a really remarkable degree.

Finally, I have to express my deep sense of obligation to my two colleagues, Drs. Malins and Short; to the former for having with characteristic kindness allowed me to take into the General Hospital and keep under my own care several of the cases with which I have here dealt; and to Dr. Short for giving me the benefit of his valuable opinion on the condition of the heart in several of the patients.

Case 2. *Large multinodular fibro-myoma of the uterus, the largest nodule interstitial; duration of symptoms two years; cardiac hypertrophy; extra-peritoneal hysterectomy; collapse on the twenty-sixth day; recovery.*—S. H—, aged 39, married seven years, never pregnant, had been suffering severely from the effects of a large abdominal fibroid for two years. The patient was well nourished and not anæmic; there had been excessive loss at the periods. She was admitted to the General Hospital on June 18th, 1895, and the following note on the condition of the heart was taken on the 19th. The impulse is heaving; percussion dulness is increased to the left; the first sound is rather weak, but there is no murmur.

On the 20th the uterine tumour was removed by the abdominal method with extra-peritoneal treatment of the pedicle. The portion removed weighed 3 lbs. 11 oz., and consisted chiefly of one large interstitial fibroid; there were also several subperitoneal tumours the size of pigeon's eggs.

The remains of the stump were cut away on the

twenty-fourth day, and everything went well until then, and for two days longer. On the twenty-sixth day after operation the patient was seized with pain in the left groin, with vomiting and severe collapse, the temperature sinking to 96°, and the pulse becoming almost uncountable. With very free stimulation the patient rallied, and in two or three days was quite well again. She was discharged well on August 3rd.

This patient was again seen on November 8th, 1898, when she was looking very well and had gained much flesh. The operation scar was flat, the stump of the uterus, about the size of a small hen's egg, freely moveable in the pelvis. The vulva was large, but pale and smooth; the vagina and vaginal cervix were atrophied. The cardiac impulse is felt, normal and not heaving, just inside the nipple line; the first sound is a little short, but there is no murmur; the second sound at the base is accentuated. There are frequent flushes of heat and palpitations, causing sensations of exhaustion; there have been "dreadful shakings;" and burning and smarting sensations all over the abdomen have been present; but all these symptoms are now getting decidedly better.

Case 3. *Cervical fibro-myoma invading the right broad ligament; dilatation of the heart; vaginal hysterectomy; cardiac failure after operation; right femoral thrombosis beginning on the ninth day; recovery.*—F. C—, a pale yellowish, anæmic, well-nourished married woman, aged 40, was sent to me on December 4th, 1896, by Dr. Wood, of Bourton-on-the-Water. The patient had had four children, the last ten years, and one miscarriage four years, previously. There had been menorrhagia for eighteen months, and an attack of retention of urine, lasting a fortnight, six weeks before coming to me. An œdematous fibro-myoma the size of a child's head, which had grown outwards into the base of the right broad ligament, was removed by vaginal hysterectomy on December 8th.

In February, 1896, this patient had loss of power and sensation in the right arm and hand, with stiffness of the right side of the neck, and impaired hearing on the same side. These symptoms completely disappeared in about three weeks, and were possibly due to an attack of cerebral thrombosis.

Before operation it was noted that the heart's impulse was diffused, and extended outwards to three quarters of an inch beyond the left nipple line; it was best felt at about the level of the nipple. Dulness extended to the left to half an inch outside the nipple line, and upwards to the third costal cartilage. The first sound was reduplicated; there was no murmur, but the sounds were not quite clear.

Recovery was complicated by an attack of right femoral phlebitis beginning on the ninth day, probably connected with some purulent offensive discharge from the vagina, that had begun two days previously. The heart was examined on December 10th by Dr. Short, who concluded that there was dilatation with some leakage through the mitral valve, probably due to enlargement of the mitral ring from weak muscular action. There was a soft systolic murmur heard at the apex, not conducted especially in any direction; and a somewhat harsh murmur was heard over the left base. The cardiac dulness was increased to the left, and the apex was half an inch outside the normal position. The pulse was 104°, of fair quality and regular.

From December 8th injections of Liquor Strychniæ, four minims every four hours, were given till the 12th, and then three times a day till the 18th. For the first twenty-four hours after operation enemata of salt solution, eight ounces every four hours, were also administered.

Dr. Short again examined the heart on January 8th, 1897, when he reported that there now seems to be more dilatation of the heart than on the first examination, and the murmur is decidedly louder. The apex-beat is felt lower than before, and extends about half an inch outside the

nipple line; there is a fairly loud systolic murmur at the apex with occasionally a short presystolic murmur running up to the first sound. The heart is still regular and of slower beat; the pulse of better quality, 88 to the minute. On the same date there is a note that the patient has fainted on the last two evenings, the first occasions on which she has been got up. She is looking much better than on admission, although still pale and waxy; the thigh is quite well again.

On the 20th October, 1898, Mr. Wood was good enough to let me know that the patient's general health had rapidly improved after her return home, and that the signs of heart trouble had certainly decreased.

Case 4. *Large inflamed submucous fibro-myoma; degeneration of cardiac wall; total abdominal hysterectomy; cardiac failure after operation; thrombosis of the veins of the left leg beginning on the eighth day; recovery.*—A. M—, aged 41, a somewhat anæmic and sallow woman, who looked ill and said she had lost flesh, was first seen on August 13th, 1897. She had had four children, the last six years previously, and had been complaining of a lower abdominal tumour since the last labour; there had been profuse menorrhagia for one year. In the June previous to her first attendance there had been an attack of thrombosis in the veins of the left leg below the knee.

At the first attendance the patient was kindly examined by Dr. Short, who found that the heart was not dilated, but that there was evidence of fatty degeneration of the muscular wall. The action was regular, the first sound prolonged and murmurish, with occasionally a distinct, soft, systolic bruit. The second sound at the base was softer and fainter than normal. The ventricular contraction was prolonged, producing a tendency to spacing of the sounds. The pulse was quick and sharp, regular, and of fair tension.

On September 18th there was a systolic murmur

heard all over the cardiac area, best over the pulmonary cartilage.

A large abdominal fibroid extending upwards to one and a half inches above the umbilicus was removed by total abdominal hysterectomy on September 21st. The tumour was a large submucous fibro-myoma; the cut surface of a section showed a deep plum colour; the mucous membrane covering it had a similar colour and was eroded in parts. The inside of the uterine cavity had a distinctly disagreeable smell, but there was no collection of discharge and no pus. Ten-grain quinine suppositories were ordered to be given twice a day from the time of the operation; on the day after the operation brandy enemata and hypodermics of strychnia were ordered to alternate, each every four hours. The strychnia hypodermics were given three times a day after the 25th, and brandy was administered by the mouth from the 23rd until October 12th. An attack of thrombosis of the veins of the left calf began on the eighth day, previous to which the temperature had been normal. The temperature was raised irregularly until October 5th, after which it was again normal. The leg was much improved by October 19th, when the patient was sent to the Jaffray Hospital. During a stay of five weeks there the woman gained 21 lbs. in weight, and the leg further improved considerably. When seen after her return the heart's apex-beat was weak and diffused, and a soft systolic murmur was still present, but best heard now at the apex.

On April 5th, 1898, the patient was again seen looking well, and expressing herself as feeling perfectly well.

On November 25th, 1898, Dr. Short again examined this patient for me and found that she was not at all anæmic, and that there were no cardiac symptoms. The apex-beat was in the normal position, the first sound full and a little prolonged, but otherwise the cardiac sounds were normal. The pulse 80, was regular, of fair size, and not unduly compressible.

Case 5. *Submucous fibro-myoma; cardiac hypertrophy; total abdominal hysterectomy.*—S. J—, married, who had had two children, and had miscarried four years ago in the last of three pregnancies, had been complaining of profuse menorrhagia for two years before coming to seek advice on July 29th, 1898. There were anæmia, some wasting, and occasional swelling of the feet. A fibroid was causing retroversion of the uterus, and filling up the pelvic cavity.

On September 1st it was noted that the cardiac impulse was diffused and heaving; a double soft murmur accompanied the sounds at the base, and there was a soft systolic murmur at the apex.

On September 3rd the tumour, which was a submucous fibroid in the anterior wall, was removed by total abdominal hysterectomy after an attempt at vaginal removal had failed. Hypodermic injections of three minims of Liquor Strychniæ were ordered to be given every eight hours after the operation, and were continued for four days. One ounce of brandy was given by enema every six hours for four days after operation.

On September 19th it is noted that the apex-beat is seen over a considerably greater area than normal; the impulse feels diffused, and is slow and distinctly heaving and forcible; it extends outwards as far as the left nipple line, with a maximum in the fourth interspace just below and inside the nipple. Dulness extends upwards to the third costal cartilage, and to the nipple line to the left. The sounds at the base are muffled, but there is no murmur there or at the apex, where the first sound is weak and short.

Case 6. *Large multinodular interstitial fibro-myoma; cardiac dilatation; abdominal supra-vaginal hysterectomy.*—E. H—, a fat, anæmic, and somewhat sallow woman, aged 40, was first seen by me on December 28th, 1897, when there was an abdominal tumour extending up to the umbilicus. The patient had had two children, the last

seven years previously, and had been suffering from menorrhagia for six years. The heart was examined on several occasions, and on September 8th there is a note that the impulse is diffused and extends outwards to the nipple line; a systolic murmur is best heard over the pulmonary cartilage. The tumour at this date extended to one and a half inches above the umbilicus.

On September 10th, the uterus, containing a large multinodular fibroid in the right wall, was removed by abdominal hysterectomy with intra-peritoneal treatment of the cervical stump; the part removed weighed 3¼ lbs. Three hypodermic injections, each of four minims of strychnia solution, were given on the day of operation. There was some cough for a few days after operation.

On September 19th the cardiac impulse was diffused, and extended to three quarters of an inch outside the left nipple line; the impulse was weak and slapping. There was no murmur, but the sounds were somewhat weak. The patient made a good recovery.

Case 7. (Reported in detail in 'Lancet,' 1900, vol. i, p. 306.) *Numerous interstitial fibroids; signs of cardiac dilatation and degeneration; total abdominal hysterectomy; death on the tenth day from perforation of a latent duodenal ulcer; post-mortem examination; brown induration and fatty degeneration of the heart muscle.*—E. C—, a thin, spare widow of 42, who had had one child twenty-two years previously, and no other pregnancies, was first seen on December 14th, 1897, when she had had pain in the right lower abdomen and vaginal discharge for six months. The beginning of the present illness was marked by a profuse period lasting fourteen days and confining the patient to bed, and for the whole six months the periods have been very irregular, usually recurring about every three weeks, with varying, but not on the whole increased, flow. A firm multinodular fibroid of the uterus, the size of a fœtal head, occupied the hypogastric region and extended to within two inches of the umbilicus.

On the 25th October, 1898, the woman was rather thinner and paler than before, and the fibroid appeared to be about the same size. There had been no menorrhagia, but the yellow discharge had been more profuse, and the pain severe. The cardiac impulse was much diffused over an area extending to three quarters of an inch outside the left nipple, and about one and a half inches below it; the impulse was forcible and deliberate, but not distinctly heaving. A soft systolic murmur was heard all over the cardiac area, best at the lower end of the sternum and at the base, especially over the aortic cartilage. There have been palpitation and shortness of breath for about two years; previously the woman had been quite well, and she had never had rheumatic fever.

In April, 1899, the patient was obviously losing ground, and the fibroid had apparently somewhat increased in size. The cardiac sounds were more marked, the impulse being now more diffused and extending to an inch outside the nipple, and being also distinctly less forcible and more slapping in character.

The patient was admitted to the General Hospital on April 22nd, 1899, and on the 25th the tumour was removed by total abdominal hysterectomy. The operation was rendered difficult by old firm adhesions and disease of the appendages, and there was much collapse during its progress; hypodermic injections of strychnia, saline infusion under the skin of the axilla, and finally, intravenous transfusion of saline fluid, were all employed. The tumour removed weighed 2 lbs. 3 oz., and consisted of the uterus with numerous fibroids affecting its body, and of both sets of appendages. After the operation hypodermics of strychnia solution and saline enemata were ordered, and gradually left off as the patient's condition improved.

On May 1st it was noted that the apex-beat was in the fifth space in the vertical nipple line; the systolic murmur was softer in character, but still heard all over the cardiac area.

The condition of the patient gave rise to no anxiety till

the evening of the eighth day after operation, when a dose of castor oil was immediately followed by severe pain in the epigastrium and by rapid collapse, which ended fatally in sixteen hours.

At the autopsy, which was made by Dr. Stuart Macdonald, the sudden ending of the case was found to have been due to the perforation of a duodenal ulcer on the posterior wall of the duodenum. The process of repair at the seat of operation had gone on in a perfectly normal and satisfactory manner. The following notes were made upon the condition of the heart:

The pericardium contained about 2 drachms of clear fluid; there was a fair amount of pericardial fat; no adhesions were present. The right auricular appendix contained some small ante-mortem clots, the left was two inches long, and had a very small lumen in three quarters of its extent. There was a little atheroma of the aorta with some affection of the cusps of the valve, and small patches of atheroma surrounded the orifices of both coronary arteries. The openings of both the coronaries were rather patulous, the right especially so, and the latter was somewhat dilated throughout, but showed no atheroma. The aortic valve was competent; the cone diameter measured 0·9 in. The pulmonary valve was competent; the cusps healthy, the diameter 1·5 in. The mitral valve measured 1·28 in.; it showed evidence of slight chronic endocarditis at the base of the anterior cusp; the margins of both the cusps were slightly nodular; there were no vegetations. The tricuspid valve, similar in appearance to the mitral, measured 1·4 in. in diameter. The heart muscle was soft and flabby, and was uniformly brown in colour with a somewhat hyaline appearance; there was no obvious fatty degeneration. The left ventricle was 3¼ in. long, the right 4¼ in. The wall of the left ventricle was 1·4 cm. in thickness all over; that of the left auricle 0·6 cm.; that of the right ventricle 0·85 cm., and of the right auricle 0·5 cm. Under the microscope the heart muscle showed brown atrophy with slight fatty

degeneration of the fibres. The organ weighed 9¼ oz., and contained extensive post-mortem clots in all its cavities, and a few ante-mortem clots in the right ventricle.

Case 8. *Mitral stenosis twenty-five years; repeated attacks of pelvic peritonitis twenty-two years; multinodular fibro-myoma of the uterus one and a half years; cardiac symptoms much worse.*—M. K—, aged 40, had had one child twenty-two years ago, and no miscarriages; was married at seventeen, became a widow at thirty, and married for the second time at thirty-three. The patient had had very frequent and free losses of blood for one and a half years, and had felt a lump in the abdomen for one year, before being admitted to the General Hospital on September 27th, 1899. There had been heart symptoms, palpitation, and dyspnœa for eighteen years, but all these had been much worse in the last three or four months. There had been scarlet fever at thirteen, rheumatic fever at fifteen, inflammation of the lungs at thirty-five, and several attacks of pelvic inflammation since the birth of the only child. The patient's mother died of cancer of the breast at fifty, and one brother died of a tumour. The patient was a very anæmic and wasted woman of medium size. A multinodular fibroid of the uterus the size of a fœtal head extended two thirds of the way to the umbilicus, and there were, in addition, signs of adhesions and swelling of the appendages, especially of the left side.

The heart's apex-beat is seen and felt to be considerably diffused, and extends to one inch outside the nipple line in the fifth space. There is a long presystolic thrill. Percussion dulness extends upwards to the third rib, and outwards to one inch outside the nipple line. At the apex there is a long, rough, presystolic murmur, followed by a sharp first sound; on tracing the sounds outwards into the axilla the presystolic murmur becomes much shorter and a short, rough diastolic murmur makes its

appearance. At the base there is a soft systolic murmur, and reduplication and accentuation of the second sound, best heard over the pulmonary, and least over the aortic cartilage; the systolic murmur is well conducted downwards to the lower end of the sternum. The reduplication of the second sound is more marked at the middle of the cardiac area.

The patient was kept in bed for five weeks, at the end of which time the cardiac symptoms were decidedly better, the heart's action stronger and regular, and the presystolic murmur louder. Hysterectomy was offered but declined, and the patient was sent home on November 4th.

Case 9. *Large multinodular fibro-myoma, two years, the largest tumour interstitial; rheumatic fever ten years before operation; total abdominal hysterectomy; development of cardiac double murmur after operation.*—M. P—, aged 49, was sent to me to the General Hospital on August 4th, 1896, by Dr. Buxton, of Fazeley. The patient had been married twenty-three years; had one seven months' child born dead twelve years, and two miscarriages, the last eight years before her first visit to me. There was a history of rheumatic fever ten years previously. The abdomen had been getting large for two years, and there had been menorrhagia for one year. Examination of the heart after admission disclosed no abnormal physical signs. Total abdominal hysterectomy was performed on September 15th. The tumour removed weighed 10¼ lbs., and consisted of the uterus with its cavity 8 inches long, and its walls thickened by about twenty fibroids. The largest of these was in the posterior wall, and measured 8½ inches by 5 inches. On section it was found to have undergone gelatinous degeneration, the colour being greyish-white and translucent. Another tumour the size of a goose egg was degenerated in the same way, while another at the lower part of the large one was more opaque white. In addition to these there were about

twenty interstitial fibroids varying in size from a goose egg to that of a walnut.

On September 23rd the pulse had been frequent ever since the operation, the highest rate having been 120 a minute, eighty hours afterwards.

On the 24th the patient was seen by Dr. Short; the pulse was 114, the patient pale and waxy. Cardiac dulness was not increased, but there was a double rub, weak, and rather distant, all over the cardiac area, and a rough systolic murmur at the lower end of the sternum. The heart-sounds themselves were weak, and the action occasionally tumbling. After a careful examination of the chest it was concluded that this woman had probably had pericarditis during the attack of rheumatic fever ten years before, and that compensation had taken place. The cardiac wall had recently become weak, and the symptoms were due to this and not to recent pericardial mischief. The tongue was clean; the appetite had begun to return. Iron and strychnia were recommended every four hours. After this date the patient made a good recovery, sat up on October 8th, and went home on the 10th.

Case 10. *Fibro-myoma of the uterus more than fourteen years; mitral regurgitation; death with symptoms of inflammation of the fibro-myoma.*—M. W— first came under observation in the year 1890, when she had a tumour reaching upwards to one inch below the umbilicus. The woman had had three children and seven miscarriages, the last in 1883; she had begun to lose too much in 1881; had a tumour of the uterus removed through the vagina in 1882; and had first noticed an abdominal tumour in 1884. There was anæmia, and the heart signs were the same in 1890 as they were when the patient first came under my care in June, 1898, at the Workhouse Infirmary; in the interval the patient had been more or less continually under observation.

When I first saw her a rather soft fibroid extended upwards as far as the umbilicus; the cervix was free, and

Abstract of Cases.

I. *Affections of the heart caused by fibro-myoma of the uterus.*

No. of case.	Initials.	Age.	Nature, etc., of uterine tumour.	Symptoms of uterine tumour.	Duration of symptoms	Nature of cardiac affection.	Treatment of uterine tumour.	Result as regards cardiac affection.
1	A. H.	37	Multiple, interstitial, extending to a little above the umbilicus	Hæmorrhage; retention of urine	4½ yrs.	Degeneration	Double oöphorectomy	Slow but steady and marked improvement.
2	S. H.	39	Multiple; largest nodule interstitial 3 lbs. 11 oz.	Not anæmic; menorrhagia	2 yrs.	Hypertrophy	Extra-peritoneal hysterectomy	3 years later signs of hypertrophy had disappeared.
3	F. C.	40	Cervical fibroid invading right broad ligament = child's head	Menorrhagic; retention of urine	1½ yrs.	Dilatation	Vaginal hysterectomy	2 years later reported better.
4	A. M.	41	Inflamed submucous, extending to 1½ inches above the umbilicus	Anæmia; menorrhagia; wasting	6 yrs.	Degeneration	Total abdominal hysterectomy	Great improvement 1 year later.
5	S. J.	40	Submucous, size of fœtal head	Anæmia; menorrhagia; wasting	2 yrs.	Hypertrophy giving way to dilatation	Total abdominal hysterectomy	—
6	E. H.	40	Multiple, interstitial, 3¼ lbs.	Anæmia; menorrhagia	6 yrs.	Dilatation	Intra-peritoneal hysterectomy	—
7	E. C.	42	Multiple, interstitial, 2 lbs. 3 oz.	Wasting; slight anæmia	1 yr. 10 mos.	Dilatation and degeneration	Total abdominal hysterectomy	Died on 10th day from perforation of a latent duodenal ulcer. At autopsy dilatation of heart with fibroid and fatty degeneration.

II. *Fibro-myoma in patients already the subject of heart affections.*

8	M. K.	40	Multiple tumour size of fœtal head	Menorrhagia	1½ yrs.	Mitral stenosis 25 years	Medical	Symptoms much worse; improved after rest in bed.
9	M. P.	49	Multiple, interstitial, 10¼ lbs.	Menorrhagia for 1 year	2 yrs.	? Pericarditis 10 years before	Total abdominal hysterectomy	Temporary failure of compensation after operation.
10	M. W.	59	Tumour up to umbilicus	Menorrhagia; pain	14 yrs.	Mitral regurgitation of unknown duration	Medical	Died with symptoms of inflammation of the uterine tumour. No autopsy.

the os patulous; there was much pain, and the woman was never free for more than a few days at a time from a reddish discharge. There was some degree of anæmia, but the woman did not appear to be ill. The heart was regular, the apex-beat in the fourth interspace; there was a blowing apical systolic murmur, and the pulmonary second sound was accentuated. While I was away on my holiday the patient, who was getting about the ward in her usual state before I left on the 5th August, 1898, was seized with severe lower abdominal pain and diarrhœa on the 22nd of the month; great tenderness appeared over the tumour, and there was free bleeding from the vagina. The temperature rose to 100·8°. The diarrhœa ceased in about two days, but the lower abdominal tenderness persisted, and the patient rapidly became worse and died on the 27th, after six days' illness. The age at death was fifty-nine; a post-mortem examination was unfortunately refused.

References.

1. Dower. 'New York Med. Journ.,' vol. xxxix, 1884, p. 505.

2. Bedford Fenwick. "On Intra-abdominal Tumours as a Cause of Cardiac Degeneration," 'Brit. Gyn. Journ.,' vol. ii, May, 1887.

3. Hennig. 'Festsch. der Gesellsch. f. Geburts. u. Gynäk.,' 1894.

4. Pozzi. 'Gynæcology,' Syd. Soc. transl., vol. i, p. 294.

5. Strassmann and Lehmann. "Zur Pathologie der Myomerkrankung," 'Archiv für Gynäk.,' lvi, pt. 3.

6. Tuffier. 'Gaz. des Hôp. de Paris,' October 17th, 1893. Cited in 'Brit. Med. Journ.,' Epitome 31, i, 94.

The President commended Dr. Wilson for his scientific treatment of a subject handled too empirically at present. On the one hand Dr. Wallace, at Liverpool, refused ultimately to operate on any uterine fibroid which was not threatening life

on the other hand, some operators seemed over-eager to advance arguments in favour of the removal of fibroids which caused no symptoms. The President had frequently observed circulatory troubles, independently of anæmia, in patients with fibroid tumours. One, free from any sign of organic heart disease, was subject to attacks of syncope at every period (never very free) for two years. Three years ago he removed the tumour, as it was growing rapidly, and took away both ovaries. Since then no attacks of syncope had occurred. In the case of hysterectomy for suppurating fibroid, of which he spoke last year ('Transactions,' vol. xli, p. 212), the pulse was very intermittent before the operation. It had since become perfectly regular. In this instance one ovary was not removed. Chavannaz and Fieux, of Bordeaux,* recently reported another instructive case of irregular pulse becoming regular after panhysterectomy with removal of both ovaries. The patient had been subject to dysmenorrhœa all her life, and to pains, presumably due to a fibroid, for eight years. Fieux opened the very narrow cervix and applied a stem; temporary relief followed. A few months later Chavannaz did the panhysterectomy. Near the end of the operation the pulse stopped and the anæsthetic had to be suspended. The fibroid adhered strongly to the lower bowel. The President asked Dr. Wilson, in respect to these three cases, how far the ovaries played a share in causing disorders of circulation.

Dr. Amand Routh recalled a case which proved the serious action of ergot in the cases under discussion. He had elevated a large pelvic fibroid by hydrostatic pressure in a patient aged forty-six years. Her only symptoms had been due to pelvic pressure, and these were at once relieved. Her heart's action was feeble. Against his advice, she took ergotin pills, and soon became very weak and ill, and stated that within an hour of taking a dose she had pains over the cardiac area, with breathlessness and palpitation, and was quite unable to walk. She was seen by Sir William Broadbent, who stated that he found her arteries were very much tightened, and his previous experience of such cases enabled him to fix on the ergot as the cause of the heart trouble and of the pseudo-angina. The patient slowly improved when the drug was discontinued. Inasmuch as ergot was so generally given in cases of uterine fibroids, he thought it not unlikely that unsuspected cardiac debility in such cases would be aggravated by the drug, and would explain some of the cases of so-called asthenia, which were not infrequent.

Dr. Herbert Spencer considered the paper a very valuable contribution to the knowledge of the effect of uterine fibroids

* 'Revue mensuelle de Gynécologie, Obstétrique et Pædiatrie de Bordeaux,' March, 1900, p. 186.

on the organism. He thought that many of the symptoms of heart disease and the murmurs were due to the anæmia to which the fibroids gave rise by hæmorrhages. Anæmia thus caused was an urgent indication for operation, especially in young subjects. It was remarkable how rapidly in some cases the symptoms disappeared and health was restored, even after removal of the ovaries only, the tumour remaining. He doubted whether fibroids often gave rise to hypertrophy of the heart; in pregnancy the heart was very frequently not hypertrophied.

Dr. Blacker thought that there were considerable difficulties in determining the causal relationship between a fibroid tumour and organic heart disease. He would like to know upon what number of cases of fibroid tumour Dr. Wilson based his experience. At the present day, when influenza was so common and so often followed by cardiac mischief, the previous histories of the cases described in the paper were of the greatest importance, since without a very complete previous history it would be difficult in any given instance, apart from cases of grave anæmia, to say that a dilated heart was due to the presence of a fibroid tumour. He also wished to ask why Dr. Wilson thought that the presence of cardiac hypertrophy with a fibroid tumour was an indication for operation.

Dr. Heywood Smith, in reference to what Dr. Spencer had said as to hypertrophy and dilatation of the heart being probably due to the anæmia produced by the loss of blood, contended that it was more probably due to the heart having to overcome increased resistance caused by the extended area of circulation produced by the tumour, as well as the resistance through a tissue so unyielding as a fibrous tumour. In confirmation of this proposition he stated that Dr. Bedford Fenwick, some years ago, called attention to the fact that a similar hypertrophy and dilatation of the heart was to be observed in many cases of large ovarian cysts, where a large increased area was added to the circulation, giving a greater stress of work to the heart.

Dr. Thomas Wilson, in reply, said that in the cases recorded in the paper the presence of fibroid tumours appeared to be the only probable exciting cause of the cardiac condition. In none of the patients was there a history of influenza or other of the common causes of derangement of the heart's action or nutrition; none of the patients were neurotic in the sense in which this term is generally applied. In many of the cases chronic anæmia seemed to be an important factor; but in several of the cases there was no anæmia. With regard to the relative frequency of heart affections in cases of fibroids Dr. Wilson was not in a position to give statistics at present.

JUNE 6TH, 1900.

ALBAN DORAN, F.R.C.S., President, in the Chair.

Books were presented by Mr. Bland-Sutton, Drs. Giles, Jacobi, Minot, Cristalli, and Lieut.-Colonel Sturmer, I.M.S.

The following gentlemen were proposed for election: —Jameson John Macan, M.A., M.D.Cantab.; Ralph Henry Vincent, M.B., B.S. (Dunedin); George Mansell Dawkin, M.R.C.S., L.R.C.P.Lond., and Horatio White Abbott, M.R.C.S.Eng., L.R.C.P.Lond.

Report on Dr. Stabb's specimen of Myxo-fibroma (? Sarcoma) of Uterus. (*See p.* 133.)

We, the undersigned, have met this day, and, after examining the specimen named above, have drawn up and signed the following Report:

Having examined a series of microscopic specimens, taken from different parts of the tumour, we are of opinion that it is a fibro-myoma which has undergone extensive myxomatous degeneration. There are many clusters of small cells or nuclei scattered through the sections, but there is no clear evidence that these are of a sarcomatous nature.

WILLIAM DUNCAN.
T. W. EDEN.
G. DRUMMOND ROBINSON.
A. F. STABB.

SQUAMOUS-CELLED EPITHELIOMA OF THE CERVIX UTERI IN A VERY EARLY STAGE.

Shown by W. S. A. Griffith, M.D.

SQUAMOUS-CELLED EPITHELIOMA INVADING SURROUNDING TISSUES LIKE A COLUMNAR-CELLED VARIETY.

Shown by W. S. A. Griffith, M.D.

SARCOMA OF THE UTERUS, WITH A MICROSCOPIC SECTION.

Shown by H. R. Andrews, M.D., B.S.

Dr. H. R. Andrews showed a specimen of sarcoma of the uterus, with a microscopic section. The patient, an unmarried woman of thirty-three, was apparently quite well until eight months ago. She then began to have excessive losses at her menstrual periods. Four months ago a tumour was found in the abdomen. For the last two months, before she came to the London Hospital, the bleeding was practically continuous. She complained of a good deal of abdominal pain.

A hard rounded tumour, regular except for one well-marked nodule at the upper part, was found rising out of the pelvis reaching up to the umbilicus.

An attempt was made to remove the uterus by abdominal hysterectomy, but found to be impossible, owing to the fact that the right broad ligament was infiltrated by the growth, which was evidently malignant.

The patient died and the uterus was removed post mortem.

A large growth was found in the anterior wall of the uterus, which was three inches thick. The uterus weighed 3½ lbs. The endometrium was unaffected. Sections showed the tumour to be a sarcoma. Masses of small round cells, arranged in a more or less alveolar manner, were seen to be infiltrating the uterine muscle. Round the margins of the alveoli were spindle-cells. There were very numerous ill-developed blood-vessels in the growth.

No secondary deposits were found, but only a partial autopsy was allowed.

Dr. Andrews was indebted to Dr. Herman for the specimen.

CYSTIC FIBRO-MYOMA OF THE CERVIX UTERI.

Shown by Dr. Roberts.

Dr. Roberts showed a specimen of cystic fibro-myoma of the cervix uteri (No. 2960*b* St. Bartholomew's Hospital Museum), which was removed post mortem from the body of a woman aged thirty-four, who was admitted to the hospital for difficulty in micturition and defæcation of two years' duration. A rounded mass was felt in the abdomen reaching to the level of the umbilicus, and continuous with a hard, fixed, nodular tumour, which was discovered *per vaginam* to occupy the whole pelvic cavity, and extend on to the perinæum. Laparotomy was performed without any successful result; the patient died of peritonitis. Post mortem the tumour was found to be in a condition of suppuration. This occurred in 1894. The tumour is a large cystic fibro-adenoma of the cervix; it resembles in all particulars an ordinary cervical fibroid, the body of the uterus being perched on the summit of the ovoid tumour below, which projected

into the dilated upper part of the vagina. The tumour is dense and fibrous. Scattered through its substance are a large number of cysts, varying from the size of a marble to that of a pea; some contain mucoid material, some altered blood, and some a cheesy, purulent substance.

In the neighbourhood of the internal os the tumour is breaking down, and the cavity of the uterus is lined by ragged sloughing tissue.

Sections of the growth (shown) prove the tumour to be a cystic fibro-adenoma; each of the centres is lined with a single layer of columnar epithelium resembling the glands of the cervix.

Dr. Roberts showed this specimen and a section of another cystic adenoma of the cervix (2960*a*, St. Bartholomew's Hospital Museum) which grew on the anterior lip, forming an oval tumour which protruded through the vulva of a woman of thirty-two. The tumour measured 2½ inches, it was spongy in section and contained mucus in cystic centres which on section were found to be lined with a single layer of columnar epithelium (section only, shown on June 6th).

Dr. Roberts thought these specimens of some interest in connection with much that had been brought forward lately before the Society with regard to adenoma of the uterus. At the last meeting Dr. Roberts had shown a specimen of adenoma of the body of the uterus with cancer of the cervix.

It was also of some interest in relation to the so-called cystic fibroids. Dr. Roberts had examined a considerable number of cystic fibroids, but had not met with a single case, except the one quoted above, where any trace of epithelium could be found lining the spaces in such tumours, which Dr. Roberts regarded as due to necrosis and degeneration.

In the cystic fibroid of the cervix it was probable that the spaces lined with definite columnar epithelium took their origin from cervical glands.

A CASE OF EXTRA-UTERINE GESTATION IN WHICH FŒTAL DEATH OCCURRED AT THE EIGHTH MONTH AFTER SPURIOUS LABOUR; ABDOMINAL SECTION TWO MONTHS LATER.

By Alban Doran, F.R.C.S.
SURGEON TO THE SAMARITAN FREE HOSPITAL.

(Received March 15th, 1900.)

(*Abstract.*)

The patient, aged 34, became pregnant for the fifth time, after an interval of four years, in February, 1899. Abdominal pains occurred early, diarrhœa caused trouble from July to the end of October, when labour pains and hæmorrhage set in, followed by septic symptoms. The outline of a fœtus could plainly be felt through the parietes. On December 12th it was removed by abdominal section. It was very fœtid, and had developed in the posterior layer of the right broad ligament. The sac was packed with gauze for a few days and then drained; the placenta came away in fragments. A fæcal fistula developed and discharged for a few weeks. For six weeks the patient did very well, then symptoms of chronic obstruction with great emaciation set in, and she died in the ninth week after operation, flatus passing to the last. Several coils of small intestine had been dragged upon by the contraction of the sac; the adhesions involved several surfaces of mesentery, which seemed to account for the emaciation, strongly marked in this case where there was but little vomiting or distension.

The author dwells on the infection of the sac, especially common in posterior tubo-ligamentary pregnancy (Taylor), on the diarrhœa observed when placenta is attached to intestine

(Freund), and on the inanition caused by the changes noted in this case. As there is no true sac-wall inferiorly in this form of ectopic gestation, complete extirpation of the sac seems hardly possible. He dwells on Dunning's case and on those collected by Jayle and Delherm, and expresses doubts as to the precise anatomical character of the sac in some of those cases. Finally, the author agrees with Taylor in preferring to pack and drain the sac, but does not know of any method of dressing which can obviate the dangers which follow the contraction of the sac-wall.

This case is of interest in relation to several others which have been recently published. The patient, almost moribund from septic absorption, was for six weeks restored to relative health by the removal of the fœtus with draining of the sac. Unfortunately the walls of the sac, which were developed from the posterior layer of the broad ligament, were contracted so as to drag upon several coils of adherent small intestine. This complication interfered so greatly with nutrition that the patient died in the ninth week after operation.

I will begin by relating the history of the case and the operation.

E. P—, aged 34, married fourteen years, was admitted into the Samaritan Hospital, under my care, on December 5th, 1899.

Dr. Walter Tate, to whom the patient had applied at the out-patient department, kindly furnished me with the following clinical history:—She had borne five children, all females, the eldest thirteen, the youngest four years of age, and had never miscarried. The last period occurred in February, 1899. A month or two later she found that she was evidently pregnant, and pains were felt all over the abdomen from the first. At the fifth month coloured water dripped away from the vagina for three weeks. Several sharp attacks resembling labour pains occurred in summer, and forced her on each occasion to keep to her bed for over a week. Diarrhœa set

in during July, and thenceforward the bowels were always relaxed.

At the end of October unusually severe pains set in, just like labour, with considerable flow of blood (which continued till the operation). Then she became very ill and feverish, losing flesh steadily. Dr. Tate examined her, and detected a fœtal outline through the abdominal walls.

On admission the patient was much emaciated, the eyes bright, the skin dry and rough, the tongue very raw, the temperature 100·6°, the pulse 120, the urine deep orange in colour, clear; specific gravity 1017, and distinct trace of albumen.

The abdominal walls were very thin. There was a brown pigmented line, which ran not only from the umbilicus to the pubes, but also from the ensiform cartilage to the umbilicus—which it curved round to the right—and was continued downwards. The patient was dark-complexioned. An oval swelling filled the front of the abdomen almost to the ribs. It was resonant all over on percussion; on palpation a crackling sensation was felt. The outline of a fœtus could be easily detected; the head lay uppermost, to the left above the umbilicus.

I endeavoured to improve the patient's condition by rest and good feeding for a few days, but she grew worse; the pulse remained high, the night temperature exceeding 101°. On December 11th she was drowsy and very feeble. On December 12th I operated, with the assistance of Mr. Butler-Smythe. The incision in the middle line exposed a cystic cavity with a thick, very soft wall of deep red colour. Intensely fœtid gas, vernix caseosa, and shreds of fœtal membrane escaped. I enlarged the incision to above the umbilicus, and drew out the fœtus by the legs, which lay lowest. During extraction the head, though very soft, tore the upper limit of the cyst wall, exposing an omental adhesion and the upper part of the peritoneal cavity. The cyst extended into the right iliac fossa and into the pelvis. I washed it out with saline solution, with 1 in 40 boracic solution, and with

iodine water, one ounce to the pint. The placenta lay in the lower part of the cyst, chiefly to the right. The umbilical cord was so rotten that during extraction it came off close to its placental attachment.

The cyst wall was very soft, but closely incorporated with important adjacent structures. The patient was already much exhausted. Had I succeeded in dissecting away the cyst—a practically impossible task, as the sequel proved,—and returned her alive to her bed, general septic infection must have rapidly set in. I therefore closed the rent in the upper part of the cyst with a fine silk suture, packed the cyst cavity with iodoform gauze, and made a purse-string suture, including its cut edge. I drained the peritoneum at the upper angle of the wound, above the rent in the cyst, with a strip of gauze, which was removed on the second day. This precaution proved hardly necessary, as the general peritoneal cavity was really cut off at this point by adhesions of adjacent coils of intestine.

The fœtus was a female, extremely fœtid and decomposed. The skin was dead white, much macerated, and it had disappeared from the right side.

Weight (after lying twenty-four hours, first in carbolic acid, then in acid) was 3½ lbs. The length from neck to extended left heel was 18 inches. The left side presented, breech lowest, head bent on thorax, and greatly flattened laterally, the occipital protuberance lying uppermost. Parietals overlap. Features normal, but flattened. Thighs and humeri strongly flexed on trunk.

No spina bifida; no cleft in the middle line of thorax and abdomen. Funis softened by decomposition: now hardened through spirit. Two inches of funis remain on fœtus; it tore away during extraction. Vulva well developed; hymen distinct, with wide orifice. Anus pendulous; admits bougie 1½ inches.

The skin has disappeared through maceration from the right side of the trunk. The ninth and tenth ribs appear necrosed, projecting through the exposed muscular

layers, black, and denuded of their periosteum. The other ribs, invested with their periosteum, appear normal.

After a few hours of severe shock the patient's condition rapidly improved. The pain, nausea, and general discomfort, from which she had not been free for months, disappeared entirely.

On the second day I removed the iodoform gauze from the cavity of the cyst; it was very fœtid. The cavity was washed out with antiseptics. Chinosol (strength 15 gr. to the pint) proved to be the best agent for the purpose. On the third day the gauze was removed from the upper part of the wound. Flatus passed well. Sloughy placenta began to come away in small fragments. For several days the patient suffered from occasional sickness, and grew weak and sallow. On the sixth day the bowels were opened twice. On the seventh a large handful of placenta came away. The cavity was filled with chinosol solution (15 grains to the pint, as used daily). The fluid did not ebb, but some bubbles rose up in it. On the eighth day some fæces came out of the wound; a fæcal fistula had thus developed. It discharged till January 24th, 1900, in the seventh week after the operation, and three weeks before the patient's death on February 15th.

During the second week occasional attacks of sickness occurred. On January 8th, at the beginning of the fifth week, a large ragged mass, three inches by one inch, came away as the cavity was being washed out. Fearing that this piece of placenta might include a portion of intestinal wall, I sent it to Mr. Shattock, who found that it was typical placental tissue, with no evidence of any fragment of intestine. It had remained attached for nearly three weeks longer than the remainder of the placenta. At this time the cavity was washed through the rectum with saline solution every morning, and it had greatly shrunken. But the chinosol solution, as on the first day that the fæcal fistula was detected, did not ebb into the rectum when poured into the cavity, though, as from the first,

bubbles of flatus rose up. The fistula, which could not be detected after death, must have been valvular. The patient slept and fed very well at this time; indeed, she was a good sleeper to the last.

On January 24th, after the completion of the sixth week, solid fæces still came away from the rectum, and some soft fæces from the wound; but from that day no motion could be made to pass. Flatus passed to the last, and several coils of small intestine rose up daily, and disappeared slowly, to rise again in a few hours. The patient was sick once or twice daily, the vomit mucous or bilious, never "coffee-ground" or fæcal. Marasmus came on rapidly.

I held several consultations with my colleagues, and we agreed that an exploratory operation was not advisable, as the clinical symptoms pointed to mal-assimilation from the dragging of extensive adhesions rather than to well-localised mechanical obstruction. The probability of spontaneous disappearance of the obstruction, though very small, was greater than the chance of doing any good by operation. The post-mortem evidence showed that the obstruction could hardly have been rectified, or even accurately diagnosed, through an abdominal incision. I meditated an enterostomy as a palliative measure, so as to drain the distended small intestine, with a view to some more radical intestinal surgery when the patient had grown stronger. But she was extremely weak; and my experience of enterostomy in chronic obstruction on a much-enfeebled subject is that it ensures a few days' comfort, followed by euthanasia, but seldom, if ever, has the patient grown strong enough to bear a plastic intestinal operation. In certain forms of acute obstruction enterostomy is, no doubt, serviceable.

The patient died on February 15th; the flatus had passed within five hours of her death.

Post-mortem appearances.—Dr. Bosanquet made the necropsy about twenty-four hours after death.

The body was extremely emaciated. The heart weighed

only 5 oz., the liver 2 lbs. 3½ oz., the spleen 2 oz., the right kidney 2 oz., the left 2½ oz.

Several coils of distended small intestine were firmly adherent to the posterior and superior part of the sac. The large intestine was much contracted, but contained a considerable amount of soft fæces. The ileum was quite empty and greatly contracted at the ileo-cæcal valve, and for three or four inches upwards till it was traced to the back of the sac, with which it was closely incorporated.

The rectum, when laid open from below, seemed completely closed at the point where it touched the sac, which was six inches from the anus. The upper end of the rectum also seemed completely closed at its junction with the sac. The parts were sent to Mr. Shattock for further examination at the College of Surgeons.

After careful dissection it was found that the uterus, three inches long and rather thick, bounded the greater part of the anterior aspect of the sac. The left tube and ovary were detected on dissecting from the front, that is to say, through the layers of the left broad ligament. The anterior wall of the right broad ligament formed the anterior wall of the sac to the right, and no trace of tube or ovary could be detected. The back of the sac was closely incorporated with the aorta, just at its bifurcation, by dense cellular tissue. The rectum was closely connected with the sac, and its calibre contracted so as to become too narrow to admit the little finger. The mucous membrane was deeply congested and puckered for three inches, corresponding to the area of adhesion. No communication could be found between the rectum and the cavity of the sac, nor between the sac and any other part of the intestinal canal.

The last four inches of the ileum were much contracted, not admitting the little finger. But water could be made to pass along it from the upper bowel in small quantity. This portion of intestine was closely adherent to the back of the sac and to the mesentery of the intes-

tine above it, and several coils of intestine higher up were also adherent, obstructing each other by kinking and by firm adhesion to adjacent mesentery.

The sac had a true wall, though incomplete—a matter on which I shall dwell presently—and much altered by pathological changes; this wall was not made up of coils of intestine covered with lymph. The lining of the sac seemed sloughy; it invested anteriorly the back of the uterus and the back of the anterior layer of the right broad ligament, of which ligament it evidently formed a part. Posteriorly, where the true wall was deficient, the lining of the sac—a mere inflammatory deposit—invested the aorta and iliacs and the upper part of the rectum. The cavity had greatly contracted, so that its upper part lay almost as low as the fundus of the uterus. Douglas's pouch had been completely lifted up on the right, but to the left it was represented by a shallow pouch containing the left ovary and tube, and bounded in front by the posterior surface of the left half of the uterus. The bladder adhered firmly to the front of the uterus, but the utero-vesical fold existed.

The absence of all trace of communication between the canal of the intestine and the sac was remarkable, as fæces had passed so freely through the sac for six weeks. The fistula must have been low down, as saline enemata came out through the wound almost directly; I suspect that the fistula had closed up during the last three weeks of her life and the whole bowel had become contracted and puckered at its side.

Tubo-ligamentary pregnancy. — In making comments on this case and others like it, I will, for the sake of convenience, make use of the terms introduced by Taylor.* He believes that nearly all ectopic gestations are originally tubal, and most of us are of the same opinion. The other familiar forms are held by him to be secondary to tubal gestation, hence he terms them tubo-uterine (or

* 'Extra-uterine Pregnancy: a Clinical and Operative Study,' 1899.

"interstitial") gestation, tubo-abdominal (or "abdominal"), and tubo-ligamentary ("sub-peritoneo-pelvic," "extra-peritoneal" or "broad ligament") gestation.

With tubo-uterine gestation we have evidently nothing to do. Nor was this case an instance of tubo-abdominal pregnancy called "abdominal." At the operation a distinct wall was detected; in tubo-abdominal pregnancy there is no true wall. The surgery of the two forms, tubo-abdominal and tubo-ligamentary, is therefore different. Tait and Bland-Sutton maintained that tubo-abdominal is a tertiary not a secondary condition. The primary tubal sac, they believed, bursts into the broad ligament, the consequent broad-ligament sac bursts into the peritoneal cavity and manages to develop there. Taylor, however, holds on clinical evidence that this tertiary form is exceptional. Tubo-abdominal pregnancy is as a rule secondary; a tubal sac bursts at a point in its wall where there is no placenta; the fœtus is extruded into the peritoneal cavity without any disturbance of the placenta, which remains attached to the tube; hence the fœtus develops without hindrance. Tait overlooked this explanation of the phenomenon through his well-known conviction that rupture of the tubal sac into the peritoneal cavity necessarily killed the fœtus, and almost as surely killed the woman, by hæmorrhage. In tubo-abdominal pregnancy the fœtus is always above the placenta.

This case is undoubtedly an example of tubo-ligamentary pregnancy, and of the posterior variety. The anterior variety, where the anterior layer of broad ligament and then some of the parietal peritoneum is lifted up, makes the sac entirely pre-peritoneal, as Hart, Barbour, and Carter have shown. Hence in this variety there is little fear of infection of the sac or fæcal fistula after operation, for the sac-wall is far from intestine.

In the posterior variety, including this case, the posterior layer of broad ligament, and then some of the peritoneum as high as the promontory of the sacrum, is

heaved up. The sigmoid meso-colon is often involved. The sac is therefore entirely retro-peritoneal ; its wall of thickened peritoneum being deficient below, so that the ovum and membranes come into close relation with the lower bowel. Hence the sac is often infected, and fæcal fistula is frequent after operation.

I may here remind the Society of the instructive diagram in Dr. Walter Griffith's communication read in April, 1891.* Death occurred at the fourth month, so that the parts and relations were easier to demonstrate than in my case, which, like Dr. Griffith's, was posterior tubo-ligamentary and in the right broad ligament. "The peritoneum of the posterior surface of the right broad ligament passed directly from the right posterior border of the uterus to the middle of the anterior surface of the rectum." In my own case the same piece of peritoneum had become stretched upwards so as to form a cyst-wall, which pressed forwards against the parietal peritoneum. In my case, as in Griffith's, there remained on the left of the uterus a shallow pouch containing the ovary ; it was the last remnant of Douglas's pouch.

I will now dwell on certain clinical features noteworthy in my own case, namely the infection of the sac, the diarrhœa, and the nature of the obstruction.

Infection of the sac.—The putrid condition of the fœtus and the great accumulation of fœtid gases in the sac were marked features in this case. Freund, in a treatise to which I shall again refer, indicated that when the ovum in advanced ectopic gestation dies, putrid infection often takes place from germs in the diseased bowel, which can readily penetrate the thin walls of the placental vessels. He speaks specially of cases where the placenta has become partly attached to intestinal wall. General infection sometimes follows, as in two of his cases, and also in my own, where the

* "A Case of Extra-uterine Gestation, the Sac being situated in the Right Broad Ligament, Pregnancy advanced to the early part of the fourth month," 'Trans. Obst. Soc.,' vol. xxxiii, p. 126, drawing, p. 129.

patient became both emaciated and septic. In Dr. Phillips's case, read before the March meeting this year, the pregnancy was of the abdominal type, the cyst had become infected and contained fœtid gas. Luckily general infection did not occur.

In my own case the pregnancy was posterior tubo-ligamentary. Infection of the sac is specially probable in this variety, on account of its intimate relations with the rectum. Taylor has developed Freund's earlier researches, the former finding that late posterior tubo-ligamentary pregnancy may be termed the decomposing, septic, or putrid type of ectopic gestation. Quiescence and lithopædion are more common in the tubo-abdominal and anterior tubo-ligamentary varieties; when infection does occur there seems less chance of general sepsis, possibly because the sac may more readily cut itself off by inflammatory adhesions from the source of infection than it can in the posterior tubo-ligamentary type, where the rectum is practically part of the sac-wall and remains a constant source of infection. The above remarks will turn our attention to an allied clinical subject.

Diarrhœa in late stages of ectopic gestation.—The obstinate diarrhœa which troubled the patient for nearly four months before the symptoms of spurious labour is worth consideration. Freund dwelt on this symptom over seventeen years ago.* He attributed it to attachment of placenta to intestine, and consequent abnormal vascularity of the intestinal walls. As a result catarrh is set up, an effect which necessarily increases as term grows nearer. In a true tubo-abdominal pregnancy, when part of the maternal surface of the placenta extends by growth over the uterus and pelvic wall, and not rarely over adjacent intestine, intestinal catarrh is always probable, though I am not certain that the complication has often been noted since Freund published

* "Extra-uterine Gestation," by Professor Freund. Read by Dr. David Smart before the Edinburgh Obstetrical Society ('Edinburgh Medical Journal,' vol. xxix, 1883–4, p. 526).

his observations. In my own case the sac was posterior tubo-ligamentary. The child, as Taylor has shown us, must be below the placenta when it is first expelled from the tube into the broad ligament, but as the pregnancy advances the child passes high up into the abdomen behind the placenta. At the same time the placenta grows rapidly beyond its original limits in the ruptured tube, extending over the greater part of the lower portion of the sac. But that portion is entirely behind and below the peritoneum, nor is there any true sac-wall, the posterior boundary consisting in part of the rectum itself. The placenta certainly invaded the rectal wall in my own case.

Nature of the intestinal obstruction.—There remains a third matter of clinical and pathological interest, the nature of the obstruction, which in this case starved the patient, instead of causing her death after the manner usual in more acute forms. It is true that there was very distinct kinking at several points. It is true that the kinking was caused by the dragging of the contracted sac on the adherent coils of intestine. Yet flatus, at least, passed to the last. Death was mainly brought about through slow starvation caused by the firm adhesions of several large areas of mesentery which were also dragged upon by the sac. This condition greatly impeded the absorption of chyle.

Operative treatment of tubo-ligamentary pregnancy.—The best operative treatment is, after all, the most important question in relation to a case like that which I now relate. I saved the patient from rapidly falling a victim to sepsis. Before the extraction of the fœtus the temperature was high; afterwards it remained almost normal. But the contraction of the sac caused fatal results. This raises two questions:—Should the sac have been dissected away? If that was impossible, how could its dragging upon adherent intestine have been prevented? The first question must, I think, be answered

in the negative. It is as to the second that I particularly desire your opinion.

To dissect away the sac is an impossibility in late posterior tubo-ligamentary pregnancy for reasons which I have already made apparent. The inferior part of the sac has no true wall, and includes the anterior aspect of the rectum. The upper part has, indeed, a wall, often thick, but always very closely adherent to important structures. In any case the sac wall was very fœtid; it was opened and drained and soon ceased to be so. Had I dissected it away at the operation, or tried to do so, the patient would have possibly died on the table, and if not would almost certainly have perished from septic peritonitis or pure septicæmia within a few days. Dunning, as Taylor points out, did extirpate the sac, but had to complete his operation by removal of the uterus.

From Dunning's original report * I find that, as in my case, his was undoubtedly "posterior tubo-ligamentary." He avowedly coins the term "intra-ligamentous retro-peritoneal ectopic pregnancy," which Taylor has simplified. He strongly urges enucleation of the sac.

Let us remember Dunning's own words. He and his assistant, Dr. Patton, "dealt with it as we do with an intra-ligamentous cyst, viz. we encircled the upper portion of the mass by an incision extending only through the serous investment, peeled down this investment, and proceeded to enucleate the fœtal sac. *It was not a difficult task.* There was not found any distinct pedicle, but a large artery entered the sac from below. This was ligatured and severed. Several smaller arteries were also ligatured." The peritoneum, it was found, had been stripped off the back of the uterus, which bled freely in consequence, so the uterus was removed by Baer's operation. This was undoubtedly good surgery under the circumstances.

From the above description it is evident that Dunning's

* "Ectopic Gestation: a Consideration of the Intra-ligamentous Retro-peritoneal Form," 'Amer. Journ. Obstet,' vol. xxxvi, 1897, p. 43.

case differed from mine in respect to the condition of the sac. There is no evidence in his report of general septic infection. The contents of the sac, beside the placenta, are described as "a quart of dark-coloured fluid," not stated to be fœtid. The enucleation of the lower part of the sac was "not a difficult task." In my own case, as I have explained, it would have been impossible, as there was no true cyst wall. Indeed, I cannot see how a sac of this kind can be enucleated in the strict sense of the word. Again, in my case the back of the sac higher up proved to be closely incorporated with the aorta at its bifurcation. Under such conditions Dunning's method becomes impossible.

Jayle and Delherm have recently collected a valuable series of clinical reports of operations for extra-uterine pregnancy, including twelve where gestation was intra-ligamentary.* Some of the original reporters, however, do not seem to have been quite precise in their ideas as to the real anatomy and pathology of tubo-intra-ligamentary pregnancy, nor can the exact nature of a fœtal sac be always determined at a successful operation.

Jayle and Delherm include an unpublished case in their series of intra-ligamentary gestations (numbered 18 to 29 in the entire series). In this case (No. 19) Pozzi removed a macerated fœtus retained for sixteen months. He attempted to extirpate the sac, but this task proved impossible, for the sac had not only opened up the broad ligament but also the mesocolon. The sigmoid flexure pushed forward and to the right capped the sac, or rather formed part of the sac wall, the extirpation of which would have involved the resection of the segment of intestine thus involved. Hence part of the sac had to be left behind. The patient recovered.

Matlakowsky (Case 27) operated at the eleventh month on a case which he specifies as right tubo-intra-

* Jayle et Delherm, "La Grossesse Extra-uterine Tubaire et Intra-ligamentaire après le Cinquième Mois," 'Revue de Gynéc. et de Chirurg. Abdom.,' vol. iv, No. 1 (Jan., Feb., 1900).

ligamentary. He succeeded in excising the whole sac, but wounded the right ureter and had to remove the right kidney. As in Dunning's case, the sac was closely associated with one cornu and the serous coat of the back of the uterus. The patient recovered.

Voigt (Case 20) operated fourteen days after the death of the fœtus at term. The sac was believed to be in the left broad ligament. The mesocolon was opened up as high as the descending colon. The removal of the entire sac was attempted. Violent hæmorrhage occurred, and proved difficult to check; the patient nearly died, and some of the sac was left behind. Recovery was fairly rapid.

In this case the fœtus and sac were not putrid and the patient was in good condition. In my own it was otherwise, and much less hæmorrhage would have killed the patient.

In four of Jayle and Delherm's cases where, as in those already given and in my own, the fœtus was dead, the sac was not removed but drained. In one of these (No. 18), published for the first time, Pozzi removed a macerated six months' fœtus with its placenta. He attempted to remove the sac, but failed on account of numerous adhesions. He therefore fixed it to the parietes, packed it with iodoform gauze, and also drained it with a T-shaped tube through Douglas's pouch. The patient recovered. In the second case (No. 24, Oliver) a macerated fœtus was retained for six months after term. The sac, which occupied the right broad ligament, contained pus. After extraction of the fœtus the sac was drained. The patient made a good recovery and bore two children afterwards. In the third case (No. 25, Oliver) a macerated fœtus had been retained for five months after term. The sac contained pus; it was "marsupialised," fixed to the parietes, and drained. The placenta came away in pieces; an attempt to remove it at the operation caused severe bleeding. In the fourth case (No. 28, Rochet) the fœtus had been retained

for two months; it was macerated. The sac was simply drained; the placenta came away at the end of a week. The patient recovered.

In the five remaining cases in Jayle and Delherm's collection the fœtus was living, so that there was no source of sepsis at the moment of operation. In the first (No. 21, Frommel) the child seems to have lived over term. On its extraction alive there was so much hæmorrhage from the sac that the tampon was applied at once, and no attempt to extirpate the sac was thought of. The placenta was extracted normally on the seventh day; much hæmorrhage followed, stopped by the tampon. Ultimately the patient recovered. In the second (No. 22, Frommel), where the child was saved, the cyst, with the uterus, was actually drawn to a great extent outside the wound, but could not be extirpated. The hæmorrhage on separating the placenta was very severe. The sac was packed and drained, but death occurred on the third day. In the third case (No. 23, Frommel), the placenta being wounded, the sac was immediately packed after the extraction of the living fœtus, but fatal hæmorrhage ensued. In the fourth (No. 26) Breisky removed sac and placenta entire and mother and child were saved. But the fifth case was like the third. Lebec (No. 29) was obliged to cut through the placenta in order to get at the fœtus. Hæmorrhage followed and proved fatal; no attempt was made to extirpate the sac, which was developed out of the left broad ligament.

Thus, in the above series, two out of three attempts to remove the entire sac after extraction of a dead retained fœtus proved unsuccessful, whilst the third involved the sacrifice of a kidney through wounding of a ureter. On the other hand, in the five cases where the fœtus was alive there was so much hæmorrhage in four that no attempt was made to remove the sac, whilst in one the sac was removed with the placenta successfully.

In the four cases of drainage of the sac after extraction of a dead fœtus, all seem to have recovered; but except

in case No. 24 the after-histories are not sufficiently explicit. Nevertheless drainage is at least the safest course.

I must repeat the observation which I made in speaking of Dunning's case : I cannot clearly understand how a tubo-intra-ligamentary sac can be dissected out entire, and fancy that in some of these records the observer was in error.

Taylor seems quite surgical when he insists that in tubo-ligamentary pregnancy, not only is there no necessity for the operative removal of the placenta, but there is likewise no need for the surgeon to attempt to remove the sac. So high an authority as Martin, of Greifswald, strongly urges an opposite course. He advocates extirpation of the sac. Drainage, he says, means tedious convalescence, hernia, and intestinal fistula.* So it does, and intestinal fistula and worse befell my case, but extirpation was an impossibility in that instance and, I suspect, in many other cases, where Martin and Dunning are dangerous guides.

Drainage then being unavoidable, could the fistula and the obstruction have been avoided ?

Can dangerous contraction of the sac be prevented ?—The essential feature in the simple treatment of the sac, which I was bound to adopt, is packing and drainage. It is the only possible treatment after operations for tubo-abdominal pregnancy, as in the cases of Champneys, Taylor, and others, where there is no true sac wall above or below, and in cases where the sac has been converted into an abscess perforating the parietes (Marmaduke Sheild). But I am dwelling now on tubo-ligamentary pregnancy, where a thick cyst wall exists above. This wall is certain to contract, and nearly always draws down with it intestine bound to it by old adhesions.

At first the sac must be tightly packed, as there is always some, and often much, fear of hæmorrhage. Is there any special advantage in employing iodoform ? In

* 'Die Krankheiten der Eileiter,' 1895, p. 393.

Frommel's case, already related (No. 21), iodoform poisoning was distinctly noticed within a few days after operation, ceasing after removal of the iodoform gauze. I have already read notes before this Society of a case where symptoms of iodoform poisoning were observed, when the capsule of a pelvic cyst had been packed with iodoform gauze.* When the sac is already septic, I question whether this variety of medicated gauze is of the least good, and many authorities discard it in any kind of dressing.

But suppose that we employ ordinary absorbent gauze? Sterilised gauze is hardly safer, for it must be speedily made septic by the tissues of the sac. The most important question is, When should the packing be discontinued?

That it needs frequent change at first there can be no doubt. When a fæcal fistula develops it is difficult to manage packing. I washed out the fistula daily with saline solution from the rectum to keep it clean, and it closed, only too much, so as to leave no trace visible at the necropsy. This was due to the same contraction, I suspect, as that which dragged on the small intestine, and not to the saline irrigations. I think that packing should be continued longer than was done in my case, and in most similar cases, so as to avoid too rapid contraction of the sac and dragging on the intestines. Yet it is possible that packing might promote the development of further adhesions. It is certain that, up to the present, we have had to depend too much upon luck when undertaking the treatment of the fœtal sac by packing and drainage.

I suspect that relatively few cases of any kind of operation for tubo-ligamentary pregnancy that ended fatally have been published, so that literature and statistics deceive us as to their actual gravity. On that account I have reported this case, and think that it is

* "On the Management of True and False Capsules in Ovariotomy," 'Trans. Obst. Soc.,' vol. xxxix, 1897, p. 265.

important that others should be published. Humanity calls for facts rather than for the registration of our triumphs.

Mr. Butler-Smythe said that in this particular case the fœtid contents of the sac would alone have prevented any attempt at enucleation. He considered that the patient's life had been prolonged owing to the treatment adopted by Mr. Doran, who repeatedly washed out the sac with a strong solution of iodine before closing the wound. He (Mr. Butler-Smythe) advocated this treatment in all similar cases.

Dr. Cullingworth expressed the pleasure it had given him to listen to the President's paper. He quite agreed with the author that it was well to give the Society an opportunity for discussing some of the views recently propounded with reference to ectopic gestation, and especially to that form of it known as abdominal gestation. He himself believed that Mr. J. W. Taylor (whose new book on extra-uterine gestation was the best account of the subject in our language) had succeeded in demolishing the theory hitherto held that almost every abdominal pregnancy was due to secondary rupture of an intra-ligamentous pregnancy. The arguments and illustrative cases Mr. Taylor had adduced seemed to him absolutely convincing. Our knowledge of the whole subject of ectopic gestation was still in its infancy, and it should not be matter for surprise if some of the views propounded by the earlier workers should have to be reconsidered as our experience enlarged.

With regard to the question of removing the sac when operating upon cases of advanced ectopic gestation, he entirely agreed with the President that it was impossible to lay down any hard and fast rule. Undoubtedly the ideal method was to remove the sac, but it was not always practicable. In the President's case, for example, it would have been absurd to attempt it. The rule should be to remove the sac when it was possible. Where it was impossible to adopt this course the sac should be placed under the conditions most likely to conduce to the patient's recovery. The most important of these conditions was to ensure free drainage. He did not think it was a good plan to pack the cavity with gauze of any kind, and he therefore did not propose to discuss the comparative merits of the various kinds of gauze. He thought the fashion of gauze packing was at present adopted much too frequently in abdominal surgery, and in the case of a necrotic gestation sac he considered it entirely out of place. Free drainage was what was wanted, and that could be obtained better without packing than with. Gauze packing was apt to block up the way, and

the removal of it was very painful. He considered that the introduction of gauze in large quantities into the interior of the abdomen should be restricted to cases where there was actual hæmorrhage that could not otherwise be controlled, or where there was reason to fear serious secondary hæmorrhage.

He held similar views as to the practice of indiscriminate and wholesale irrigation. Suppurating cavities emptied themselves quite satisfactorily if there was a free opening, and no amount of washing out would separate adherent sloughs. The idea that a cavity with septic or necrotic walls could be disinfected by antiseptic irrigation seemed to him childish. It might be temporarily deodorised, but the conditions could not be otherwise affected. It should also be further remembered that there may be lesions of continuity in the sac wall, and that putrid matter may be washed by the irrigation through these into parts outside where it might not otherwise have found its way. Of the value of irrigation in general surgery he was not competent to speak, but he was convinced that it would be a good thing if it were less generally adopted as a routine practice in many departments of gynæcological surgery. When men who had been working in the surgical wards of the hospital came to work with him in the gynæcological ward, he found it necessary to be constantly restraining their irrigating propensities. The washing out of suppurating cavities might be occasionally useful where there were loose masses of broken-down tissue to be got rid of, but under any other circumstances he doubted whether it did any good.

The President had referred to, and seemed disposed to accept, Freund's theory as to diarrhœa being an indication that the placenta is attached to intestine. He had always regarded the diarrhœa, so frequently observed in these cases of advanced ectopic gestation with dead fœtus, as partly the result of irritation from pressure, and partly as one of the symptoms of septic infection. He would be glad to hear whether there were any special reasons in this case for attributing the diarrhœa to other causes than these.

The fact that the fæcal fistula had closed, even under the extremely unfavourable conditions here present, was a clinical fact of the greatest interest, and bore out an opinion he had frequently expressed, that the spontaneous closure of such fistulæ may always reasonably be hoped for when they are not too low down in the rectum, and when the subjects are free from tubercle or malignant disease.

He hoped that the remarks he had ventured to make would not be taken in any other light than as friendly comments, or as any indication that in his opinion a different plan of treatment would have brought about a more favourable result. He did not believe that this patient's life could have been saved by

any treatment. He concluded by once more thanking the President for his communication, and for providing them with such excellent material for discussion.

Mr. Malcolm said he had seen this patient before the operation, and had been present at the operation, and Mr. Doran had, if anything, understated the extent of her emaciation and debility. The fact that within a few days of the operation one or more fæcal fistulæ had developed showed conclusively that it was impossible to remove the sac of the fœtation. Mr. Malcolm agreed with Dr. Cullingworth that washing out the abdomen had been resorted to more frequently than was desirable in abdominal surgery, but in a case of this kind, with a putrid cavity and much sloughing placental tissue on its walls, he should certainly advise washing out as the best method of cleaning the sac. As regards the mode of death, judging by the way in which the patient's abdomen had distended and become flat again after a time, he thought there must have been an escape of gas from the upper part of the intestine as long as the patient lived. Thus the symptoms were not those generally found in obstruction of the bowels, although an obstruction with a fistula existed, and death was due to exhaustion and malnutrition.

Dr. Robert Boxall had twice seen a fæcal fistula heal in the same patient when in a serious condition of ill-health from a suppurating dermoid tumour. It is an important fact that such fistulæ will sometimes heal even where the patient is seriously ill. He suggested that a rubber bag, like a child's balloon, might with advantage be substituted for gauze packing. By attaching a tube and funnel and filling with solution, pressure could be regulated to a nicety. It could be emptied by syphoning out the fluid and easily refilled, thus avoiding the disadvantages of repacking.

The President, in reply, noted that he had applied the term "tertiary condition" to the "abdominal pregnancy" of Tait and Bland-Sutton, the "tubo-ligamentary abdominal pregnancy" of Taylor, who believed that as a rule abdominal pregnancy was secondary, being the direct result of rupture of a tubal sac into the peritoneal cavity. In the tubo-ligamentary abdominal variety a tubal sac burst into the broad ligament, and a tubo-ligamentary pregnancy, a secondary condition, developed; then this secondary sac burst into the peritoneal cavity and the tubo-ligamentary abdominal pregnancy was established. To the Edinburgh school was due the honour of demonstrating the true nature of a uterine ligamentary pregnancy; whilst Taylor had thrown light on the posterior type and made the whole subject of ectopic gestation comprehensible at last. The President was glad to find that the Society agreed with him in maintaining that no attempt should be made to dissect away the sac in an

advanced posterior ligamentary pregnancy. He had some experience in swabbing fœtid sacs with pure tincture of iodine; the results were good, though at the operation the vapour of the iodine set free by the warmth of the body was sometimes very disagreeable to the operator and others concerned in the proceedings. The iodine was strong, sure, and, unlike iron salts and other chemicals, free from danger. The President was compelled to wash out the sac frequently because of the fæces and the fœtid sheets of placenta. He thought that antiseptic lotions stimulated the exposed tissues and caused granulations to develop, but this change in a debilitated septic subject might involve low inflammatory processes, ulceration, and sloughing, as Dr. Cullingworth implied. The President removed the packing within a few days. Dr. Boxall's suggestion that the sac might be prevented from too rapid contraction by means of an inflatable thin rubber bag seemed worth a trial. There was no evidence of a small intestine fistula; the patient was killed not by drainage of food which might have been digested, but rather by inanition, due to the dragging of the sac on the coils of gut and the adhesions between different surfaces of mesentery. Freund's theory about diarrhœa was open to criticism; it might be simply a symptom of sepsis, as Dr. Cullingworth believed, but in the President's case, as Mr. Malcolm noted, this complication prevailed chiefly during the last half of pregnancy before the death of the fœtus, and the placenta was partly attached to the rectum, circumstances which seemed to support Freund's opinion. In conclusion the President feared that no certain method for preventing the dangers due to contraction of a sac of this kind was at the operator's disposal. It was unfortunate that so much dependence had to be placed on luck.

JULY 4th, 1900.

Alban Doran, F.R.C.S., President, in the Chair.

Present—38 Fellows and 3 visitors.

Books were presented by the Presbyterian Hospital Staff (New York) and Dr. Jellett.

William Warburton Wingate, M.B., B.C.Cantab., was admitted a Fellow of the Society.

The following gentleman was proposed for election:—Thomas William Shepherd, L.R.C.S. & L.M.(Launceston).

The following gentlemen were elected Fellows of the Society: Jameson John Macan, M.A., M.D.Cantab. (Cheam); Ralph Henry Vincent, M.B., B.S.Dunedin; George Mansell Dawkin, L.R.C.P.Lond. (Pontypridd); Horatio White Abbott, L.R.C.P.Lond.

FROZEN SECTIONS OF A UTERUS AT THE TENTH WEEK OF PREGNANCY, SHOWING HÆMORRHAGES INTO THE PLACENTA, DECIDUA REFLEXA, AND DECIDUA VERA FROM A PATIENT WHO DIED OF HEART DISEASE.

Shown by G. F. Blacker, M.D.

The specimen was obtained from the body of a woman who died of double mitral disease and hæmorrhagic pleurisy.

The clinical history of the case is shortly as follows:

M. B—, æt. 27, was admitted into University College Hospital January 27th, 1900, complaining of shortness of breath, present for the past twelve months, but which

had markedly increased during the last month; hæmoptysis and weakness. She had had one child, seven years ago. On admission there was great dyspnœa present. Both legs and the lower part of the abdomen were markedly œdematous. Numerous *râles* could be heard on both sides of the chest, mitral systolic and diastolic murmurs were present, and the liver was enlarged, the lower margin reaching as far down as the level of the umbilicus. There was no albumen in the urine. A week after admission the dyspnœa had markedly increased, dulness appeared in the right axilla, and thirteen ounces of blood-stained fluid were drawn off from the right pleural cavity. The patient died two days later, nine days after admission. No abdominal pain was complained of, and there was no discharge from the vagina.

At the post-mortem examination the left pleura was found to be adherent to the diaphragm, pericardium, and chest wall. The right pleural cavity contained three quarters of a pint of blood-stained fluid. A recent infarct was present at the apex of the right lung. The right side of the heart was much engorged with blood; the right ventricle and right auricle were dilated, the tricuspid valve admitting three fingers. The mitral valve was covered with vegetations, and the mitral orifice would not admit the tip of the little finger. There was no narrowing of the coronary arteries. The liver presented a typically nutmeg appearance. The capsule of the kidneys stripped off without difficulty, while the cortex was of normal width, but broke down readily under the finger.

The uterus was removed from the body as carefully as possible and placed in a freezing mixture of salt and ice for eighteen hours. It was then sectioned with a saw. Tracings of the section were taken on glass, and these were used in making the coloured drawings which were painted from the specimen in the recent state.

The specimens shown are preserved in formalin and glycerine. The uterus was divided into four sections by

three cuts, one passing approximately through the median plane, and the other two about midway between the median plane and the lateral margins.

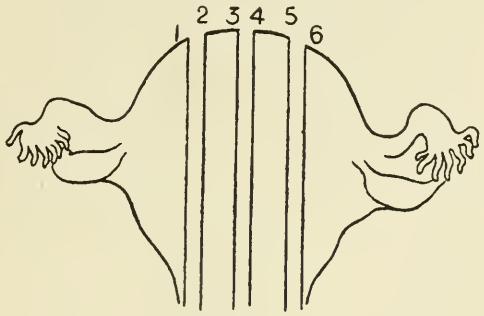

Diagram illustrating direction and position of sections made through uterus. Plates XIV, XV, XVI, and XVII correspond to the surfaces numbered 1, 2, 4, and 6. Uterus viewed from behind.

No history was forthcoming as to the date of the patient's last menstrual period, but the duration of pregnancy appears to be just ten weeks. The length of the trunk of the fœtus is about 41 mm., and its total length, from vertex to sole, 61 mm. The fœtus has been cut through in two of the sections, the first passing through the left side of its head and the corresponding shoulder, and the second through the body from the right shoulder to the lower part of the trunk on the left side. It is situated in the upper part of the amniotic cavity, presenting by the breech, and in an attitude of general flexion. This position of the fœtus, and some undue elongation of the whole uterus which is present, are due to the fact that the uterus was suspended by the vagina while being frozen.

The measurements of the uterus are as follows :

From fundus to external os . . 14·1 cm.

From fundus to internal os . . 9·4 cm.
(the position of the latter being determined by naked-eye examination alone, and not by microscopical examination).

Antero-posterior diameter . .	6·7 cm.
Transverse diameter . . .	6·6 cm.

To naked-eye examination the muscular tissue presents a normal appearance. It measures 6 mm. in thickness at its thickest part at the fundus. The long axis of the amniotic cavity is not quite vertical, its upper end being directed backwards, the thinnest part of the uterine muscle corresponding very closely to the position of the upper pole of the amnion.

The anterior uterine wall is thickest 4·5 cm. above the internal os, where it measures 14 mm. The thickest part of the posterior wall, 3 cm. above the internal os, measures 19 mm.

The placenta is attached to the anterior uterine wall, and there is a very sudden diminution in the thickness of the wall at a point 6 cm. above the level of the internal os, the measurement diminishing suddenly from a thickness of 15 mm. to one of 10 mm. No such striking diminution is to be seen in the case of the posterior uterine wall, which gradually diminishes in thickness as it approaches the fundus uteri.

The decidua vera at the fundus measures 1 mm. in thickness. The conjoined decidua vera and reflexa opposite the middle of the placental site measure 4 mm., the decidua vera alone 2 mm.

The lower limits of the placenta are difficult to define, numerous chorionic villi being present opposite the lower pole of the ovum in microscopic section. Although the decidua vera and decidua reflexa are lying in contact with one another throughout the greater part of their extent, yet it is possible to separate them all round the ovum from one extremity of the placenta to the other. Determined in this way the lower edge of the placenta is distant 6·5 cm. from the internal os, its vertical measurement being 4·5 cm., and its thickest part 1·5 cm. The amniotic cavity measures 5 by 3 cm., and the end is attached 1·3 cm. from its lower end.

The hypertrophied mucous membrane of the cervix

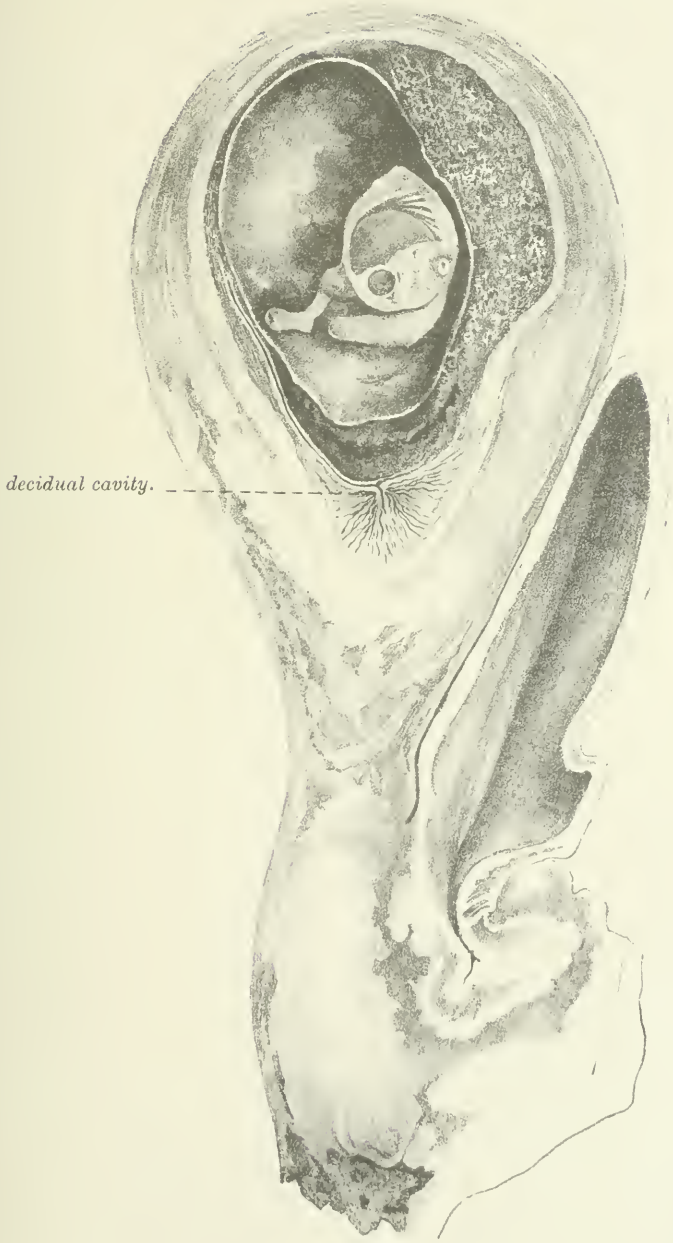

Illustrating Dr. Blacker's Specimen of Uterus in Early Pregnancy.

Bale & Danielsson, Ltd., Lith.

Illustrating Dr. Blacker's Specimen of Uterus in Early Pregnancy.

Bale & Danielsson, Ltd., Lith.

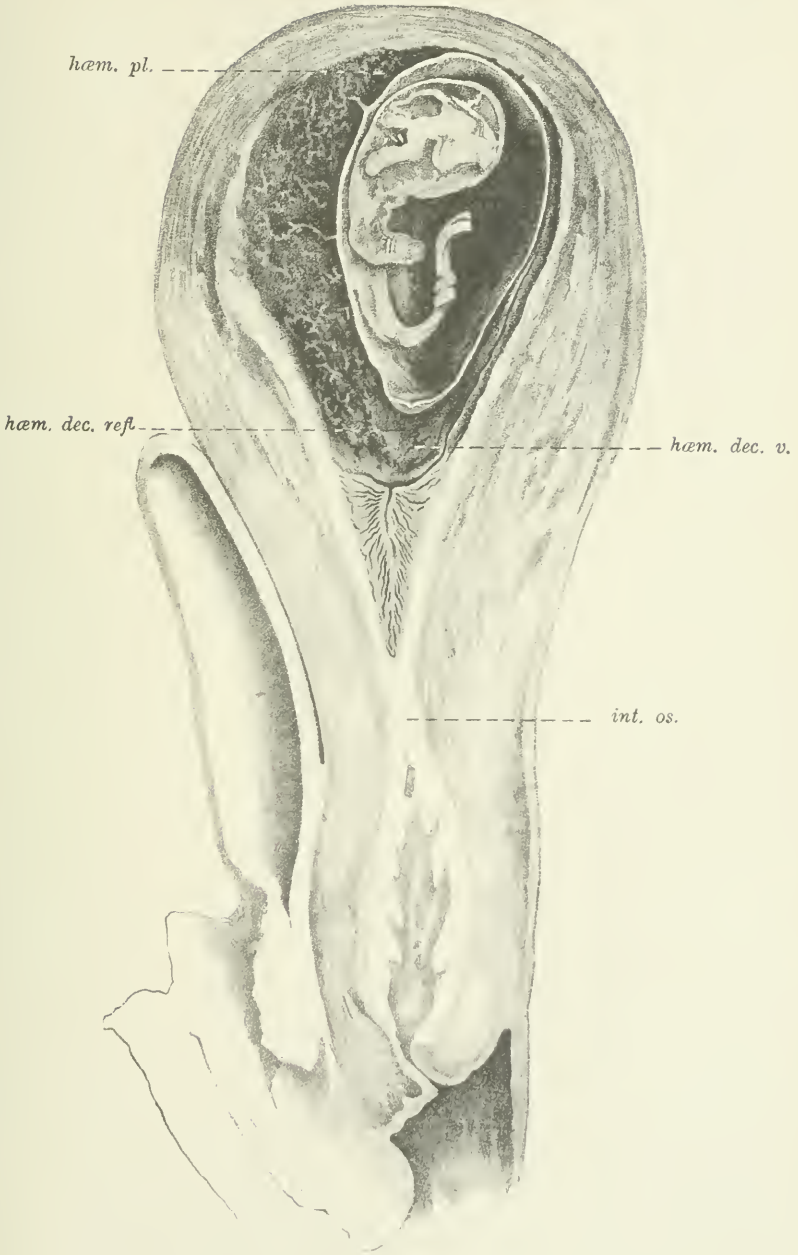

Illustrating Dr. Blacker's Specimen of Uterus in Early Pregnancy.

Bale & Danielsson, Ltd., Lith.

Illustrating Dr. Blacker's Specimen of Uterus in Early Pregnancy.

Bale & Danielsson, Ltd., Lith.

Decidua Vera showing hæmorrhage.

Villus showing hæmorrhage into substance.

Illustrating Dr. Blacker's Specimen of Uterus in Early Pregnancy.

Hale & Danielsson, Ltd., Lith.

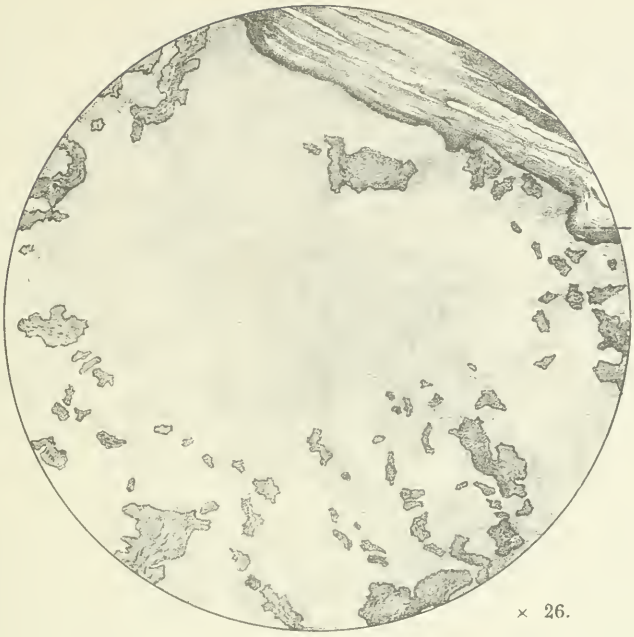

Placenta showing wide separation of Villi from hæmorrhage.

Decidua Reflexa, showing hæmorrhage about ¾ inch from margin of Placenta.

Illustrating Dr. Blacker's Specimen of Uterus in Early Pregnancy.

Bale & Danielsson, Ltd. Lith

with well-marked folds, the spindle shape of the cervical canal, the plug of mucus completely filling it, and the fact that both the internal and the external ossa are closed is well seen in the sections.

The peritoneum is reflected anteriorly on to the bladder 3·6 cm. above the level of the extenal os and 1 cm. below the level of the internal os.

The utero-sacral ligaments take origin at a point 4 mm. below the line of reflexion of the peritoneum. The level of the firm attachment of the peritoneum could not be ascertained with accuracy. Comparatively few vessels are seen in the sections. A large vein cut across, 24 mm. above the internal os, probably marks the upper level of the lower uterine segment. The sections demonstrate very well the commencing obliteration of the decidual cavity, viz. the space that is present in the early weeks of pregnancy between the decidua vera and decidua reflexa. The cavity is still evident, however, and can be recognised in the shape of a Y, its two oblique limbs embracing the lower pole of the ovum, and the posterior one running up for some distance between the two portions of decidua. The vertical limb of the Y is also readily seen running down between the decidua vera on the anterior and posterior uterine walls towards the internal os. From the junction of the vertical and oblique limbs to the internal os measures 3 cm. The distance from this point to the lower pole of the ovum is 10 mm., and this represents the thickness of the decidua reflexa at that spot. The decidua vera opposite this measures 9 mm. on the posterior wall and 8 mm. on the anterior wall.

On naked-eye inspection it is evident that marked hæmorrhages have occurred into the placenta, the decidua reflexa, and in some places, at any rate, into the decidua vera. The presence of these hæmorrhages obscures the lower limit of the placenta, and no doubt accounts for the excessive thickness of the decidua. The hæmorrhages are situated mainly at the periphery of the placenta and in the adjacent portions of the decidua reflexa opposite the

lower pole of the ovum. No hæmorrhage has occurred into the amniotic or decidual cavities, while the portion of the decidua vera just above the internal os presents a perfectly normal appearance.

Microscopic examination.—The peritoneum is normal. The superficial and middle layers of muscular tissue present a healthy appearance. In many places the muscular fibres immediately beneath the spongy layer of the decidua show definite yellowish discoloration, the outlines of the fibres being difficult to distinguish, the nuclei staining badly, and numerous pigment granules being present in the muscle cells. This appearance is confined to areas corresponding to hæmorrhages in the placenta. There are no extravasations of blood in the muscular tissue, and there is no cellular infiltration. The vessels appear normal in section.

Decidua serotina presents areas of pigmentation of similar character to that seen in the superficial layers of muscular tissue, and here and there some small hæmorrhages. The gland spaces of the spongy layer are normal in appearance.

Placenta.—A great deal of pigmentation is present throughout the whole of the placenta in the form of granules in the cells and elsewhere. In many parts the placenta presents a typically normal appearance, especially as regards the proportion of the villi to the intervillous spaces. In portions, however, where to the naked eye there are definite signs of hæmorrhage, the intervillous spaces are greatly enlarged, and the villi widely separated. Some of the villi present signs of hæmorrhage into the stroma. The exact origin of this hæmorrhage is uncertain ; possibly the blood has invaded the villi from the intervillous spaces. A few of the villi present the appearance of the early stages of mucoid degeneration. Small microscopic areas of the intervillous spaces have been obliterated by deposits of fibrin.

Decidua reflexa.—In those areas which present definite signs of hæmorrhage to the naked eye, well-marked

localised extravasations of blood into its substance are present, separating its layers.

Decidua vera.—The deeper layers present a normal appearance, but in the more superficial there is marked congestion of the vessels and small hæmorrhages into the interglandular stroma.

None of the sections present any evidence of arterial disease.

I wish to express my thanks and my great indebtedness to my friend Mr. Lawrence, not only for the preparation of the microscopic specimens, but also for the very beautiful drawings illustrating the specimens which I have been able to show.

List of authors who have published sections of the pregnant uterus between the end of the first month and the end of the fourth month.

Bayer, H.—'Gynäkologische Klinik Freund,' 1885. Sections of uterus in 2nd, 3rd, and 4th months of pregnancy.

Braune, W.—'Topographischer anatomischer Atlas,' 1872, pl. ii. Sections of uterus at end of 2nd month of pregnancy.

Hofmeier und Benckiser.—'Beiträge zur Anatomie des Schwangeren und kreissenden Uterus,' 1887. Sections of uterus in 2nd and 4th months of pregnancy.

Gottschalk.—'Archiv für Gynäkologie,' Band xxix, 1887, p. 488. Sections of uterus in 5th week of pregnancy.

Pinard and Varnier.—'Études d'Anatomie obstetricale,' 1892. Section of uterus at 3½ months of pregnancy.

Leopold, G.—'Uterus und Kind,' 1897. Sections of uterus at 3½ and 4 months of pregnancy.

Waldeyer.—'Das Becken,' 1899. Sections of uterus at 3, 3½, and 4 months of pregnancy.

PREGNANT UTERUS AND FIBROID TUMOUR REMOVED BY ABDOMINAL HYSTERECTOMY.

Shown by Peter Horrocks, M.D.

The specimen was removed five days previously from a primipara, who had had considerable pain and pressure symptoms at about the fifth month of pregnancy. There was difficulty in the diagnosis, the right-hand tumour being thought the pregnant uterus by some, and the fibroid by others. He had considered the right-sided tumour was the uterus on account of a ridge which ran down the right side of it. This ridge, which is formed by the round ligament, Fallopian tube, and ligament of the ovary, was of great service in diagnosis. It could not, however, always be felt, as, for instance, when the uterus was twisted so as to throw the ridge behind. But the left-handed tumour had no such ridge on it, and it proved to be the fibroid. The two were separated at the upper part by a sulcus. On opening the abdomen the two tumours were blended in the greater part of their length, and it seemed impossible and even dangerous to attempt to remove the fibroid alone. And yet during the course of the operation the fibroid enucleated easily from the cellular tissue in the left broad ligament, and the attachment to the uterus was more by vessels and connective tissue than by continuity of tumour. In future cases it would be better to begin the removal on the tumour side, so as to make sure whether it could be removed alone or not.

RUPTURED UTERUS AT TERM THROUGH SCAR OF OLD CÆSAREAN SECTION; ABDOMINAL HYSTERECTOMY (see p. 262).

Shown by J. H. Targett, M.S.

Dr. Herbert Spencer said an examination of the specimen seemed to him to show that the rupture had not taken place

at the scar, but to one side of it. The history seemed to point to accidental hæmorrhage and to the rupture occurring during version. He hoped these two points would be made clear in the description of the case, which was an important one.

Dr. Peter Horrocks said that he had performed the Cæsarean section on this case about three years ago. She then had a transverse presentation, and futile attempts had been made to decapitate. He had tried himself, but the uterus was so firmly contracted round the child, and the mother's condition was so serious, that it was considered the best for her to have Cæsarean section done. She made a good recovery. He could not help feeling that the site of rupture was in the line of the incision. Obviously this was and must be a weak part in the uterine wall, and, as a fact, it had given way along the front of the uterus in the same length as the incision made during the operation.

In cases where it was thought desirable he generally sterilised the patient by snipping out half an inch of each Fallopian tube at the thinnest part without applying any ligatures.

He mentioned a case in which the patient had been sterilised after Cæsarean section by ligaturing the Fallopian tubes. In spite of this she became pregnant again, and the uterus ruptured along the line of incision when near full term, and the child and a portion of the placenta escaped into the abdomen. Dr. Galabin removed the uterus, and the specimen is now in the Guy's Museum. The patient recovered.

The ligature on one side had cut through the tube, and the severed ends lay about half an inch apart. On the other side the tube and ligature looked as if the tying had only just been done, and on experimenting it was impossible to force a coloured liquid through the tube. Still it was thought that in all probability the ovum which had become impregnated had got past the constriction produced by the ligature, and so entered the uterus.

MULTIPLE MYXOMATOUS POLYPI FROM CERVIX UTERI.

Shown by William Duncan, M.D.

PORRO-CÆSAREAN HYSTERECTOMY WITH RETRO-PERITONEAL TREATMENT OF THE STUMP IN A CASE OF FIBROIDS OBSTRUCTING LABOUR; WITH REMARKS UPON THE RELATIVE ADVANTAGES OF THE MODERN PORRO OPERATION OVER THE SÄNGER-CÆSAREAN IN MOST OTHER CASES REQUIRING ABDOMINAL SECTION.

By Amand Routh, M.D., B.S., F.R.C.P.

(Received May 8th, 1900.)

(*Abstract.*)

When first seen the pelvis was occupied by a large fibroid, and the cervix uteri was out of reach above the symphysis.

During the thirty-fourth week the pelvic fibroid was rather suddenly drawn up out of the true pelvis, and the cervix resumed its proper position, and it was hoped parturition would be naturally performed.

Attempts to induce labour by introducing a bougie, by Steele's hydrostatic dilator, and by rupturing the membranes, failed to produce any sensation of pain, except when the hydrostatic dilator was *in situ*. A well-marked *caput succedaneum*, however, was subsequently found, proving that the intermittent uterine contractions were really labour pains. (Is the sensation of pain in true labour "pains" due solely to dilatation of the lower uterine segment, and of the cervix and vagina, and not, as is usually taught, to uterine contraction also?)

As it was found that the head was arrested just above the lower segment of the uterus by two opposing fibroids a Porro-Cæsarean operation was performed, in preference to a pan-

hysterectomy, or to Cæsarean section with removal of the appendages.

The operation.—When the abdomen was opened in the middle line the left broad ligament came into view owing to the torsion of the uterus, with the largest fibroid on its right. The incision into the uterus had therefore to be made posteriorly to the left broad ligament, and was directly over the placental site. The placenta was stripped off, the membranes incised, the child extracted, the placenta and membranes removed, and the uterus brought out through the abdominal incision. The broad ligaments and round ligaments were tied and cut through, the anterior flap of peritoneum with the bladder was turned down, the uterine arteries tied, the posterior peritoneal flap formed, and the stump covered over by the peritoneal flap and dropped back into the abdomen.

The tumour weighed 5 lbs. 12 oz. The baby—a boy—weighed 6½ lbs., and both he and the mother had an uneventful recovery. The abdominal scar now measures 5½ inches.

It is a point worthy of discussion whether supra-vaginal amputation of the uterus (Porro's operation), with retro-peritoneal treatment of the stump, is not safer for the patient in skilled hands than a Sänger-Cæsarean section with sterilisation in all cases of *permanent* obstruction to labour requiring abdominal section, except perhaps those due to cancer of the supra-vaginal cervix.

When it has been decided that a viable child has to be delivered from a living mother by abdominal section, the method to be adopted has to be determined. All cases would resolve themselves into three groups :

1st. Those where hysterectomy (Porro or panhysterectomy) with retention of one or both ovaries is absolutely indicated.

2nd. Those where a Sänger-Cæsarean operation (with or without sterilisation) is absolutely indicated.

3rd. Those capable of being treated by either operation.

It is agreed that a Porro (or panhysterectomy) is absolutely indicated in the following cases :—obstructing fibroids ; cicatricial stenosis of the vagina where the lochia cannot escape ; septic endometritis ; decomposed fœtus ; (osteomalacia owing to the fact that removal of the appendages is often curative ;) uterine

hæmorrhage from uterine inertia during Cæsarean section; after much previous manipulation of the uterus in attempts to extract *per vaginam*.

Sänger-Cæsarean section without sterilisation is, on the other hand, absolutely indicated, instead of a "Porro," where it is considered desirable for the woman to have a chance of another child, and Sänger-Cæsarean section with sterilisation, is required (?) in cases of cervical cancer, when the supra-vaginal cervix is involved. There only remains, therefore, a third group of cases where a Cæsarean section with sterilisation is usually done, but where it would, in my opinion, be quite as reasonable to do a modern "Porro."

This third group includes all cases of sufficient pelvic contraction, and it is in such cases that the relative value of a modern "Porro" operation as compared with a sterilising Sänger-Cæsarean operation demands serious consideration.

Mrs. T. M—, aged 33, married five years, never pregnant.

Admitted into Chandos Ward of Charing Cross Hospital September 21st, 1899.

Her menstrual history was regular, the periods lasting from three to four days; the loss was not profuse, and there was only trifling dysmenorrhœa during the day preceding the flow. Her last period was on July 5th, a period of amenorrhœa of eleven weeks. She had noticed a lump in the right iliac region for three years, but it had not caused pain, nor had it increased in size the last six months. She had had some frequency of, and pain during, micturition for twelve months. She was now sent into Chandos Ward by Dr. Eden from the out-patient department.

On abdominal examination there was a large fibroid tumour occupying the hypogastric, umbilical, and right iliac regions. Just above the left Poupart's ligament a smaller fibroid nodule was felt, and between the two the uterine wall had an elastic feeling on palpation, which suggested pregnancy.

Per vaginam.—The cervix was out of reach behind the symphysis pubis, and the sacral hollow and most of the true pelvis was occupied by a large impacted fibroid.

The urine was normal.

A provisional diagnosis of pregnancy in a fibroid uterus was made. She was kept in the hospital for five weeks, during which time unsuccessful efforts were made by digital pressure under anæsthesia, and by hydrostatic pressure, to elevate the impacted fibroid. Careful measurements were also made, but very little increase of size was discoverable, and as no further evidence of pregnancy could be detected, and the indications from the breasts were almost negative, it was thought possible that the amenorrhœa was due to some other condition.

She came back, as instructed, in two months on January 29th, 1900, having then had complete amenorrhœa for twenty-nine weeks.

On examination the breasts were found to be very suggestive of pregnancy, and the abdominal measurements had much increased, especially over the elastic portion of the uterus on the left side. A souffle could be heard just below the umbilicus, and both intermittent contractions and fœtal movements were detected.

Per vaginam.—The pelvic fibroid seemed slightly higher up, but the cervix was still out of reach.

The situation was explained to the patient, and as her desire to have a living child was great, and nothing was to be gained by operating then, it was decided to wait and perform a Cæsarean operation when near full term. She left the hospital on February 9th, with instructions to return at once should pain supervene.

On February 24th (thirty-three and a half weeks of gestation) she had some severe abdominal pain, and was readmitted.

On examination the abdominal tumour was much larger, and the difference between the hard fibroid on the right side and the elastic portion of the uterus which contained the fœtus on the left was very marked. The

fœtal heart could be heard. The outline of the fœtus could now be defined, and its position was found to be the first vertex.

Per vaginam.—The large fibroid which previously occupied the pelvis had risen almost above the brim, and was lying rather in the left posterior quarter of the abdomen, and this sudden movement of the tumour probably explained the abdominal pain of the preceding twenty-four hours, as there was no evidence of labour having begun. Owing to the alteration in the position of the pelvic fibroids, the uterus had become so tilted that the cervix was now easily felt in nearly its normal position.

March 10th.—Examination under ether, in consultation with Dr. Eden.

The head was found to be presenting, lying between, but apparently nearly clear of the fibroid tumours, but there was a fibroid the size of an egg in the left antero-lateral wall of the uterus above the level of the internal os, which it was thought might cause trouble. If this should be further drawn up, and should not block the way, it was thought that the head might pass the other two large fibroids, and that Cæsarean section might not be required. It was decided to induce labour at the 38th week, it being now the 36½th week, if labour did not previously supervene.

Accordingly, on March 20th an attempt was made to pass a No. 13 gum-elastic bougie, but it could not be manipulated past the internal os uteri.

On March 23rd, under anæsthesia, the cervix was dilated with bougies, and a ridge, formed by bulging of the small fibroid in the left antero-lateral wall, was then felt which had evidently prevented the bougie from passing. The bougie was now passed into the uterus between the membranes and decidua for about seven inches, the lower end being curled round and kept in the vagina by iodoform gauze packing. Two days later, as

there was no evidence of labour, I passed a sound and swept it round beneath the membranes.

Next day, March 26th, labour pains being still absent, I dilated again, and inserted a Steele's hydrostatic bag containing four ounces of water. "Pains" ensued every fifteen minutes, and next morning, labour being apparently established, I removed the hydrostatic bag. The head was still high up, resting apparently on a ridge or shelf at the lower margin of the small fibroid, which lay just above the plane of the pelvic brim anteriorly, and to the left.

The uterus then continued to contract intermittently, and the membranes bulged and became tense during the contraction, but the patient had no sensation of pain during these contractions, and seemed to be quite unaware of them. The membranes did not come down low enough to dilate the internal os.

On March 27th, at 9 a.m., finding that no progress had been made, and the cervix being soft and dilatable, I ruptured the membranes with a Playfair's probe whilst they were rendered tense during a uterine contraction. On the same evening, at 9 p.m., Dr. Eden and I saw the patient. She said she had had no "pains," but the internal os was slightly more dilated. The head was no lower, and it was evident that it could not pass the lower zone of the uterus, for the fibroids, which were now not kept separated by the liquor amnii, were much closer together, particularly in the lower uterine segment.

With the patient's consent an abdominal operation therefore was decided upon.

In an hour's time, viz. at 11 p.m., March 27th, assisted by my colleagues, Mr. Stanley Boyd, Dr. Eden, and my house physician, Mr. H. H. P. Johnson (anæsthesia being induced by Mr. Lilley), I opened the abdomen in the middle line. I then found that the left broad ligament was in the line of the abdominal incision, and as the whole of the uterus on the right of this ligament was occupied by the largest fibroid tumour, I was obliged

to tilt and rotate the uterus still more to the right, in order to make the uterine incision in the posterior surface of the uterus.

I made a small incision through all the coats of the uterus, extending the opening by tearing upwards and downwards, and found that the maternal surface of the placenta presented along its entire length. I stripped this off rapidly till the membranes were reached, incised them, and extracted the child by the feet. The child cried at once. The uterus was then turned out of the abdominal incision, Mr. Boyd controlling the hæmorrhage by manual pressure round the cervix.

The round ligaments and broad ligaments were then tied, clamped on the uterine side of the ligatures, and cut through, the left ovary being left *in situ*.

The peritoneum was then incised anteriorly and turned down with the bladder, and the uterine vessels were tied on each side A posterior peritoneal flap was then made, and the uterus was cut away, a stump being formed below the level of all the fibroid tumours. The endocervix was cleansed, the muscle of the stump sutured by two rows of buried catgut ligatures, and the peritoneal flaps were drawn over, the stump being finally dropped back into the peritoneal cavity. All clots were sponged out of the abdominal cavity, and the abdomen was closed by a series of interrupted silkworm gut sutures through all the tissues, with a continuous catgut suture uniting the sheath of the recti.

The operation lasted over an hour. The convalescence of both mother and child has been uninterrupted.

The child weighed 6 lbs. 6 oz.

Dr. Eden has kindly given the following description of the specimen :

The uterus is roughly pyriform in shape, measuring 7·5 inches in a vertical, 8 inches in antero-posterior, and 5 inches in transverse diameter. The round ligaments are attached 3 inches below and in part of the summit of the uterus. The incision lies 1·5 inches behind the left

round ligament, and is 3·5 inches in length. The cavity, exposed by this incision, measures 6·25 inches in vertical, and 3·5 inches in greatest antero-posterior, and 2 inches in greatest transverse diameter. There are two main fibroid growths, the larger overlapping the anterior wall, the smaller the posterior wall. The uterine cavity lies between, and has its widest part above the fibroids. The distension of the lower half of the uterine cavity has been greatly limited by the presence of these growths, so that this portion joins an oval canal measuring 1 inch by 1·5 inches in diameter. This undilated portion of the uterine cavity probably corresponds to the lower uterine segment, but owing to the absence of any retraction ring, this cannot be determined with certainty. In addition to the two main fibroid growths there are numerous smaller ones. An interstitial growth the size of a hen's egg occupies the lowest part of the posterior wall of the uterus, being distinct from the main posterior growth. The whole mass removed weighed 5 lbs. 12 oz., and is now exhibited.

Dr. Hubert Roberts has very kindly made an excellent drawing of the specimen.

Remarks.—Careful observation of cases of pregnancy with fibroids has shown that in a large proportion of them the fibroids, which in early pregnancy seem likely to obstruct full term delivery, are, during the pregnancy, gradually drawn up out of the true pelvis, and at or near full term are found to be lying above the presenting part, so that it is usually advisable not to interfere. Fibroids may, however, delay delivery by causing irregular muscular action, or by interfering with the direction of the "direct uterine force," or by inducing either a malpresentation or a flexion of the fœtal axis.

In the case under discussion it seemed hardly possible that the large fibroid, which filled the pelvis, and which had so tilted the uterine cervix that it was out of reach above the pubes, could get drawn up out of the pelvis as the pregnancy advanced. The history of the patient

shows that this elevation spontaneously and suddenly occurred at the thirty-fourth week.

From the patient's point of view it was disappointing to find that this elevation of the largest fibroid was not sufficient to allow labour to terminate naturally. The approximation of the fibroids towards the lower zone of the uterus prevented the head from reaching the internal os, and made an abdominal operation necessary.

A point of physiological interest may be noted. Except when Steele's hydrostatic bag was *in situ*, the patient had no sensation of pain during her "pains," so that I looked upon the uterine contractions, which regularly occurred, as the ordinary intermittent contractions of pregnancy. I noticed, however, on two occasions, that during one of these painless contractions, the membranes forcibly bulged downwards between the opposing fibroids, but they did not reach the internal os, and seemed not to be attached as low as the internal os, owing probably to the ridges formed by the bulging fibroids. There was, in fact, no wedge to effect dilatation of the cervix from above. Yet it was evident that labour had been present, for when the child was delivered a very marked caput succedaneum was seen on its vertex.

Is it possible that the sensations of pain during the "pains" of labour are solely due to dilatation of the cervix and of the vagina, and not to the muscular effort of the uterine muscle? If so, it would be difficult to explain "false pains" and spasmodic dysmenorrhœa, the pains in which cases are said to be due to *irregular* uterine effort. Painless labours, such as those which occur during sleep, are explained by Galabin as being in cases where there has been very little resistance to dilatation, and very small uterine effort was therefore required. In this case muscular effort was evidently great, the obstruction was absolute, and yet there was no sensation of pain.

As regards the operation itself, there was, with the

very efficient help I was receiving, nothing unusually difficult.

The necessity of incising the uterus posteriorly, owing to the left broad ligament being central, and a large fibroid being immediately anterior to it was unexpected, but a suitable part of the uterus was easily brought into position by some further torsion and tilting of the uterus, and some dragging of the abdominal incision to the left. To have cut down also on the placental site was unfortunate, but it was unavoidable, and did not delay the operation, for, finding it was perfectly easy to strip the placenta rapidly off, and incise the membranes when they came into view, I did not adopt the book method of cutting straight through it.

The anterior aspect of the supra-vaginal cervix was covered by the bladder, but contained no fibroid low down. Posteriorly, a fibroid the size of an egg had to be drawn up and enucleated and the stump made below it.

It was noticed how much easier it was to manipulate the uterus than in a fibroid uterus of similar size, apart from pregnancy. All the connections and ligaments of the uterus were more mobile and supple, and it rendered the intra-peritoneal treatment of the stump much easier.

As soon as the contents of the uterus were evacuated, it contracted down most remarkably, so that it could have probably been turned out of the abdomen through a smaller incision than I had made, which is represented by $5\frac{1}{2}$ inches in the present length of the cicatrix. Myomectomy being impracticable, the only possible alternative to removal of the uterus was an ordinary Cæsarean operation, followed by removal of the appendages to sterilise the patient and promote atrophy of the fibroids, but the operation adopted seemed preferable.

Having decided to remove the uterus and fibroids, it seemed desirable to adopt the modern method of dealing with the stump, covering it with peritoneal flaps and dropping it into the abdomen, rather than to adopt Porro's original modification of the Cæsarean section, viz.

to fix the stump at the lower end of the abdominal wound by *serre-nœud* and transfixion pins. The alternative method, that of pan-hysterectomy, did not appear to me to be called for.

It is a question whether, with the modern retro-peritoneal method of dealing with the uterine stump, it would not be better to substitute the modern Porro-Cæsarean operation in nearly all cases of *permanent* obstruction requiring abdominal section for the delivery of the child *during* the life of the mother.

Statistics are not yet available to distinguish between the mortality of the *modern* "Porro," still an infrequent operation, and of the Sänger-Cæsarean.

When Porro in the pre-antiseptic period (1876) introduced abdominal hysterectomy as an alternative, or addition, to Cæsarean section, the mortality of the latter was 84 per cent. Porro's results were encouraging but not satisfactory, for the mortality of the first fifty cases was 60 per cent.

Antiseptics, however, soon reduced the mortality in both operations, and Sänger's improvement of the Cæsarean section enabled the Sänger-Cæsarean operation to succeed even better than the Porro,—or even than the Porro-Müller operation.

Thus up to 1882, out of 212 Sänger-Cæsarean operations there were fifty deaths, or 22·6 per cent., whilst in 272 Porro's the mortality was 150, or 55 per cent.

Dr. Galabin draws attention to the improvement which has followed a greater experience of the Porro operation, for while out of the first fifty cases thirty woman died, only ten died out of the second fifty, *i. e.* 20 per cent.

Leopold* gives as his statistics from 1884 to 1898, seventy-one cases of Sänger-Cæsarean operations with seven deaths, a mortality of 9·8 per cent., and twenty-nine Porro operations (all extra-peritoneal) with three deaths, or a mortality of 10·3 per cent.,—so that the

* Leopold und Haake, "Ueber 100 Sectiones cæsareæ," 'Archiv für Gynäkologie,' Bd. lvi, 1898, p. 1.

latest statistics up to 1898 appear to show that the mortality in skilled hands is practically the same in the two operations.* This was before the intra-pelvic treatment of the stump was generally adopted, and Braun and Fernwald† give still more favourable statistics of Porro's operation up to 1894, for out of thirty-two cases requiring abdominal section, he had twelve classical Cæsarean with one death, and twenty Porro operations without any mortality. There seems every reason to believe that the Porro-Müller operation, modified according to Baer's method by the retro-pelvic treatment of the stump, is likely to lead, in skilled hands, to as good results as in the ordinary abdominal hysterectomy for fibroids apart from pregnancy, the mortality of which in skilled hands is from 2 to 8 per cent.

If so, it stands to reason that this method of abdomino-hysterectomy would be still more successful in cases of pregnancy with contracted pelvis, where there were no fibroids in the uterine lower segment to render the operation longer and more difficult.

There are obvious risks in the Sänger-Cæsarean operation, which are to a great extent foreign to the modern "Porro;" thus in Leopold's statistics several of his Porro operations were required owing to severe hæmorrhage due to uterine inertia in the course of a Sänger-Cæsarean operation. This risk would of course be obviated by making the operation a "Porro" from the commencement.

* Leopold reduces these mortality percentages to 5·8 per cent. and 5·2 per cent. respectively by omitting from the fatal cases following the Sänger-Cæsarean operations, three cases, and from the Porro fatalities, two cases.

The three cases he omits from the former group were (1) a case of unrecognised intra-uterine infection which should have been treated by a Porro's operation; (2) pulmonary œdema following anæsthesia; and (3) where premature labour had four weeks previously been attempted, and where there was gonococcal infection.

The two cases he omits from the Porro fatalities were (1) complicated by medullary sarcoma of the right ovary, and (2) a rachitic dwarf moribund at the operation from cardiac mischief.

† 'Der Kaiserschnitt bei engem Becken,' Wien, 1894.

Most fatal cases of the Sänger-Cæsarean section are due to sepsis, and this danger would be greatly lessened by removal of the placental site and the large absorbent uterine sinuses, as in a "Porro." There have been very few cases published of Porro's operation with retro-pelvic treatment of the stump, but I may remind the fellows that Dr. Gow * showed in 1898 at this Society a uterus with fibroids which he had removed in this manner, both mother and child doing well.

Dr. Eden has kindly drawn my attention to the views held by Dr. Hirst,† Professor of Obstetrics in the University of Pennsylvania.

Writing in 1899, he states that it is his conviction that in a case requiring Cæsarean section modern cœlio-hysterectomy is preferable to cœlio-hysterotomy, having a lower mortality and a greater freedom from complication, not only in the puerperium, but in the patient's future existence. The complications which may arise in the puerperium are post-partum hæmorrhages and puerperal infection. The complications later in life would be, according to Prof. Hirst, retention and decomposition of the lochia owing to the undilated cervical canal not permitting free exit if the operation is done before labour; adhesions between the anterior uterine and abdominal walls; persistent fistulæ communicating with the uterine cavity; rupture of the uterus in subsequent pregnancies and labour, and the necessity for repeated Cæsarean sections if the woman is allowed to become pregnant again.

Some of these reasons for preferring hysterectomy instead of hysterotomy would be met by sterilising the patient after a Sänger-Cæsarean section, but apart from that modification his arguments are in my opinion sound.

Dr. H. J. Boldt,‡ of New York, also advocates hysterec-

* 'Trans. Obstet. Soc.,' 1898, vol. xxxix, p. 7.

† Hirst, 'Text-book of Obstetrics,' 1899, p. 785.

‡ Boldt, 'American Journ. of Obstet.,' 1898, vol. xxxviii, pp. 41—50.

tomy instead of the Sänger-Cæsarean operation, for very similar reasons, in every case where there is an absolute indication for abdominal section; but he prefers panhysterectomy to Porro's, for reasons which need not here be stated.

When it has been decided that a viable child has to be delivered from a living mother by abdominal section, the question at once arises, what particular method of operation should be adopted. All cases would then resolve themselves into three groups:

1. Those where hysterectomy (Porro or panhysterectomy), with retention of one or both ovaries, is absolutely indicated,

2. Those where a Sänger-Cæsarean operation (with or without sterilisation) is absolutely indicated, and

3. Those capable of being treated by either operation.

Among the first group requiring hysterectomy the following may be enumerated:—Obstructing fibroids; cicatricial stenosis of the vagina where the lochia cannot escape; septic endometritis; decomposed fœtus (osteomalacia owing to the fact that removal of the appendages is often curative); uterine hæmorrhage from uterine inertia during Cæsarean section; after much previous manipulation of the uterus in attempts to extract *per vaginam*.

Sänger-Cæsarean section without sterilisation is, on the other hand, absolutely indicated, instead of a "Porro," where it is considered desirable for the woman to have a chance of another child, and Sänger-Cæsarean section with sterilisation is required (?) in cases of cervical cancer, when the supra-vaginal cervix is involved. There only remains, therefore, a third group of cases where a Cæsarean section with sterilisation is usually done, but where it would, in my opinion, be quite as reasonable to do a modern "Porro."

This third group includes all cases of sufficient pelvic contraction, and it is in such cases that the relative value of a modern "Porro" operation, as compared with a

sterilising Sänger-Cæsarean operation, demands serious consideration.

Dr. Galabin noticed that the author had applied the term Porro's operation to the operation performed by him. This term had for so many years been used to signify the operation by which the stump of the uterus was fixed in the abdominal wall, that he thought it was a pity not to limit it to that, but to extend it to a very different operation. He thought that this would tend to confuse the statistics, which it was desirable to keep distinct, that the relative mortality of each might be ascertained. He thought the operation ought rather to be called a Baer-Cæsarean operation, or simply Cæsarean hysterectomy.

He thought that Dr. Routh had been right in his choice of operation. His own experience in that direction was limited to one case, about four or five years ago, in which he performed it in pregnancy complicated by a fibroid tumour, not at the full term of pregnancy, but at something under six months, the abdominal distension necessitating some interference. He was struck by the fact that the pregnancy did not seem to add to the difficulty of the operation, and was led by this experience to recommend it in the 1897 edition of his 'Midwifery' as the best operation when fibroid tumours obstructed the pelvis at full term; and also as an alternative to be considered to the ordinary Cæsarean section apart from fibroid tumours. Since then he had had three or four cases of fibroid tumours obstructing the pelvis during pregnancy, in which all preparations had been made for performing the operation at term, but the tumours ascended unexpectedly in the first stage of labour, and the children were delivered with forceps. He had treated them somewhat differently from Dr. Routh, in that he had left labour to come on spontaneously; and he thought that this, perhaps, favoured the ascent of the tumour.

In one of these cases, the lady being anxious for a family, notwithstanding the risk resulting from the presence of the fibroid tumour; and being sterile, he had curetted the uterus in the hope of bringing about pregnancy, and that result had followed.

He asked Dr. Routh whether any trouble was found from hæmorrhage before the ovarian and uterine arteries were secured, and whether any elastic ligature was used.

Dr. William Duncan congratulated Dr. Routh on the success of his treatment, and agreed with him that in the case recorded abdominal hysterectomy with intra-peritoneal treatment of the stump was preferable to Cæsarean section.

He thought it misleading to call certain operations by the

names of those who are supposed to have originated them (such as Porro-Cæsarean, Sänger-Cæsarean, Baer, etc.)

He was strongly of opinion that abdominal hysterectomy with intra-peritoneal treatment of the stump was much less dangerous than any Cæsarean section, and he would adopt it in all cases which necessitated removal of the fœtus *per abdomen*, the only exception being in cases of cancer of the cervix, in which he thought it safer to clamp the cervix and fix it in the lower end of the abdominal incision.

Of course in cases of hysterectomy one or both ovaries should be left, so that after recovery the patient suffered none of the symptoms met with at the menopause. He pointed out that it is always better to leave both ovaries, as he has several times noticed that when only one has been left various unpleasant symptoms (such as flushings, headaches) have ensued, although not so severe as when both are removed.

Dr. Peter Horrocks thought it would be better to speak simply of Cæsarean section rather than Sänger-Cæsarean, because the chief point in Sänger's modification was sewing the peritoneum completely over the deep sutures by means of Lembert's suture. The evolution of asepsis had shown this to be unnecessary, and so it has been abandoned by many operators. He considered that Dr. Amand Routh had done quite the best thing in the case which he had operated on; but he did not think that it was possible to formulate rigid rules to which operators must adhere. As a matter of experience, it was found that no two cases were alike, and hence it often happened that, even during the course of an operation, it was found best to do something quite different from what was intended when the operation began. In the case he had shown to-night, he believed it would have been possible to have removed the fibroid tumour without removing the uterus as well. Still, speaking generally, he should prefer always to do Cæsarean section rather than Porro's operation, and, although a woman's uterus was no use to her after she had been sterilised, yet he would prefer to leave the uterus, and sterilise by snipping half an inch out of the middle of each Fallopian tube, rather than do a Porro, simply because it was so much easier to do, and so much less risky to the patient. He had never found that the climacteric atrophic changes commenced when one ovary was left behind. He always left both ovaries behind where possible.

Dr. Dakin was unable to agree with Dr. William Duncan that it was necessary to leave both ovaries behind after an abdominal hysterectomy of any kind, in order to prevent the appearance of the unpleasant symptoms to which Dr. Duncan had alluded. If one ovary were left behind the effect was the same as if both were. The question of most importance discussed in Dr. Amand Routh's very interesting paper was

whether, in certain cases in which delivery through the abdominal wall was necessary, it was better to suture the uterine wound or to remove the uterine body by the retro-peritoneal method. Dr. Dakin related a case on which he had recently operated. The patient, aged 28, was sent to him in May of the present year. She was at just about term, a 2-para. Her true conjugate measured $2\frac{3}{4}$ inches, and in the previous pregnancy labour had been induced at about the sixth month, delivery being even then accomplished with difficulty. She was a fairly well-built woman, and her pelvis was otherwise of normal size. The head of the child was lying on the brim, and projected in front beyond the upper border of the symphysis. She was very anæmic, and had much œdema of the vulva and of the anterior abdominal wall just above the level of the head. She was prepared to run the risk of an abdominal operation to have a living child, but, when the situation had been explained to her, decided to be sterilised at the same time. Dr. Dakin, before operating, considered what method he should adopt, much on the same lines as argued by the author of the paper, and determined to wait until the abdomen was opened and the child extracted before deciding whether he would complete the operation by removing a length of each tube and suturing the uterine wound, or by amputating the body of the uterus. The placenta was found in the line of the uterine incision, and had to be removed, but the hæmorrhage from the cut edges of the placental site was easily arrested by pressure with a gauze plug. The vessels of the uterus were then seen to stand so clear of all obstruction to easy ligature, that he decided that it would be a much shorter procedure to remove the body of the uterus than to suture the uterine wound and to ligature and excise a part of each tube. The result was quite satisfactory, and the mother and child left the hospital in good health about five weeks after operation, convalescence having been interrupted only for a few days by some œdema of the left leg, due, no doubt, to a small thrombus.

When the Cæsarean section is completed in this way, the woman escapes certain risks to which she is liable when the sutured uterus is left behind; namely, those of infection of the peritoneum through an imperfectly sutured wound; adhesions of the uterus to the anterior abdominal wall, which may cause internal strangulation of the bowel; and the possibility of a recurrence of pregnancy from imperfect sterilisation. If the woman wishes to have a family all delivered through the abdominal wall it is another matter. There seems to be no amount of shock during or after operation when supra-vaginal hysterectomy is performed above that which may occur from an ordinary Cæsarean section; at all events the patient under dis-

cussion, who was not by any means an ideal case for abdominal section, suffered from none at all.

It seemed to the speaker that the best way was to wait until the child was extracted from the uterus before deciding how the operation should be finished in a case, that is where the woman desired to run no further risk of pregnancy.

Dr. Herbert Spencer thought that all would agree that the best operation had been done in this case of dystocia from fibroids, as a living child had been obtained and the mother had got rid of the tumours. Eight years ago he had himself performed Porro's operation for dystocia from fibroids, with a similar result ('Obst. Trans.,' vol. xxxvii). While the intra-abdominal treatment of the stump had the advantage of lessening the period of convalescence and the tendency to hernia, it was by no means free from drawbacks, as shown by the three cases published by Klotz, which all died of septic peritonitis (produced in the opinion of Klotz by infection of the silks through the vagina) within three years of the operation, and by the risk of adhesion to the seam causing intestinal obstruction, which had occurred in several cases, among them one of his own. He disagreed with the author's suggestion to perform the Porro operation in all cases of permanent obstruction, such as contracted pelvis. He thought the conservative Cæsarean section was the proper operation in these cases, but would have nothing to do with sterilisation by tying or cutting the tubes, which, besides exposing the patient to additional risks, was very unreliable in its effects, and was at least debatable from the moral standpoint. The conservative Cæsarean section was, when performed in a healthy subject, one of the most successful of all abdominal sections, and it had the great advantage over operations for the removal of tumours that there was no "stump" for intestines to adhere to, the wound in the puerperal uterus lying up against the abdominal wall and the uterus adhering in that situation, so that at a subsequent operation the general peritoneal cavity was slightly opened or not at all. He had recently performed Cæsarean section under local anæsthesia (Schleich's method) upon a patient whom he had delivered by Cæsarean section twice previously. The first two children had died of diarrhœa when they were two or three weeks old, and the third was now a fine healthy child, and the woman a happy mother, instead of being disconsolate, as she would have been had he removed the uterus, as recommended by the author. He had also successfully repeated Cæsarean section in another case.

Dr. Collingwood Andrews said that it had been his lot to use a Koeberte's serre-nœud a good many years ago, before the retro-peritoneal treatment of the stump had been suggested.

He would certainly never have recourse to the loop again, as he considered the later method to be greatly superior.

Mr. Butler-Smythe considered Dr. Amand Routh's modified operation to be essentially an operation for the hospital, where the operator would be himself experienced in abdominal surgery, and at the same time have the advantage of skilled assistants. He, Mr. Butler-Smythe, wished to ask Dr. Amand Routh if he advocated the performance of such an elaborate method by the medical practitioner at the bedside of some poor patient in country districts? With regard to cases of contracted pelvis, he hardly dared to venture an opinion as to what operation should be performed; but he certainly would prefer Cæsarean section. In a case complicated by fibroids, whether in the body or in the lower segment, he would advise the so-called Porro's operation, and, if the means were at hand, he would decidedly adopt the retro-peritoneal treatment, a method he hoped to see carried out in all future cases. The unfortunate part of the question was that no operator could settle on what he would or could do until he had opened the abdomen and uterus, and had extracted the child. It was then he would find that many of his elaborations would have to be modified. His first duty was to save the lives of the mother and child, the second to consider whether it would be wise to allow the mother to risk a second pregnancy. He considered the serre-nœud and elastic ligatures very useful adjuncts in emergency cases.

Mr. Targett referred to a case shown by him, see p. 242, in which he had performed abdominal hysterectomy for rupture of the pregnant uterus at term. The patient had had a Cæsarean section done two and a half years previously for impacted shoulder presentation, but she had not been sterilised. She was readmitted in a state of severe collapse, and on opening the abdomen the child and placenta were found free in the peritoneal cavity, and there was a large rupture in the anterior wall of the uterus along the scar of the previous operation. With respect to the questions raised by Dr. Routh's paper, he considered that a non-sterilising Cæsarean section was very rarely justifiable; while between a supra-vaginal hysterectomy and a Cæsarean section with sterilisation the balance would be usually in favour of hysterectomy, because it could be more rapidly performed, and prevented the risks of hæmorrhage and subsequent sepsis. When the pregnancy was complicated with fibroids the advantages of supra-vaginal hysterectomy were obvious.

The President observed that he had heard the dispute about nomenclature as long ago as 1881, when Sir Spencer Wells successfully performed what would now be called panhysterectomy, in the sixth month of pregnancy, for cancer of the cervix. The retro-peritoneal operation was best, provided that, as in

Dr. Amand Routh's case, the obstetrician had already performed it more than once on non-pregnant subjects and in hospital practice. Country practitioners with large midwifery practices but no experience of abdominal section have, as in a case within his own knowledge, had excellent results after the old Porro-Cæsarean operation, which was easy, and could be done quickly. On that account Lepage ('Annales de Gynéc. et d'Obstét.,' April, 1900) performed the old operation in a hospital on a case of labour at term and free hæmorrhage, saving mother and child; the fibroid was large. Weiss and Schuhl (*ibid.*) reported the removal of the uterus in two cases of spontaneous rupture during labour, both occurring in a hospital. In one case the elastic ligature and pins were used, and the patient recovered; in the second, which was lost, the retro-peritoneal operation was undertaken; but this case was septic. Panhysterectomy had the disadvantage of being yet lengthier than retro-peritoneal hysterectomy. The President considered that the question of the treatment of the ovaries in any kind of hysterectomy was still unsettled. He agreed with Dr. Herbert Spencer as to the liability to trouble from the ligatures in the stump in the retro-peritoneal operation. Hæmorrhage from too few ligatures was more dangerous than parametritis from too many.

In his reply Dr. Amand Routh agreed that the nomenclature was not altogether satisfactory, but thought that all cases of hysterectomy during late pregnancy (except panhysterectomy) were of the nature of a "Porro," the treatment of the stump being a detail capable of many renderings. He did not consider the old "Porro" operation was suitable for cases of advanced cancer of the cervix, owing to the great strain on the friable supra-vaginal cervix, which would almost certainly give way. He did not think it made any difference to the patient's after-history whether one or both ovaries were left. Most of the speakers had, with certain reservations, approved of his view that hysterectomy was in most cases preferable to Cæsarean section with sterilisation, and, as Mr. Doran stated, if haste was essential the old Porro was indicated, otherwise the modern retro-peritoneal hysterectomy. Dr. Herbert Spencer's contention that, wherever possible, Cæsarean section *without* sterilisation should be performed, so as to allow another pregnancy to occur, was not, in his opinion, justifiable. The patient might at full term be far away from skilled assistance, and would, moreover, run all the risks mentioned in his paper, both during the puerperium and subsequently. The adhesions, which Dr. Spencer stated occurred between the uterine and abdominal incisions, were one of the dangers, and involved the risk of intestinal obstruction. He preferred catgut to silk for suturing the muscle of the stump, owing to its quicker absorption, which

caused, therefore, a smaller chance of subsequent infection. He had not used the elastic ligature before tying the uterine vessels, but had tied or clamped these immediately after the child was extracted.

OCTOBER 3RD, 1900.

ALBAN DORAN, F.R.C.S., President, in the Chair.

Present—30 Fellows and 2 Visitors.

Books were presented by Dr. Galabin, the American Association of Obstetricians and Gynecologists, the Section on Gynecology of the College of Physicians of Philadelphia, the Copenhagen Medical Society, the Madras Government Maternity Hospital, and the Royal Medical and Chirurgical Society.

Ralph Henry Vincent, M.B., B.S. (Durh.), was admitted a Fellow of the Society.

Claude S. Hawkes, L.R.C.P. (Brisbane), and Jameson John Macan, M.A., M.D. (Cheam) were declared admitted.

The following gentleman was elected a Fellow of the Society :—Thomas William Shepherd, L.R.C.S. and L.M. (Launceston).

Report of Committee on Dr. H. R. Andrews's Specimen of Sarcoma of Uterus. (See p. 210.)

SECTIONS from various parts of the tumour show masses of small round-cells, with a few oat-shaped cells, in some

places showing a more or less alveolar arrangement, infiltrating the muscle-bundles. The growth is very vascular.

There is no doubt at all that the growth is sarcoma. There is no evidence of the sarcoma having started in a fibroid tumour.

Herbert R. Spencer.
T. W. Eden.
H. R. Andrews.

RUDIMENTARY SUPERNUMERARY DIGITS.

Shown by H. R. Andrews, M.D., M.R.C.P.

Dr. Andrews showed three specimens of what were apparently rudimentary supernumerary digits.

They were small ovoid bodies, about an inch and a quarter long and half an inch thick, resembling "snow-berries." The first was expelled from the uterus shortly after the birth of a male child, which presented by the breech. The arms were extended, and had to be brought down. Doubts as to its nature were cleared up by the fact that the next day an exactly similar body was found on the little finger of a new-born female infant, attached by a small thin pedicle. On examination of the first child's hand a small vascular stump was found at the root of the left thumb. The pedicle had evidently been torn through during the birth of the arm.

The two microscopical sections exhibited showed practically identical structures, a lining of skin with stratified epithelium, papillæ, myxomatous connective tissue, sweat-glands, and fat, with a small mass of cartilage in the middle with a strand of fibrous tissue attached to it. Skiagrams showed the bones of both infants' hands to be normal.

Dr. Andrews said he had been unable to find any account of similar bodies. Supernumerary digits were common, but such rudimentary specimens as those shown, having no trace of a nail, if they might be described as supernumerary digits, seemed to be uncommon, or at any rate not described.

A third specimen, exactly like the other two, had been sent to him by Dr. Sargent, who had removed it from the thumb of an infant.

In replying Dr. Andrews asked Mr. Targett if he knew of any book containing a description of similar tumours. Mr. Targett said that he did not.

Mr. Sherren said that in the early part of this year he had seen three similar cases. They were, as far as the naked-eye appearances went, exactly similar to the specimens shown. They were seen in young children, and were attached by narrow pedicles. One child had two such structures, one attached to the skin on the ulnar side of each little finger. In another case the body was attached in much the same position, and in the third child it was situated to the inner side of the great toe. All the cases were seen within a very short time of each other, and he had seen none before or since. Unfortunately none of the specimens were examined microscopically.

A CASE OF CANCER OF THE CERVIX ASSOCIATED WITH AN ADENOMATOUS GROWTH IN THE FUNDUS.

By C. Hubert Roberts, M.D., F.R.C.S., M.R.C.P.,

PHYSICIAN TO IN-PATIENTS, SAMARITAN FREE HOSPITAL FOR WOMEN, AND PHYSICIAN TO OUT-PATIENTS, QUEEN CHARLOTTE'S LYING-IN HOSPITAL.

(See Plate XX.)

The following case was briefly reported at the last meeting of the Obstetrical Society, but, owing to a suggestion from the senior secretary, Dr. Herbert Spencer, it is now reported more fully in a short communication.

Mrs. E. M. R—, aged 38, married fourteen years—one child seven years ago, one miscarriage twelve years ago, —a patient of Dr. Bloxham's, of Bath, was sent to the Samaritan Hospital, March 10th, 1900, for ulceration of the cervix uteri of a malignant nature, accompanied with hæmorrhage and fœtid discharge.

The history of the present trouble was that some discoloured discharge had been noticed about four months ago, and that it was at times foul; there had never been any severe hæmorrhage until Dr. Bloxham first examined her, shortly before she was admitted into the hospital. There had been no pain, and the patient appeared to be in good health; she had attached little importance to her symptoms.

On admission the general condition of the patient was very good, but on local examination, which caused severe bleeding, the cervix was found enlarged and excavated by a considerable mass of friable growth, evidently malignant; it occupied the canal of the cervix, and appeared to extend upwards towards the body of the uterus; the anterior lip was also somewhat involved. There was some doubt as to uterine fixity towards the right side of the pelvis, but on rectal examination no involvement of the utero-sacral ligaments could be made out.

The case appeared a very unsatisfactory one, both as regards operation and prognosis, and Dr. Amand Routh, who kindly saw the case with me, reported unfavourably upon it.

I decided to examine the case more carefully under an anæsthetic, and on March 12th, 1900, this was done; the uterus was then found to be mobile, and could be drawn down almost to the vulval outlet. The limits of the growth were now much more evident, and appeared confined to the endo-cervix as far as the os internum. Dr. Walter Tate, who kindly assisted, agreed with me that it was just possible to get the uterus away. I separated the bladder anteriorly after some trouble, as

C. Hubert Roberts del.

FIG. 1.

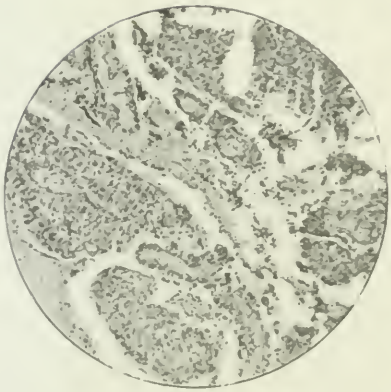

FIG. 2.

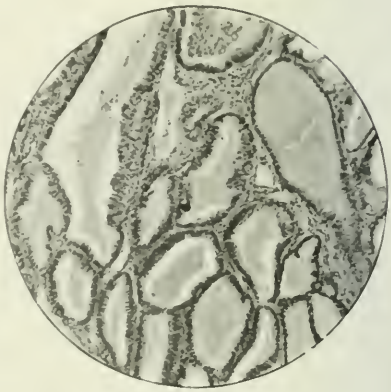

FIG. 3.

Illustrating Dr. HUBERT ROBERTS'S specimen of Cancer of Cervix, with Adenomatous Growth in the Fundus.

Bale & Danielsson, Ltd.

DESCRIPTION OF PLATE XX,

Illustrating Dr. Hubert Roberts's specimen of Cancer of the Cervix with Adenomatous Growth at the Fundus.

Fig. 1.—*a*. Fundus uteri.

b. Growth in fundus distinct from the growth which occupies the cervical canal.

c. Cervix uteri much expanded by a large mass of cancerous growth which is breaking down.

d. Mass of growth which occupies the cervix; under the microscope it is a columnar-celled carcinoma. The mass is fungating through the cervix below; above it extends as far as the os internum.

Fig. 2.—The growth is an atypical columnar-celled carcinoma, and large columns of cells are everywhere invading the tissue of the cervix. There is very active proliferation accompanied by hæmorrhages and vacuolation.

Fig. 3.—The growth is a simple adenoma composed of tubular gland-like spaces lined with a single layer of columnar epithelium containing many goblet-cells. Mucin is seen in the cavities of the glandular alveoli.

the shell of cervical tissue in front was certainly thin. After opening Douglas's pouch the broad ligaments were easily defined, and did not appear to be involved; they were ligatured carefully step by step on either side, and eventually I easily anteverted the fundus, ligatured the tubes and the remainder of the broad ligaments from above downwards, and removed the uterus without much difficulty; there was very little hæmorrhage. I closed the vagina to some extent by a stitch on either side, uniting the anterior and posterior vaginal flaps, plugging the central portion with iodoform gauze. The operation lasted forty-five minutes; there was very little shock. The patient subsequently did very well. She was very sick for three days, but the sickness ceased on the third day, when I removed the iodoform gauze plug; possibly some of the vomiting may be attributed to this, but it is not certain. The temperature never rose beyond 100·8°, and convalescence was rapid. She was discharged from the hospital on March 31st (nineteen days after the operation). I have since heard from Dr. Bloxham that her progress is satisfactory.

Pathology.—On cutting into the uterus it exhibited the characters seen in the accompanying drawing (see Plate XX), the whole cervix being filled with a mass of fungating cancerous growth, while the fundus was occupied by another mass of growth of an uncertain nature, but which has since been proved microscopically to be adenomatous. The whole uterus has somewhat enlarged, especially the cervical portion from the os internum downwards, below which the cervix is expanded to a marked degree by the cancerous growth, which has excavated and filled the entire canal of the cervix. This has not extended much into the vagina, and the growth is sharply limited at the region of the internal os. The cervix itself is severely infiltrated, only a thin shell of tissue being left in some places. The anterior lip is involved, but not the vaginal wall. The parametrium did not appear to be involved anteriorly, as the bladder stripped off very fairly easily;

and although the utero-sacral and broad ligaments did not feel thick, with such extensive disease of the endo-cervix I fear the growth will soon recur.

The chief interest of the specimen is, however, the growth occupying the fundus uteri, and which appears to have no connection with that occupying the endo-cervix. It consists of a localised mass of soft somewhat papillomatous growth at the summit of the cavity of the body of the uterus; it is sessile, and does not appear to infiltrate the walls of the uterus, but to be entirely limited to the endometrium, the whole being about the size of a hazel nut. The portion which extends into the cavity of the body of the uterus has the character of a soft warty papilloma. To the naked eye it did not appear to resemble the growth in the cervix; and the specimen was shown at the last Obstetrical Society's meeting as being of interest, in that the uterus showed a cancer of the cervix, while the body of the uterus was occupied by a growth of uncertain nature.

After the uterus had been hardened careful sections were made of the growth in the cervix, and also of the mass at the fundus.

I have to thank Mr. Corrie Keep, my colleague at the Samaritan, for some excellent sections; others being prepared for me by Dr. P. W. Andrewes, Lecturer on Pathology at St. Bartholomew's Hospital. Dr. C. H. Cosens has prepared the excellent micro-photographs which I now show.

Acting on the suggestion of the President, Mr. Alban Doran, Dr. Tate and Mr. Targett have examined the sections with me, and we have come to the following conclusions:

(*a*) *The growth in the cervix.*—This consists of an atypical spheroidal-celled carcinoma, probably originating in the glandular elements of the cervix. The growth is of a very malignant type, and there has been great proliferation and active infiltration. The individual cells are massed together in dense columns everywhere, and

there is very little intervening stroma; there are hæmorrhages amid the growth, and the surface towards the cavity of the cervical canal is undergoing degeneration. The walls of the cervix are extensively infiltrated. No glandular structures remain, the whole growth consisting of atypical spheroidal cells; in places the growth exhibits dense columns of cells, as are seen in epithelioma of the cervix, but no cell-nests can be found; and though the growth is atypical, it is most probably a columnar-celled carcinoma of glandular origin.

(*b*) *The growth in the fundus.*—Sections show that this growth is an adenoma, and that it has no connection with the cancerous growth occupying the cervix. It consists everywhere of pure columnar glandular epithelium, arranged in a tubular manner, exactly resembling a mucous polyp; there is very little stroma. The tubules are lined with a definite glandular epithelium, situate on a basement membrane. Many of the cells are goblet cells, and the lumen of many of the tubules is filled with mucin. There is no sign of infiltration where the adenomatous growth joins the muscular wall of the uterus, though careful serial sections were made to determine this point. We are, therefore, of the opinion that the growth is a simple adenoma, and that it has no connection with the growth in the cervix.

Remarks.—The specimen is of some interest, as it was thought at first that the growth at the fundus was of a malignant nature; but it was difficult to explain how such a separate mass of growth could exist apart from direct extension from the cervix.

The growth in the fundus proved to be adenomatous, and the interest of the specimen devolves on this point, for at present there seems to be great confusion on the subject of adenoma of the uterus, and more especially on the relation of adenoma malignum to cancer.

Adenoma of the uterus may occur either in the cervix or the body; its simplest forms occur as erosions (so called) and simple mucous polypi, the latter occurring

either in the cervix or the body; text-books generally limit mucous polypi to the cervix, but the author has frequently found them in the body of the uterus in association with fibroids, and even with cancer of the cervix, as in the case now related.

Such adenomata appear simple in character, and generally exhibit definite glandular structures, consisting of tubular glandular epithelium, the lumen of such cavities being frequently distended with mucin. Whether such simple adenomatous growths have any connection with cancer is uncertain, though Sir John Williams ('Cancer of the Uterus,' pp. 29 and 72) reports a case where cancerous changes commenced in a mucous polyp, and suggests that internal polypi in advanced age are apt to be malignant, and whenever they are removed they should be examined as to their true character.

Another type of adenoma affecting the cervix is that in which actual glandular invasion of the tissues of the cervix takes place, and which it is difficult to distinguish from a true malignant process. Sir John Williams describes such a case in his work on 'Cancer of the Uterus' (p. 42). Dr. R. J. McCann exhibited a similar specimen at the Obstetrical Society in January, 1898 ('Trans. Obstet. Soc.,' vol. xlii, p. 2). Dr. Eden also showed a very similar specimen, in which the cervix was deeply invaded by glandular structures, though apparently of a simple nature. Winckel ('Lehrb. der Frauenk.,' 1886, p. 430) describes a similar condition as adenomyxoma of the cervix.

In St. Bartholomew's Hospital Museum is a specimen, No. 2960 (B), which is apparently a cervical fibroid, everywhere riddled with cystic cavities, lined with a definite columnar epithelium. Much depends in such cases on the after history, and if not actually malignant, such adenomata seem to be on the borderland of that condition.

With regard to adenoma of the body of the uterus, great confusion exists. Localised simple mucous polypi

are common; other conditions are classed under the heading "Endometritis," which, unless we define what we mean, is a term which is most misleading (Dr. Herman, 'Clin. Journal,' April 15th, 1896, and 'Diseases of Women,' p. 458). The author agrees most emphatically with Dr. Herman that the conditions of the endometrium associated with overgrowth, which is really adenoma of the body of the uterus, must be distinguished from inflammation and atrophy of the mucosa.

Some conditions associated with overgrowth of the endometrium are purely adenomatous; others again, especially in elderly women, may recur, and are malignant.

Dr. Amand Routh ('Trans. Obst. Soc.,' vol. xxxix, p. 5) described a malignant papilloma of the body of the uterus on which Mr. Targett reported, which invaded the uterine wall, showing the tendency which simple adenomata and papillomata have to become malignant when affecting the uterus.

With regard to such conditions, a mere piece from the surface of such a growth, removed by a curette, is often misleading; it may appear to be an "adenoma benignum," but implication of the walls of the uterus by glandular invasion may be going on, and such groups of gland elements invading muscular tissue are to be looked on with extreme suspicion. If such evidence cannot be obtained by the microscope, clinical evidence is sometimes forthcoming, in that the disease returns, and it is more than probable that such growths have ceased to be benign, and are essentially malignant, and at present it seems extremely difficult to make any definite distinction between adenoma malignum and cancer proper.

The PRESIDENT said that it was clear that two different forms of new growth had developed in the same uterus. The tumour in the body was a pure adenoma according to its microscopical appearances, but to the naked eye it looked malignant. Much

remained to be learnt about the earliest stage of cancer of the uterine body.

Dr. A. H. N. Lewers said he had met with a case presenting all the characters clinically of cancer of the cervix, in which the microscopic examination merely showed large cavities lined by a simple layer of columnar epithelium. Supra-vaginal amputation of the cervix was performed. For a time the patient remained well, but about a year after the operation the disease recurred in the scar, and before long there was a large typically malignant ulcer at the top of the vagina. As regards the cause why the uterus was fixed in advanced cancer, Dr. Lewers believed the principal cause was extension of the malignant growth to the tissues in the neighbourhood. This seemed proved by cases where, as the impairment of mobility was only slight, an attempt was made to remove the uterus. In several such cases the operation discovered infiltrated tissue beyond the uterus, at the situation where the mobility of the uterus appeared to be checked.

After some remarks by Dr. W. S. A. Griffith upon the nature and significance of peri-uterine induration in cases of presumably operable uterine cancer,

Dr. Amand Routh alluded to a case of papilloma of the body of the uterus in which he had curetted the uterus three times, and had eventually removed the uterus, feeling that, although the microscopical sections of the scrapings were simple papillomata, recurrence proved its malignant nature. On removal, papillomatous processes were found to have invaded the uterine muscle almost as far as the peritoneum. He believed that any definite growth developing in the body of the uterus was malignant in type if it occurred after the menopause, and should be treated as such. He disagreed with Dr. Griffith as regards operating on cases of cancer of the cervix, and preferred to leave cases alone if the broad ligament or utero-sacral folds were involved. Cervical epithelioma did not, as a rule, spread anteriorly.

Dr. Herman could not agree with Dr. Griffith that fixation of the uterus in early cancer was often due to adhesions. He agreed with Professor Sinclair, of Manchester, that the usual direction of extension of uterine cancer was into the cellular tissue of the utero-sacral ligaments. The situation of the induration due to spread of cancer in this direction was different from that of induration from pelvic peritonitis. In some doubtful cases in which he had commenced operation, but found that there was too much extension of cancer laterally for the operation to be completed, he had opened Douglas's pouch, and found it free from adhesions. He had seen cases of large adenomatous polypoid growth in the uterus recurring again and again after removal; and the macroscopical signs

of such growths were distinctive; they were not solid, friable tissues, like cancer, but pulpy, gelatinous, translucent stuff. When such recurrence took place more than once he thought hysterectomy indicated.

Dr. Herbert Spencer thought the report of the case a most valuable one. It clearly showed the association of a simple adenoma of the body with cancer of the cervix. He had no doubt that these adenomata had often been described as secondary deposits of cancer. Ruge and Veit's case ('Krebs der Gebärmutter,' fig. 34) was, in his opinion, erroneously so described. Cases of simple adenoma of the body had often been removed for cancer. He had met with simple adenoma in old women, even recurring after curetting, and yet the patient remaining well and the uterus atrophying after as long as six years from the second curetting. The diagnosis between these cases and cancer was often very difficult.

In reply, Dr. Roberts thanked the various speakers for their criticisms. With regard to Dr. Lewers' case of suspicious recurrent adenoma, Dr. Roberts thought total hysterectomy would have been a better proceeding than supra-vaginal amputation. Dr. Griffith spoke of fixation, and the possibility of adhesions being even a cause of fixity. Dr. Roberts thought it was impossible, on clinical examination, to say whether in doubtful cases, where an operation was undertaken, such fixation was inflammatory or cancerous, but he regarded a case where the uterus would not come down on traction with a volsella owing to parametric invasion as an unsuitable case both in the matter of operation and prognosis.

Dr. Roberts referred to Cullen's work on 'Cancer of the Uterus' for many valuable pictures and sections of adenoma of the uterus. With regard to adenoma of the body of the uterus, many cases were of a semi-malignant nature, and in old women, should this condition recur after curetting, vaginal hysterectomy was the best proceeding; mere curettings for microscopical examination were often misleading.

FULL-TERM PREGNANCY IN A RUDIMENTARY HORN OF UTERUS; MISSED LABOUR (FIVE MONTHS). ABDOMINAL SECTION AND REMOVAL OF SAC. RECOVERY.

By J. H. Targett, M.S.

(See Plates XXI and XXII.)

The patient was a primipara, aged 29, who was married in May, 1899. Menstruation ceased in the third week of June, 1899, and she expected her confinement at the end of March, 1900.

In November, 1899, she was attended by a doctor for pain in the left iliac region, which readily yielded to palliative treatment. At the beginning of April, 1900, she had attacks of abdominal pains, which were forcing in character, and she thought herself in labour, but there was no hæmorrhage from the vagina. In May, 1900, she had a sudden "flooding" from the vagina, but it was not severe; the hæmorrhage continued more or less throughout the month, and was at no time profuse. The discharge was dark, and did not contain clots or membranes. It ceased at the end of May, and from that time the patient noticed that the abdomen and breasts were getting smaller. Fœtal movements ceased in April, at the time when she thought herself in labour. Throughout the pregnancy the patient had enjoyed good health, and had been able to attend to her household duties. There was no trouble with micturition or defæcation.

On admission.—The patient presented herself casually at the hospital, because her friends told her she must have gone over her time. She appeared in excellent health, and had never consulted a doctor since November, 1899.

The abdomen was enlarged to about the size of an eight-months' gestation. It was occupied by a well-defined tumour, which was a little more prominent on

the right side, and felt harder than the pregnant uterus. Its consistency varied on palpation, but no distinct parts of a fœtus could be made out even when relaxed, and there was no fluctuation. Nothing was heard on auscultation. Measurements showed that the greatest circumference of the abdomen was a little below the umbilicus, and the distance from the umbilicus to the anterior iliac spine was a quarter of an inch greater on the right side. Resonance in both loins good, and it extended farther forwards on the left side to a point well in front of the iliac spine.

The breasts were quite flabby and contained no secretion, but the secondary areolæ were well developed.

Vaginal examination.—Cervix directed backwards, not softened nor dilated. It was connected with a distinct rounded body, which was pushed over to the left side of the pelvic cavity by the abdominal tumour. The lower rounded end of the abdominal tumour was felt through the anterior and right fornices, but it did not come very low down into the pelvis. The sound passed three inches into the smaller pelvic tumour, which was continuous with the vaginal portion of the cervix, and seemed therefore to be the body of the uterus.

Diagnosis.—As the case was clearly one of missed labour from extra-uterine gestation, the chief point for consideration was the situation of the sac. I came to the conclusion that it was in a rudimentary horn of the uterus, because the tumour was well defined and surrounded by muscular tissue which gave rise to intermittent contractions. Moreover, the cervix was directly connected with a small body which was quite distinct from the main abdominal tumour, and admitted the sound like the normal body of the uterus.

Against the gestation being intra-ligamentous was the fact that the tumour did not come low down into the pelvic cavity, the parts of the fœtus could not be felt through the thick-walled sac, and the body of the uterus was separate from the sac and very little enlarged.

There was no history of rupture or severe illness, such as would be expected in the course of a tubal gestation.

Abdominal section (September 8th, 1900).—A median incision was made from three inches above to three or four inches below the umbilicus. The abdominal wall was very vascular, and was found to be firmly adherent to the gestation sac. A large area of the front of the sac was exposed and then incised, liberating a small quantity of liquor amnii, which was of a greenish-brown colour. The fœtus was lying somewhat transversely with its right shoulder in front, the head to the left, and the breech to the right, but below the level of the head. The fœtus was extracted by the breech, and the cord was so rotten that it broke off at the placental attachment on very slight traction. There was very little bleeding from the cut edge of the sac, and none from the ruptured cord. The placenta was firmly attached to the posterior surface of the sac; it was yellowish in colour, and the amniotic surface was stained an olive green, like the fluid contents of the sac. Attempts were made to detach the placenta and membranes, but it was so firmly adherent that this proved a very tedious step. Moreover, I found that on pulling forwards the adherent placenta, with a view to detaching it, the posterior wall of the sac came forwards so freely that it became practically certain the sac was not adherent posteriorly. Hence it was determined to attempt the removal of the entire sac. Adhesions were cautiously separated at the upper end of the sac until the general peritoneal cavity was opened. Here the omentum was extensively blended with the sac, and had to be tied off in sections; but when this was done the hand could be passed in behind the sac, the back of which was free from adhesions. A very extensive area of the anterior abdominal wall had still to be detached from the sac before the latter could be drawn out of the incision. On exploring the pelvis a uterus was felt on the left side, and a thick band of tissue connected it with the gestation sac. Both sets of appen-

dages were seen, and the diagnosis of pregnancy in a rudimentary horn of the uterus was confirmed. The pedicle was very broad, but not thick, except at the uterine border, where it included the muscular tissue connecting the gestation sac with the left uterine body. This pedicle was ligatured in four sections first, and then tied by two separate interlocking ligatures. The raw surface of the pedicle was then closed by a continuous suture of the peritoneal edges, as after hysterectomy. There was a little oozing from the extensive abdominal adhesions, but it was stopped by pressure and small ligatures. The patient stood the operation well, and the pulse was good throughout.

For the first few days after the operation there was much sickness and flatulent distension, which was eventually relieved by repeated enemata, and after that the convalescence was uninterrupted. The pulse and temperature were good throughout, and the wound healed by primary union.

The child was a full-term male with no deformities. It measured nineteen inches, and weighed 4 lbs. 9 oz. The epidermis was peeling, and the surface was covered with orange-coloured vernix. There was no smell like putrefaction about the child or the placenta. The head and abdomen were much shrunken, the subcutaneous fat was orange-coloured, the muscles were normal, and there was no adipocere. The small weight of the child was probably due to absorption of fluids.

Description of specimen.—The general features of the specimen are shown in the accompanying photographs. The gestation sac, after contraction and retraction of its walls, and some shrinking due to preservation in formalin, measures 7½ inches by 6 inches in its two chief diameters, and about 3½ inches from before backwards. It has a somewhat pyriform outline, but is much flattened antero-posteriorly. The anterior and superior surfaces are thickly covered with adhesions, by which the sac was united to the anterior abdominal wall and the omentum; the

posterior surface, however, is almost free from adhesions. The wall of the sac varies considerably in thickness. At the lower end it measures one-third inch in thickness; but above the wall is so thin that it was easily torn in separating the adherent omentum, and here the muscular tissue in the wall is reduced to a very thin layer. The pedicle of the sac may be described as consisting of three elements—the right broad ligament, the right round ligament, and the uterine pedicle or attachment.

(*a*) *Right broad ligament.*—The relations of the different structures to the gestation sac are indicated in the photographs. The right Fallopian tube, meso-salpinx, and ovary, are normal. The tube measures 4½ inches, and its attachment to the gestation sac is 2 inches from that of the right round ligament, on a higher level, and to the outer side of the latter. The ovary is much elongated, and its ligament joins the sac 1 inch from the uterine pedicle on the posterior aspect of the specimen.

(*b*) *Right round ligament.*—This important landmark is placed at the extreme lower limit of the sac, and before removal of the sac this ligament seemed much more to the outer side than would have been expected. There is an interval of 2½ inches between it and the top of the uterine pedicle. The uterine vessels reached the side of the gestation sac at a point (indicated in the photograph) a little above and outside the attachment of the round ligament.

(*c*) *Uterine pedicle.*—By this is meant the bond of union between the gestation sac and the opposite (left) body of the uterus, and its site is marked on the photograph of the back of the specimen. The cut surface of this pedicle measures 1½ × 1 inch, and is seen to consist of dense muscular tissue traversed by many small vessels. The superficial fibres of the pedicle form a series of arches where they expand over the lower segment of the sac. There is no trace of a uterine canal to be found in the cut surface of this pedicle.

DESCRIPTION OF PLATE XXI,

Illustrating Mr. Targett's specimen of Full-term Pregnancy in a Rudimentary Horn of Uterus.

FRONT VIEW OF GESTATION SAC.

s. Summit of sac.
c. Umbilical cord protruding from an incision in the sac.
r. Right Fallopian tube.
o. Right ovary.
g. Right round ligament.
x. Site of right uterine vessels where they reach the wall of the sac.

Illustrating Mr. TARGETT's specimen of full-term Pregnancy in a Rudimentary Horn of Uterus.

Bale & Danielsson, Ltd.

DESCRIPTION OF PLATE XXII,

Illustrating Mr. Targett's specimen of Full-term Pregnancy in a Rudimentary Horn of Uterus.

BACK VIEW OF GESTATION SAC.

r. Pedicle of muscular tissue connecting gestation sac with left body of uterus.

For other letters see description of Plate XXI.

Illustrating Mr. TARGETT's specimen of full-term Pregnancy in a Rudimentary Horn of Uterus.

Bale & Danielsson, Ltd.

The PRESIDENT remarked that Mr. Targett's specimen reminded him of his own case where he removed a fibroid from the undeveloped cornu of a uterus unicornis ('British Medical Journal,' vol. i, 1899, p. 1389). He found the round ligament on the outer side, as it must of necessity be found in all cases of tumour, hæmatometra, or pregnancy in an undeveloped cornu. He noted in the original report how prominent the uterine artery was; it ran in the broad ligament from below upwards into the outer side of the tumour. He would like to hear if Mr. Targett had any difficulty with the uterine artery at his operation. In a tubal gestation sac or tumour the trunk of the uterine artery lay far from the line of incision through the pedicle.

CARCINOMA * OF THE BODY OF THE UTERUS.

Shown by J. H. TARGETT, M.S.

* The author's surmise that the specimen was squamous epithelioma of the body was not supported by his further investigation.

ON SUBCUTANEOUS SYMPHYSIOTOMY.

By G. Ernest Herman, M.B.Lond., F.R.C.P., F.R.C.S.,

SENIOR OBSTETRIC PHYSICIAN TO THE LONDON HOSPITAL; LATE PRESIDENT OF THE SOCIETY.

(Received September 17th, 1900.)

(*Abstract.*)

The author points out the advantages of the subcutaneous method of operation, viz. simplicity, quickness, small risk of sepsis, insignificant hæmorrhage, absence of a gaping wound, and of a subsequent scar.

He urges that if the maximum benefit from symphysiotomy is to be secured, it should be done under the most favourable conditions. It ought not to be postponed until the necessity for some kind of operative delivery has been demonstrated by the complete failure of the natural powers. The accoucheur should ascertain the size of the pelvis before labour, and estimate also the size of the child. If he decide upon symphysiotomy, it should be done at the most favourable time, that is, immediately after full dilatation of the os uteri. The frequency with which in contracted pelves the membranes rupture prematurely, will make the dilatation of the cervix with Champetier's bag usually advantageous.

The author points out that the one risk at present inseparable from symphysiotomy is that of injury to the urethra; and that this is likely to happen in cases in which an attempt is made to deliver by symphysiotomy a child too large to be delivered in that way, and thus the pubic bones are excessively separated.

This is to be guarded against by carefully estimating the size of the child beforehand.

I MAKE this communication to the Society, because the operation of subcutaneous symphysiotomy has not yet been discussed by it, and it is an operation which ought to be known and appreciated.

I first relate three cases.

CASE 1. *Generally contracted and flat pelvis; two former pregnancies; in both death of child during delivery; third pregnancy; delivery of living child at term, by subcutaneous symphysiotomy; recovery.* (Reported by Dr. F. T. Waldron, Resident Accoucheur, and Mr. J. H. Philbrick, Clinical Clerk).—E. W—, aged 28, was admitted into the London Hospital under my care, on January 3rd, 1899.

She was married at 19. Her first child was born dead, with its head much deformed. The labour lasted thirty-six hours; the head presented; the cord came down when the membranes ruptured, and the doctor could not make it keep up. No instruments were used. This was two years ago. The second child was born dead at seven months' pregnancy. Labour was not induced. Its premature onset was attributed by the patient to a fall on the abdomen a month before. The head presented, and as in the patient's first labour, the cord came down. No other pregnancy.

The patient's last menstruation ceased in the third week of March 1898.

The following were her pelvic measurements:

Anterior interspinous	$9\frac{1}{4}$ inches.
Intercristal	$10\frac{1}{4}$,,
Posterior interspinous	$4\frac{1}{2}$,,
External conjugate	$7\frac{1}{8}$,,
Diagonal ,,	$3\frac{3}{4}$,,

The head was presenting, but was not engaged in the pelvic brim, and could not be pressed into it. With two

fingers in the vagina, the ilio-pectineal line could easily be followed all the way round.

On January 3rd, at 9 p.m., a bougie was passed into the uterus and left there.

On January 5th there had been no labour pains, and therefore, at 11 a.m., the bougie was removed, and a sponge-tent inserted.

On January 6th, there had been but few labour pains, and the tent was tightly gripped by the os uteri. At 10.45 a.m, it was removed, and Champetier de Ribes's bag introduced without difficulty, the membranes being unruptured. Labour pains rapidly came on. At 2.15 p.m., the bag was expelled.

The patient was with as little delay as possible anæsthetised. The genitals were shaved, and as far as possible sterilised. A sharp-pointed tenotomy knife, having a blade an inch long, and an eighth of an inch in diameter, was inserted opposite the middle of the symphysis pubis. The joint was easily penetrated, and divided by cutting first down, then up. When the section was complete, the two pubic bones sprang about an inch asunder. The membranes were then ruptured, and the cord immediately came down. The axis traction forceps was applied to the head, which was lying with the occiput behind. By pulling the head was delivered, with the occiput still behind; it did not rotate. The gap between the pubic bones widened to about two inches while the head was passing. The placenta was expressed about ten minutes afterwards. The innominate bones were then pressed firmly together; strapping applied to hold them together; and over this a binder of strong unyielding material was tightly applied.

The child weighed 6 lbs. 7 oz. The following measurements of its head were taken forty-eight hours after birth.

Sub-occipito-frontal . . .	$3\frac{3}{8}$ inches.
Occipito-frontal	$4\frac{1}{4}$,,
Mento-vertical	$4\frac{3}{4}$,,

Cervico-vertical . . . . $4\frac{1}{3}$ inches.
Bi-parietal . . . . $3\frac{1}{3}$ „

The lying-in was free from fever. The binder was tightened daily. During the first week, the patient complained of aching pains across the pubes, becoming sharp and cutting when she coughed.

On the eighth day the patient complained that her water ran away without her knowing it.

The lochia ceased on the thirteenth day.

On the twentieth day the patient stated that she had pain neither on coughing nor straining, nor at any other time. Her water escaped involuntarily when she coughed; but excepting for this she could retain it so long that the need for micturition occurred only three or four times in the day.

On the twenty-second day even this impairment of control over the bladder had ceased.

The patient got up on the thirty-third day after delivery.

On Feb. 20th, the forty-fifth day after delivery, it was noticed that the patient could stand without pain; but could not, when up, retain her urine, although she could when recumbent. A soft catheter went easily into the bladder. There was no cystitis, and no perceivable injury of bladder or urethra, except that it was thought by some that the clitoris, labia minora, and meatus urinarius, were lower down than normal, and the subpubic tissue more lax. But as no measurements of the position of these structures had been made before delivery, it was not possible to be certain of this.

On Feb. 25th the patient left the hospital.

On May 4th she came back again, complaining that she still could not properly retain her urine while she was up, although she could retain it perfectly while in bed. She was admitted, and I contemplated injecting some solution of quinine into the cellular tissue between the urethra and the symphysis pubis, in imitation of the practice proposed by Dr. Inglis Parsons for the cure of

prolapse. But while the patient was in the hospital, although she was up and about all day, there was no want of control over the bladder ; and therefore nothing was done, and the patient was discharged on May 14th.

The patient came back again in July, 1900 ; she still said she could not hold her water ; but the passage of a catheter showed the presence of a fair quantity of urine in the bladder, and nurses who were directed to examine the patient's underclothing reported that it was not wet. I conclude that the bladder is a little more irritable than it was before the operation, but that the patient exaggerates when she says that she cannot hold her water.

Case 2. *Flat rickety pelvis, conjugate about two inches and three quarters ; subcutaneous symphysiotomy at full term ; child living ; perfect recovery.*—In this case the operation was performed at the patient's own home, a working man's cottage. Mrs. R—, aged 31, of short stature, deaf, and almost dumb. She had had, two years ago, a child born at six months and a half pregnancy, which only lived a fortnight.

At the end of her second pregnancy labour pains began on September 18th, 1899, at 8 p.m. She sent for Dr. W. B. Dove, of Northwood, where she lived. He found a flat rickety pelvis, the diagonal conjugate of which measured three inches and a quarter ; and asked me to see the patient.

On September 19th, at 3.30 p.m., I performed subcutaneous symphysiotomy, in the same manner as in the last case, with the assistance of Dr. J. R. B. Dove and Dr. W. B. Dove. Labour pains were recurring vigorously. The head was above the brim, not pressing into the os ; and the cervix was hanging down into the vagina, having been incompletely dilated by the bag of membranes, which had ruptured. With forceps a living male child, weighing $7\frac{3}{4}$ lbs., was delivered, the chief difficulty being the stretching open of the cervix uteri.

The trochanters were pressed together with strapping,

over which a binder of strong huckaback towelling was drawn tight.

The patient's recovery was uninterrupted. She was in bed thirty days.

On Nov. 11th Dr. Dove wrote,—"There is no pain either during or after walking. She nurses the child in her arms for hours (and it is now a very large one) without feeling any discomfort. From the first day she put her foot to the ground to this she has had no discomfort whatever."

Case 3. *Generally contracted and flattened pelvis; two children born dead and one prematurely; fourth pregnancy; subcutaneous symphysiotomy at term; living child; recovery.* (Reported by Dr. Gordon Wilson, Resident Accoucheur, and Mr. MacDowall, Clinical Clerk.)—S. K—, aged 34, was admitted into the London Hospital on February 12th, 1900.

She had had three children: the first was delivered by forceps dead; the second was destroyed during birth. In her third pregnancy labour was induced at seven months, on July 21st, 1898, by the introduction of a bougie. Delivery was natural, and the child was born alive, but only lived twelve hours.

The following were the patient's pelvic measurements:

Anterior interspinous . .	$8\frac{1}{4}$ inches.
Intercristal	$10\frac{3}{4}$,,
External conjugate . . .	7 ,,
Diagonal ,, . . .	4 ,,

The patient last menstruated from May 10th to 14th, 1899. On February 12th her greatest girth was $37\frac{1}{2}$ inches; the measurement from the symphysis pubis to the top of the uterus, over its convexity, 14 inches. The head was presenting, but its equator was above the pelvic brim, and could not be pressed down into it.

On the evening of February 12th a bougie was passed into the uterus and left there. On February 13th, at 10.30 a.m., the os uteri was found to be the size of a

shilling. Champetier de Ribes's bag was put in; it was expelled about two o'clock. The patient was anæsthetised with as little delay as possible, and subcutaneous symphysiotomy performed in the same way as in the two former cases. When the symphysis had been divided, the bones at once diverged about an inch. The head was lying transversely. The ordinary forceps was applied, and the head easily delivered, the occiput being guided forwards by the forceps. Strapping and a binder were applied as in the former cases.

The child, a female, weighed 7 lbs. 10½ oz., and was 19½ inches in length. The following were the measurements of its head taken shortly after delivery:

Vertico-mental	5 inches.
Occipito-frontal	4⅝ ,,
Sub-occipito-frontal	4⅛ ,,
Bi-parietal	3⅜ ,,
Bi-temporal	3 ,,
Bi-mastoid	3 ,,

The day after delivery the patient complained of a little aching in the pelvis.

There was retention of urine, requiring the catheter, during the three weeks following delivery.

On the fifth evening the temperature was 100°, on the sixth 100·6°, on the eighth day there was a rigor, and the temperature rose to 105°. Next day the temperature was 100°, and herpes labialis had appeared. The cause of this rigor was not discovered. With these exceptions the lying-in was free from fever.

The patient sat up in bed at the end of four weeks, and got up at the end of five weeks.

She left the hospital well and able to walk without trouble on March 23rd, thirty-eight days after the operation.

In four cases since the one just described, delivery has been effected by symphysiotomy in the London Hospital. In one the operation was performed by Dr. H. R. Andrews, Obstetrical Registrar, and in the other

three by Dr. R. C. B. Wall, Resident Accoucheur. In none was there any difficulty in finding or dividing the symphysis pubis. All the patients recovered without bad symptoms, and left the hospital able to stand and walk, and with full control over the bladder. One patient got up on the twenty-fifth day, before she had received permission to do so, and without any resulting impairment of her power of locomotion.

In estimating the place of symphysiotomy among our obstetrical resources, we have to consider: (1) its advantages; (2) its possible ill results.

As to the first I have nothing novel to say. It is now established that by symphysiotomy the conjugate diameter of the pelvis can be enlarged by half an inch. Hence in pelves with conjugates from $2\frac{1}{2}$ to $3\frac{3}{4}$ inches in length it will often be the case that labour at term will be tedious, and dangerous to the life of the child; while by symphysiotomy the birth of a living child can be made easy. The limits I have given are outside those usually stated, but I submit that they are in accordance with clinical facts. A rule cannot be laid down based solely on the size of the pelvis, because the difficulty of delivery depends on the relation of the size of the child to that of the pelvis. A pelvis having a conjugate of $2\frac{1}{2}$ inches may, when enlarged by symphysiotomy, allow a small child to be born living, while with a very large child a pelvis having a conjugate of $3\frac{3}{4}$ inches may need enlargement.

The risks of ill results are lessened when the operation is performed subcutaneously; asepsis is more easily secured; bleeding is trifling; stitching is not needed; the duration of the operation is short. The formidable appearance of symphysiotomy by the open method, the large wound, free bleeding, many stitches (not to mention the wiring of the bones which some have practised), the need for careful preparation and skilled assistance, are features of the operation which would have made most private practitioners avoid it if they

could. By the subcutaneous method a tenotomy knife is the only instrument needed beyond the midwifery forceps and a dilating bag, and the duration of the operation is a minute or two. The risk of sepsis and of hæmorrhage seems to me not greater than that attending labour with contracted pelvis treated in other ways. The abundant experience of Pinard is enough to show that the symphysis unites firmly within a month.

It is, I think, desirable in most cases to use Champetier de Ribes's bag. The membranes will often rupture early, and then the head will be prevented by the pelvic contraction from coming down into the os to dilate it; thus delivery will be delayed while the os uteri is being stretched open, first by the forceps, and then by the head. Dilatation in this way, by a stretching force applied during the earlier part of the dilatation at two points only, is more likely to tear the cervix than the equable pressure of a water-bag. If the os has been previously dilated to its full size by Champetier's bag, the head can be delivered within a few minutes after the section of the symphysis.

Examination of the published records of symphysiotomy leads me to the conclusion that there is but one serious ill result which we know not how to prevent, viz. that of injury to the urethra. Lepage* relates a case in which there occurred a tear in the vagina through the vestibule into the wound, and during convalescence there was cystitis and incontinence of urine, which was recovered from after seven weeks. In another case there was incontinence of urine from a utero-vesical fistula; this, however, the reporter attributes to the use of forceps before the operation, and as it is difficult to understand how symphysiotomy should produce a utero-vesical fistula, I think him probably correct.

Benet † says of a patient that she "has only a little

* 'Annales de Gynécologie,' 1896, vol. xlv.

† Ibid., 1893, vol. xxxix.

incontinence of urine, but cicatrization and consolidation are perfect."

Pinard * mentions one case in which there was a tear laying open the bladder, and another in which incontinence of urine followed.

A fatal case published by Tellier † is unique. The pelvis had a diagonal conjugate of $4\frac{1}{5}$ inches (10·75 cm.). An artery the size of the radial was wounded. The pubic bones were separated 4 inches (10 cm.), and there was a tear of the urethra and base of the bladder the size of a two-franc piece. I cannot help inferring that this case was one unsuited for symphysiotomy, and that the patient ought to have been delivered by Cæsarian section.

Müllerheim published in 1894 an excellent lecture ‡ on symphysiotomy, in which he has collected much valuable information, and has defined certain indications for symphysiotomy. I am not clear whether he is expressing his own views, or only representing what he takes to be current opinion. But whichever it be, I differ from him; I might almost say that in my opinion he has in the passage I shall quote defined the circumstances in which symphysiotomy ought *not* to be performed:

"In many quarters the operation is done simply because labour has lasted long, without regard to whether the child is living or not, without judgment whether indications for terminating the labour are present or not! In primiparæ we should first wait to see whether the strength of the pains and the moulding of the fœtal skull, by flattening and over-riding of the bones, can overcome the disproportion between the maternal pelvis and the fœtal head. In rightly-exercised patience lies great obstetric skill. If an indication arises for the termination of labour, the head being moveable, the first thing should be an attempt to draw the head into the

* Ibid., 1897, vol. xlvii.

† Ibid., 1893, vol. xxxix.

‡ Volkmann's 'Sammlung,' No. 91, 1894.

pelvic brim with Tarnier's forceps. If careful attempts fail, then perforation may be mentioned. If the mother and her family reject the sacrifice of the child, then symphysiotomy steps in. But there must be a limitation. Symphysiotomy should never be done in a first labour. A first labour is a trial labour. Our methods of pelvimetry cannot yet be regarded as exact. Even if ability in this department can be trusted to, we are not able with certainty to measure from without the size of the fœtal head. Nor can the strength of the pains be measured. A woman who has already been long in labour and is exhausted, gets all her strength back after a short refreshing sleep, and spontaneously expels the child, to the astonishment of the doctor. Cases are not quite rare in which even experienced accoucheurs have prepared for Cæsarian section, but the woman has expelled her child without help before the preparations for the operation were completed. But if in the patient the disproportion between the pelvis and the fœtal head has been shown in one or more labours, if the muscle of the uterus has once shown itself to be insufficient to overcome the hindrance to delivery, then we can assume with the greatest certainty and correctness that spontaneous delivery cannot take place. Added to this is the fact that with increasing number of pregnancies the size of the fœtal head increases."

I think (in opposition to the foregoing quotation) that to get the best results from symphysiotomy, the necessity for it should be found out early in labour, or still better, during pregnancy; and the operation done before the patient is exhausted, and her soft parts damaged by protracted labour and futile attempts at delivery. I cannot understand a competent person examining the abdomen of a pregnant woman and failing to discover the need for Cæsarian section.

Although the size of the pelvis, and the size of the child, and their relation to one another, can only be measured approximately, yet I think that a person of

ordinary skill and intelligence can form an approximate judgment as to the relative size of the pelvis and child which is a far better guide to the probable ease or difficulty of delivery than any history of the course of past labours. The only history of a labour that is of real value, is that of one watched throughout by a trained observer, who after delivery measured both pelvis and child. The facts known about such a labour only inform us as to the pelvis; they cannot enable us to predict the size of a future child. The duration of labour is affected by so many conditions, that I regard a statement that a former labour was long as not in itself useful, but only a hint to investigate.

I differ also from Müllerheim in that I think symphysiotomy, under proper conditions, is preferable to craniotomy, and therefore ought not to be limited to cases in which the mother declines craniotomy.

I shall now try to define the conditions under which I think symphysiotomy ought to be done.

When a patient engages a doctor to attend her in childbirth, he ought to ask her to let him examine the abdomen and pelvis not later than the seventh month of pregnancy, in order that the existence of pelvic contraction, or any other abnormal condition, may be early found out. If the patient is a dwarf, or deformed, he ought to advise examination as early as possible.

At this examination, the medical attendant should ascertain; (1) the size of the pelvis; (2) the size of the child; (3) the relative size of the child and the pelvis.

(1) I need not describe here the methods of pelvimetry.

(2) The size of the child can in most cases be estimated closely enough for practical purposes by measuring the abdomen. As Müllerheim seems to think this impracticable, I shall describe how it may be done. The greatest girth of the abdomen in women at the full term of pregnancy is usually under a yard. The measurement along the convexity of the uterus, from the symphysis pubis to the top of the fundus uteri, is usually

13 inches. If the patient's measurements exceed not this, we may safely assume that the child is not of excessive size; at seven months' pregnancy they ought to be less. If the measurements exceed those given, the excess may be due: (*a*) to the child being very large; (*b*) to fat; (*c*) to excess of liquor amnii; (*d*) to tumour; (*e*) to twins.

(*b*) It is not common for women at the child-bearing age, and especially those pregnant for the first time, to be very fat, and it is not difficult to tell whether a patient is fat or thin; (*c*) excess of liquor amnii will make the child easily moveable, ballottement will be easily obtained, and there may be enough to cause fluctuation. I need not discuss the diagnosis of (*d*) abdominal tumours, nor of (*e*) twins. I have mentioned these things in elucidation of the main point that I wish to urge—one which I think is not adequately stated in text-books or remembered in practice,—viz. that it is in most cases easy to estimate the size of the child before labour comes on.

(3) Having formed a judgment as to the size of the pelvis and that of the child, the next thing is to estimate the relative size of pelvis and child. If the head presents, this can be done by putting the hands on the abdomen, just above the equator of the head, and pressing the head down into the pelvis. With a child of average size and a normal pelvis the head can easily be pressed down into the pelvis. If it cannot be pressed down into the pelvis, but the equator remains above the brim, there will be difficulty.

If the child presents not with the head, the estimation of the relative size of child and pelvis cannot be made. We must then rely upon the measurement of the girth, and the length of the uterus.

I think the relative size of child and pelvis should be ascertained thus in every pregnancy, whether the pelvis be contracted or not; and that the minimum maternal and infantile mortality in childbed will not be attained

until this is systematically done. But I leave this point, and come to consider the application of these methods to contracted pelvis.

I take first the case in which the patient has gone to full term without being examined during pregnancy. It is found that the fœtal head cannot be pressed into the pelvis, that its equator is above the brim. The conjugate can be enlarged by symphysiotomy by half an inch. If then the diameter of the head opposed to the conjugate exceeds it by less than half an inch, it can be delivered by symphysiotomy. If it exceeds it by more than this, symphysiotomy will be useless; either delivery will be impossible, or it will only be possible by excessive separation of the bones, leading to injury to the sacro-iliac joint, and to the urethra, and possibly bladder. If the disproportion between the pelvic brim and the fœtal head is only trifling, delivery can probably be effected by turning in a flat pelvis, or by forceps in a small round pelvis. The aim of the accoucheur should be to find out as early as possible the existence of disproportion too great to allow of delivery by forceps or version. There may be cases in which the accoucheur is doubtful whether or not delivery by forceps or version is possible; and in such cases it may be proper to test the question by a brief trial of these means.

If the head cannot descend easily into the brim, the membranes will probably rupture early, and the liquor amnii escape. It seems to me good practice to prevent this by dilating the cervix with Champetier's bag. This not only dilates the cervix, but prevents the escape of liquor amnii, and so protects the child from pressure.

If the patient with contracted pelvis be examined during pregnancy, there will come a time, before she approaches full term, when the head can only be pressed into the brim with difficulty. At this time the choice lies between the induction of premature labour and symphysiotomy. The former gives the patient an easy labour but a small child, whose prospect of survival is less than

that of a child born at term. Symphysiotomy gives the mother a full-sized child, with the small risk of impairment of control over the bladder. I know not that the question has ever been raised in a court of justice how far the medical attendant is justified in deciding this question without regard to the wishes of the parents; but, whatever may be the case in other countries, I think that in England the law would hold that the parents should have a voice in the matter. If the mother thinks an easy labour more important than a strong child, labour should be induced. If, in order that the child may have the best chance of survival, she is willing to submit to symphysiotomy, the abdomen should be examined at fortnightly intervals, and if before term the child's head is so large in relation to the pelvis that it is doubtful whether, if it grow larger, it can be delivered by symphysiotomy, labour should be induced.

But whether at or before term, the essential point that I wish to urge in this communication is, that if the best results are to be got from symphysiotomy, the accoucheur ought not to wait until the impossibility of delivery by the natural powers has been demonstrated by protracted ineffectual labour; but he ought by estimation of the relative size of child and pelvis to form a judgment as to the necessity of the operation before labour begins, and do the operation as soon as the os uteri is fully dilated, before the soft parts have been bruised and the uterus exhausted.

The objection may be raised that measurement being only approximate, action upon the principle I have stated will lead to symphysiotomy being performed in some cases in which, had they been left to Nature, delivery would have taken place. I grant that this may be so. But be it remembered that in such cases the necessary separation of the bones will be small, and therefore the risk of injury to the urethra almost non-existent; and that conduct of labour on the principles formulated by Müllerheim entails the ill consequences of protracted

labour on every patient. It seems to me that, balancing the ill results of unnecessary symphysiotomy upon a few patients against those of protracted ineffectual labour in a great many patients, the latter weigh down the scale.

Dr. Lewers said he had seen some of the operations described in the paper, and he regarded subcutaneous symphysiotomy as a great improvement on the method involving a large open wound. It was not applicable, however, in all cases. In his own case of symphysiotomy, for instance, there was a sort of "bite" or dovetail at the middle of the joint, and a saw had to be used before the joint-surfaces could be separated. His case had incontinence of urine for some weeks after the operation, but ultimately recovered complete control in this respect, and micturition was now quite normal.

Dr. Herbert Spencer thought the subcutaneous method recommended by the author had advantages over the open method, but it was to be remembered that many cases of severe hæmorrhage from division of large vessels had been recorded, and this had led some authorities to advocate the open method and packing the wound with iodoform gauze. Wounds in the vagina were also very apt to occur, and if these communicated with extensive effusions about the pubes, the danger of sepsis would scarcely be diminished by the subcutaneous method of dividing the joint.

In reply Dr. Herman said he was much interested in the method of ascertaining the relative size of pelvis and child described by Dr. Griffith, and hoped to test it in practice. He had included lacerations of the vagina in the injuries of the urethra of which he had spoken; for lacerations of the urethra usually affected the vagina also, and a laceration of the vagina so slight as not to reach the urethra was not important.

NOVEMBER 7th, 1900.

Alban Doran, F.R.C.S., President, in the Chair.

Present—35 Fellows and 3 Visitors.

Books were presented by the Guy's Hospital Staff and Dr. Frommel.

Horatio White Abbott, L.R.C.P., was admitted a Fellow.

The following gentleman was proposed for election :— James Sherren, L.R.C.P.Lond., M.R.C.S.Eng.

A NOTE ON A CASE OF FIBRO-MYOMA OF THE UTERUS IN A PATIENT AGED TWENTY-THREE, WITH REMARKS ON ENUCLEATION AND MYOMECTOMY.

By Arthur Giles, M.D., B.Sc., M.R.C.P., F.R.C.S.Ed.,

ASSISTANT SURGEON, CHELSEA HOSPITAL FOR WOMEN; GYNÆCOLOGIST TO THE TOTTENHAM HOSPITAL.

Two years ago Dr. Herbert Spencer contributed to this Society an important paper * on the occurrence of fibro-myoma of the uterus in women under twenty-five years of age ; he collected some forty cases previously recorded.

* 'Obstet. Soc. Trans.,' vol. xl, for 1898.

and gave an account of two cases in his own practice. The rarity of these tumours under the age of twenty-five, as demonstrated by Dr. Spencer, induces me to report the present case.

Last August I saw, with Dr. P. R. Dodwell, of Battersea, a young lady, aged twenty-three, and unmarried, who had lost a great quantity of blood. Menstruation began at the age of thirteen, and was at first moderate in quantity and of regular rhythm. For the last two years the quantity had been increasing, and in May of this year metrorrhagia supervened. During the three months prior to my seeing her she had, on Dr. Dodwell's testimony, lost an alarming quantity of blood, hæmorrhage occurring daily, and being accompanied by clots. For several weeks she had been kept in bed. She presented an appearance of the profoundest anæmia, the lips and conjunctivæ being quite colourless. On examination of the abdomen a hard mass was felt, reaching halfway between the pubes and umbilicus. Bi-manual examination showed that the tumour was situated in the uterine fundus, which presented a globular enlargement of the size of a cocoa-nut, and which was acutely anteflexed on the cervix. The latter was drawn up high posteriorly. The patient had suffered no pain, nor did she present any symptoms of bladder disturbance; the bowels, however, were usually rather constipated.

An intra-uterine myoma was diagnosed, and I decided to attempt its removal through the vagina, both as a conservative measure, and in order to avoid, if possible, performing an abdominal section on so exsanguined a patient. The parents consented, however, to the performance of any operation that might be deemed necessary.

Four days later she was anæsthetised by Dr. Dodwell, and with the assistance of Dr. C. J. Martin, I proceeded to dilate the cervical canal. When this had been fully done I could only just touch the myoma with the tip of the finger, because it was so high in the pelvis. I then stripped the bladder from the anterior surface of the

uterus, and divided the latter in the anterior median line for a distance of two inches. The myoma still remained almost inaccessible, and as I was afraid to subject the patient to such a prolonged operation as morcellement must have been under the circumstances, I abandoned the vaginal route, after introducing a strip of iodoform gauze through the cervix uteri. The abdomen was then opened, and an incision four inches long was made in the anterior wall of the uterus, opening up the uterine cavity and exposing the tumour. While Dr. Martin controlled hæmorrhage by holding the cervix between his fingers, the tumour was rapidly shelled out. There was practically no hæmorrhage, but at this stage Dr. Dodwell remarked that the pulse could no longer be felt in the wrist. A pad was stuffed into the uterine cavity and the organ firmly grasped, while the patient's head was lowered and the legs raised. She rallied, and gave us no further anxiety during the operation. The uterine incision was closed with interrupted silk sutures in the same manner as for a Cæsarean section; the abdominal wall was sutured, and the patient was put back to bed. The combined operation had lasted forty-five minutes.

The convalescence was as satisfactory as the enfeebled state of the patient warranted us to expect. For a week after operation she had a temperature ranging from 99° to 102°, which I attributed to disintegration of tissue in the capsule of the tumour. There was a good deal of serosanguineous vaginal discharge at first, but the previous dilatation of the cervix afforded excellent drainage, and no doubt contributed to the favourable issue of the case. I was at first inclined to regret the time occupied in the vaginal stage of the operation, and wished I had proceeded at once to open the abdomen; but I felt satisfied afterwards that the result might have been less favourable if drainage had not been so free. Two months after operation I saw the patient, who was then very well, and had in large measure recovered from her anæmia.

The tumour, which is shown herewith, weighs fourteen ounces; it is the size of a fist, and presents the appearance of a fibro-myoma. The diagnosis is confirmed by the microscopic appearances, as will be seen by reference to the slides exhibited. For these I am indebted to Dr. G. Norman Meachen, House Surgeon at the Tottenham Hospital.

Dr. Spencer laid it down in his paper that every case of this kind that was reported should include, firstly, the microscopic verification of the nature of the tumour; and secondly, the verification of the patient's age by reference to the birth certificate. The latter shows in this case that the patient was born on the 10th of August, 1877.

I have searched carefully through the 'Index Medicus' since the publication of Dr. Spencer's paper, but have been unable to find a record of any other case of the occurrence of a fibro-myoma under the age of twenty-five.

The nature of the operation in this case calls for a few remarks. There is no doubt that the ideal plan for dealing with an intra-uterine myoma is vaginal myomectomy. In cases where the size of the tumour or some other circumstance renders this impossible, it would appear that hysterectomy has usually been done; for I have been able to find very few cases recorded in which the uterus has been opened from the abdomen, and a tumour removed from its interior. Braithwaite * reported such a case this year, and commented on the rarity of the operation; a similar plan was adopted in two of the cases collected by Spencer, namely, by Hager, and by Lomer. In a recent paper † Herman referred to this operation as being associated with the name of Professor Martin, of Berlin, and called attention to the fact that the mortality from Martin's operation is higher than that of amputation of the body of the uterus. In the light of the after-history of my case, I think it probable that the success of the operation will depend very

* 'Brit. Med. Journ.,' 1900, vol. 1, p. 251.

† 'Practitioner,' December, 1899.

largely on having efficient drainage; for there is sure to be a considerable discharge of débris and of serum from the bed of such a tumour, and if it has not a free exit it will become pent up within the uterus, and probably interfere disastrously with the healing of the uterine incision; whilst, if the latter gives or gapes, infection of the peritoneal cavity is likely to occur. Indeed, the conditions requisite for success find a close parallelism in those that obtain in the case of Cæsarean section. Granted that these conditions are possible, it seems to me that Martin's operation is not only permissible, but preferable in dealing with a large intra-uterine myoma in a young woman when the tumour cannot be removed through the vagina. An even broader standpoint may be taken, namely, that in all cases of fibroids in young patients with the possibility of maternity before them, the uterus should be left whenever this is possible. This practice was largely adopted in the cases comprised in Spencer's list. On analysing that list two striking features come out; first, the diversity of the operations performed: and secondly, the fact that hysterectomy was resorted to only six times. Of the forty-three cases (comprising Spencer's two cases and the present one), in sixteen either no operation was performed, or none is mentioned. In the remaining twenty-seven the operations were as follows:

Oöphorectomy, two cases—Leopold, Fehling.

Vaginal enucleation, two cases—Jordan, Benicke.

Vaginal myomectomy, two cases (?)—Hofmeier, Tillaux.

Vaginal hysterectomy, two cases—Martin, Spencer.

Abdominal hysterectomy, four cases—Wildt, Wehmer, Archer, Boxall.

Abdominal myomectomy, three cases—Archer, Mansell Moullin, Spencer.

Abdominal enucleation, seven cases—Eck, Karstrom, Bandl, Bukowski, Chrobak, Brohl.

Abdominal myomectomy for intra-uterine tumours (Mar-

tin's operation), three cases—Hager, Lomer, and the present case.

In two cases, those of Howitz and Von Meyer, the nature of the operation is not specified.

On the question of operations for uterine myoma in general, it may be remarked that there is a consensus of opinion that vaginal myomectomy is the operation of election for intra-uterine polypoid myomata; and that abdominal myomectomy is equally indicated for pedunculated subserous myomata, unless they are numerous. There is, however, some divergence of opinion as to the relative scope of abdominal hysterectomy, and abdominal enucleation in the case of interstitial myomata. My own view, qualified by such reserve as is dictated by a somewhat limited experience, is that enucleation finds its legitimate field in the cases which I have been considering, namely, myomata in young subjects; whilst in older patients hysterectomy is usually preferable. For not only is enucleation a more formidable procedure, on account of the greater risk of hæmorrhage and the difficulty of controlling it, but in addition it leaves behind a mutilated organ which, in a woman over forty, is practically useless for child-bearing, and which may be harmful as well as useless, by becoming the seat of other tumours. The brilliant results obtained by such an operator as Alexander do not, I think, invalidate this view; for they seem to me more than counter-balanced by the recorded cases in which enucleation has had to be supplemented by a later hysterectomy.

The PRESIDENT remarked that abdominal myomectomy was neither easy nor safe, but it was the ideal operation in those rare cases where interstitial fibroids occurred in girls, and could not be removed through the os uteri. It allowed of the extirpation of the tumour without any mutilation, so that future maternity remained possible. Unfortunately, only those who were deeply experienced in abdominal surgery could perform myomectomy without considerable risk.

Dr. HERMAN did not think that definite rules could be laid down for the performance of myomectomy, or comparisons

drawn between it and hysterectomy. The safety of myomectomy depended upon features special to each case, which could not be found out till the abdomen had been opened. If, for instance, a fibroid was attached by a thin stalk, myomectomy was simple; if it had a large attachment, myomectomy was a very serious undertaking. The operator must judge in each case according to its special characters.

Dr. Herbert Spencer said that the operation described by Dr. Giles (opening up the uterine cavity from the abdomen for the removal of a submucous tumour) had frequently been performed; it was generally known as Martin's operation.

Dr. Arthur Giles, in reply, thanked the Fellows for their kind reception of his communication. He entirely concurred in the view expressed by Dr. Herman, that no one operation was suitable for all cases of myoma; his wish was to call attention to particular circumstances that rendered the removal of an intra-uterine tumour by abdominal myomectomy preferable to hysterectomy, namely, the occurrence of a large single myoma in the uterus of a young woman, the tumour being such as not to admit of removal through the vagina. In reply to Dr. Spencer's question, he believed that the opening of the uterine cavity from the abdomen for the removal of a submucous tumour had not been frequently practised. The enucleation of interstitial tumours, and the removal of pedunculated subserous growths, came under a different category, and these operations were by no means rare.

FATAL RUPTURE OF AN ANEURYSM OF THE SPLENIC ARTERY IMMEDIATELY AFTER LABOUR.

By J. D. S. Nodes, M.R.C.S., and Frank Hinds, M.D. (introduced by Dr. Herbert Spencer).

(See Plate XXIII.)

Mrs. W—, aged 33, was attended in her sixth confinement by a midwife. Labour was natural, and lasted six hours. The vertex presented. The placenta was expelled by the next pain after the birth of the child.

Ten minutes after the expulsion of the placenta she had what the midwife calls a "convulsion," in which she threw her arms above her head, became restless, and struggled to get out of bed. The face, at first dark, became paler until the patient died, about a quarter of an hour after the commencement of the "convulsion." She did not complain of pain after labour, and had never complained of any symptoms of abdominal trouble. There was no history of syphilis or of alcoholism.

Post-mortem examination was made by order of the coroner.

The body was well nourished. The peritoneal cavity was full of blood, mostly liquid, but with much clotting in the region of the spleen. The uterus was contracted. The viscera were healthy. There were no signs of atheroma in the aorta.

The spleen and pancreas were removed together. The splenic artery had broken up into several branches, and at the point of division was a sac as large as a grape, into which a probe passed along the artery entered. The wall of the sac was torn away from its point of union with the surface of the spleen, and it was from this tear that the hæmorrhage had taken place; no doubt a considerable extent of the tear was made during the removal of the organ from the body.

For the following description of the specimen, and for the excellent drawing, we are indebted to Mr. T. W. P. Lawrence, Curator of the Museum of Anatomy in University College, London, where the specimen is preserved.

Note by Mr. T. W. P. Lawrence.—The aneurysm is situated at the hilum of the spleen, where it forms an oval tumour lying in contact with the organ, and measuring 3·5 cm. by 3 cm. It arises from the splenic artery at the point where the latter gives off its first branch, and partly also from the branch itself. The aperture of communication with the vessel measures about

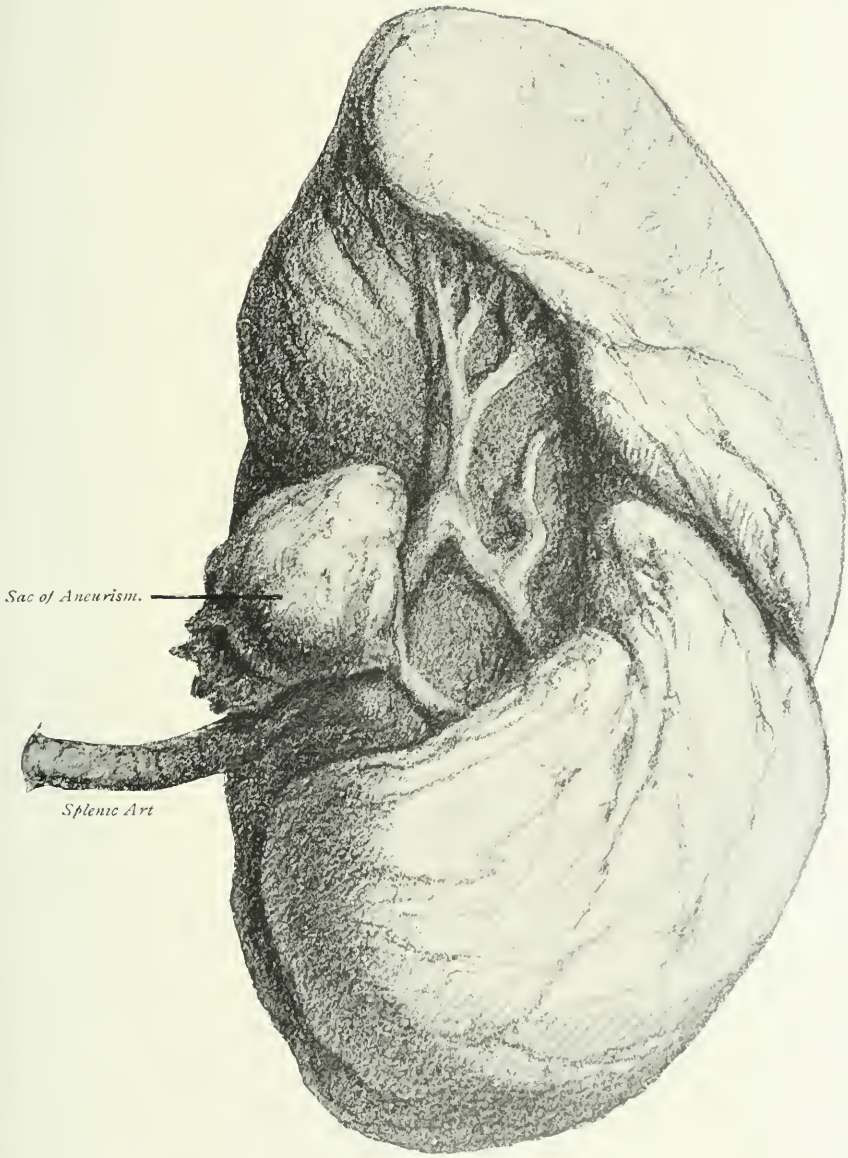

T, W. P. Lawrence, del.

Illustrating Mr. NODES's and Dr. HINDS's specimen of Fatal Rupture of an Aneurism of the Splenic Artery.

Bale & Danielsson, Ltd.

1 cm. in length. At one extremity of the aneurysm the walls have ruptured, and the adjacent areolar tissue of the hilum was found infiltrated with blood. The inner surface of the aneurysm is smooth, and free from adhering coagula. The splenic artery is in places more rigid than normal, probably from calcareous deposits in its walls.

Aneurysm of the splenic artery is rare.

In the Index Catalogue of the Library of the Surgeon General's Office of the United States Army, the references of which extend from 1880 to 1896, there are nine cases of aneurysm of the splenic artery recorded, in addition to ten cases in which the aorta was involved. We append notes of these cases.

From an examination of them, and of the one we report, we find that the ages of the subjects of this lesion varied from thirty to sixty years, that four of them occurred in males, five in females, and in one the sex was not stated.

In four cases the aneurysm was the direct cause of death; in these cases the patients were none of them over forty years of age. In two of them (Cases 1 and 6) there had been attacks of abdominal pain on previous occasions, and attacks of hæmatemesis and melæna. Death was due in Case 1 to rupture of the aneurysm into the stomach, and in Case 6 to rupture into the colon.

In the other two fatal cases (7 and 10) the aneurysm had ruptured into the peritoneum, and caused sudden death; in neither case had there been any premonitory symptoms, nor was any disease of the organs noted, beyond slight atheroma of the aorta.

In the remaining five cases the cause of death is stated to have been:—

In Case 5, "erysipelas," where the spleen was "enormous" and the artery elongated and dilated, with diverticula, and the splenic vein was in the same condition.

In Case 2, "debility," the aneurysm was the size of a walnut, and calcified.

In Case 4, "cancer of the œsophagus," there were small aneurysms on the splenic artery and its divisions.

In Case 8 the cause of death is not stated; there had been attacks of abdominal pain for years, and attacks of hæmatemesis and melæna; a dilated splenic artery communicated with a dilatation of the splenic vein.

In Case 9 an unruptured aneurysm of a branch of the splenic artery projected into a gastric ulcer.

From a consideration of these cases it appears that aneurysm of the splenic artery may occur without symptoms (Cases 2, 4, 7, and 10), and may undergo spontaneous cure (Case 2), or may suddenly rupture (Cases 7 and 10). That where it gives rise to symptoms, these are abdominal pain, melæna, and hæmatemesis (Cases 1, 6, and 8), bruit (Cases 6 and 8), and palpable tumour (Case 6).

Enlarged spleen is only mentioned in one case, and then was probably due to either the malaria or the erysipelas, or both.

The ætiology of the condition is quite obscure in most of the cases, though in some it appears to have been caused by softening of the vessel walls, consequent on inflammatory conditions in close proximity to them (Cases 4 and 9, and ? 5 and 1).

We have thought it well to put this case on record, because of the rarity of the condition, and because of circumstances under which rupture took place—*i. e.* immediately following an easy labour at which a midwife was taking charge of the patient.

References.

Case 1 ('Boston Med. and Surg. Journ.,' February, 1883.)—Female, aged 40, had had periodic attacks of pain in abdomen for years, and epistaxis. After an attack lasting three weeks went out, had severe hæmatemesis and pain in left side. Fatal hæmatemesis four days later.

Post-mortem.—Pleural effusion, atheromatous aorta; stomach, liver, and omentum adherent to abdominal wall; stomach contained blood, and had a perforation leading to a sac made up of spleen, diaphragm, liver, stomach, and pancreas, into which a dilated splenic artery opened.

Case 2 (Pathological Society, Philadelphia, February, 1888).—Female, aged 60. Admitted for debility; died four days later. Slight aortic atheroma; two inches from the aorta, on the splenic artery, was an aneurysm the size of a walnut, which had calcified.

Case 3 ('Virch. Archiv,' Bd. iv, Sec. 27, 1886, by Weigert).—Specimen of a woman aged 49. There were two aneurysms in the splenic artery; the larger of these (11 cm. in circumference) had burst into the splenic vein. The splenic vein was greatly dilated, the mesenteric veins to a less extent. Chronic endophlebitis of the mesenteric veins; cellular tissue around them thickened; ascites.

Case 4 ('Liverpool Med.-Chir. Journ.,' November 1884, by Davidson).—Specimen from patient who had died of cancer of œsophagus. On the first division of the splenic artery was an aneurysm the size of a bean, and on the next three divisions were smaller aneurysms. There was slight aortic atheroma. The spleen contained infarcts, and Davidson suggests that aneurysms were due to weakening of walls caused by emboli.

Case 5 (Soc. Anatomique, Av. 1892, by Beaussenat).—Male, aged 54, copper engraver; history of malaria, none of syphilis. Died from attack of erysipelas with abscesses, sloughing, and diarrhœa.

Post-mortem.—Spleen "enormous," splenic artery elongated, and from tail of pancreas to hilum is the seat of an aneurysmal dilatation of irregular shape, and at each end is

a diverticulum as large as a hen's egg, with thin walls. The splenic vein is also dilated, and has diverticula.

Case 6 ('Montreal General Hospital Reports,' 1880, by Drake).—Male, aged 30, suffered from epigastric pain and vomiting. Tumour felt deep in left hypochondrium; no pulsation; bruit heard once; occasional hæmatemesis and bleeding from bowel, which was the cause of death.

Post-mortem.—Tumour size of cocoa-nut, found to be aneurysm of splenic artery with many adhesions and laminated walls. The sac communicated with the colon at the splenic flexure.

Case 7 ('Trans. Path. Soc.,' April, 1885, by Charlewood Turner).—Male, aged 37; sudden death while at work.

Post-mortem.—Peritoneum full of blood, organs healthy. On splenic artery, two inches from the aorta, was an aneurysm as large as an orange; lower part of aorta slightly atheromatous.

Case 8 ('Trans. Path. Soc.,' May, 1889, by Goodhart).—Female, aged 49, ten children, of whom youngest was twelve years old. History of attacks of abdominal pain, hematemesis and melæna; bruit heard over splenic area. There was ascites.

Post-mortem.—The splenic vein was dilated to size of a hen's egg, and communicated with a dilated splenic artery.

Case 9 (Path. Soc., 'Lancet,' March 21st, 1885, by S. West).—Male, aged 56, drinker, had abdominal pain and hæmatemesis.

Post-mortem.—Gastric ulcer, into which projected an aneurysm of a branch of the splenic artery. This aneurysm had not ruptured.

ON A CASE OF TUBAL ABORTION IN WHICH THE "MOLE" WAS IN PROCESS OF EXTRUSION AT THE TIME OF OPERATION.

By J. Bland-Sutton.

Tubal abortion has become a subject of importance. When attention was first drawn to the accident, many observers regarded its occurrence as questionable, or of great rarity. Now the condition is well recognised, and in the practice of some observers it is regarded as the most frequent mode by which tubal pregnancy terminates. Further, some of us have on several occasions determined that patients who have come under our care with clear signs of a gravid tube, were the subjects of "tubal abortion," and the diagnosis has been confirmed at the operation.

For a time a few competent critics were somewhat doubtful in regard to what I have called "complete tubal abortion," an event in which the mole is discharged through the cœlomic ostium of the tube into the pelvis. I have recorded a case of undoubted tubal abortion in which the mole was found free in the recto-vaginal pouch ('British Medical Journal,' 1896, vol. xi, p. 1308). On two occasions, in the course of operations for internal bleeding due to tubal pregnancy, I have seen the mole slip out of the cœlomic ostium as the tube was drawn into the wound; but on Friday, September 21st, 1900, in dealing with a case of this kind, I succeeded in removing a gravid tube with the mole in process of extrusion, and I have managed to preserve the parts with the mole halfway through the cœlomic ostium.

The patient, a single woman, twenty-three years of age, was sent to the Middlesex Hospital, under my care, by Dr. Claude Taylor, as a case of internal hæmorrhage due to tubal pregnancy; and he also supplied me with an

account of her clinical history. The chief facts are these: She had a menstrual flow in February, and shortly after it ceased coitus took place; six weeks later she had an issue of blood lasting two weeks, and from this period until August she had recurrent metrorrhagia. Occasionally the flow of blood would persist fourteen days, but in August Dr. Clayton detected a hypogastric swelling, and perceived its gravity.

When she came into the hospital the woman was very ill; pulse 120 to the minute, and the temperature stood at 101°. The skin was quite white, and the mucous membrane of the lips pallid. An indefinite swelling could be made out in the hypogastric region, and on vaginal examination the uterus could not be separated from the mass. Some fœtid decomposed blood issued from the uterus. The mammæ were normal.

Next day ether was administered, and I found the pelvis occupied by a large indefinite mass surrounding the uterus; this organ occupied its natural position, and its cavity scarcely exceeded the normal length. On opening the abdomen a great quantity of clotted blood

Fig. 1.

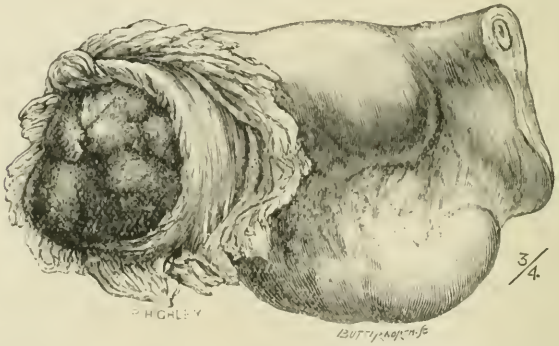

A gravid Fallopian tube and ovary. A mole is in process of extrusion from the cœlomic ostium. (The specimen is in the museum of the Royal College of Surgeons.)

was removed from the pelvis, and a much larger quantity of fluid venous blood inundated the belly and extended

as high as the liver. The left Fallopian tube, greatly thickened and enlarged, was removed with the ovary and an ovoid mass, which could be seen protruding from the cœlomic ostium of the tube (fig. 1). The right Fallopian tube and ovary were thickened, but otherwise normal. After carefully removing the liquid blood, and picking out as much of the clot as possible, the wound was closed, and the patient returned to bed. Three ounces of saline solution were injected into the rectum hourly until some thirty ounces had been administered. The pulse gradually slowed in the course of a week to the normal rate, the temperature declined in the same gradual way, and the patient made an excellent recovery.

The case is interesting in several particulars apart from the fact that the mole was caught, so to speak, in the act of quitting the tube. I believe that the blood had been slowly trickling (or dripping at times) from the tube for many weeks into the pelvis, and that some of the blood from the tube found its way through the uterine orifice into the uterus and escaped by the vagina, and especially after the mole had plugged the cœlomic ostium.

The temperature stood for many days at 102°—this I attribute to the absorption of the dead blood in the belly, —and after the operation the slow gradual lysis coincided with the absorption of the fragments of clot which had defied removal. On a previous occasion I ventured to draw the attention of the Society to the fact that the presence of a large quantity of effused and clotted (therefore dead) blood is often associated with an elevated temperature. (See 'Trans. Obstet. Soc.,' vol. xl, p. 9.)

A microscopic examination of the mole is instructive. Chorion villi are abundant, but they exhibit the features of villi found in fragments of placenta which have been retained in the uterus many weeks after labour or miscarriage. This fact may be used as evidence in favour of the view that there had been a slow trickling of blood

from the tube into the belly during many weeks, probably twelve, judging from the clinical facts.

Lastly, the case is another illustration of a truth which has been abundantly illustrated during the last three years. The left Fallopian tube may become gravid in women as the result of early coitus, as well as in those who remain sterile for many years, though living in the most favourable environment.

Dr. Peter Horrocks asked what was the condition of the uterus. It was obvious from the history and from the specimen that the fœtus had perished months before the operation, thus giving ample time for involution to take place, and unless there were some cause for subinvolution the uterus ought to have been found practically normal in its dimensions.

Dr. Herman said that our knowledge of tubal abortion was quite recent, and we were indebted for most of it to Mr. Bland-Sutton. Our knowledge of many other events of ectopic pregnancy was much older; tubal rupture, secondary abdominal pregnancy, suppuration of ectopic pregnancy, lithopædion, etc., were all well known a hundred years ago. The reason was, that these latter conditions were found out by the post-mortem examination of women who had died; but tubal abortion was not found out until the abdominal cavity came to be frequently opened in living women; then it was found to be common. There was no reason to suppose that women a hundred years ago were different from their descendants of to-day; tubal abortion was doubtless as common then as it is now; but as the condition was not discovered by post-mortem examination, he thought it was clear that the patients must have recovered. He approved Mr. Bland-Sutton's practice in the case related. He agreed with him that when there was reasonable ground for thinking that tubal abortion had taken place, the proper course was to remove the diseased tube. But the ground for interference was not to save life, which in this condition was in small danger, but to prevent a long illness. Mr. Bland-Sutton's patient was ill for months after the date at which the tubal abortion was supposed to have occurred. Had Mr. Bland-Sutton had the opportunity of removing the diseased part then, the patient would have been saved those months of illness.

Dr. W. S. A. Griffith felt some doubt if Mr. Bland-Sutton's explanation of the pyrexia following the operation was the correct one. It might more probably be the result of sapræmia from the uterus, the discharge from which was very offensive. Neither could he accept the view that the uterine hæmorrhage was the result of blood retained in the tube

escaping through the uterus; the normal anatomy of the tube, and all his experience of the changes which take place in it in hydrosalpinx and other chronic distensions of the tubes, made it appear to Dr. Griffith highly improbable. The specimen was the finest example of partial extrusion of an ovum from the tube he had ever seen.

Dr. Amand Routh said that although he was aware that pyrexia often accompanied hæmatocele, he asked Mr. Bland-Sutton whether the temperature which persisted for ten days after the operation was not due to sapræmia from decomposition of the decidua, which had led to the offensive discharge. He had seen one such case, which led at first to a difficulty in diagnosis, but which was cleared up by the formation of a hæmatocele which became encysted; and as it increased in size it was opened, as was his invariable habit in encysted cases, through the vagina. Diffuse hæmatocele, of course, needed immediate abdominal section.

The President asked if Mr. Bland-Sutton believed that the live ovum was frequently extruded from the tube and lived to develop elsewhere.

Mr. Bland-Sutton, in reply, said he agreed with Dr. Herman that in many cases of tubal abortion the amount of blood which escaped into the pelvis was not sufficient to cause a serious illness, and the temporary inconvenience it caused soon subsided; the graver forms of collapse, due to a large effusion of blood, which needed and in some instances demanded surgical interference, were exceptional. The very grave cases where internal bleeding is so profuse as to destroy life in a few hours do not come to hospitals, but become the subjects of coroners' inquests. It occasionally happens in performing operations on the pelvis of patients for chronic tubal disease, to find a hard blood-clot sequestered in a recess of the pelvis, and partially hidden by adhesions. Some of these hard clots in all probability represent the remains of a tubal abortion which has undergone a natural cure. He was firmly of opinion that the absorption of a large quantity of deliquescent blood-clot effused into the peritoneal cavity caused an elevation of temperature. Mr. Bland-Sutton distinctly stated that an intra-peritoneal effusion of blood did not cause peritonitis; the clot, however, might become septic by contamination from bowel, bladder, or Fallopian tube.

AN ANOMALOUS CASE OF ECTOPIC PREGNANCY, PROBABLY OVARIAN.

By E. Octavius Croft, M.D., Leeds.

(Received August 8th, 1900.)

(See Plate XXIV.)

(*Abstract.*)

The history and physical signs pointed to a diagnosis of some form of extra-uterine gestation, and the sac and its contents found entire were removed by abdominal section. There was free bleeding from rupture during operation, and although it was soon controlled by ligature of the broad ligament the patient did not rally, and died a few days afterwards.

The autopsy revealed an absence of peritonitis, and the pelvic organs were removed for further examination.

The sac, before rupture, contained the complete ovum—fœtus of about four months' growth, with placenta, membranes, and amniotic fluid. There was no blood or clot in the sac. Its relations were those of an ovarian tumour with short pedicle. The surface of the cyst contained follicles (? Graafian), and no separate structure corresponding to an ovary was evident on the same (right) side. The microscopic evidence of ovarian tissue in the wall was uncertain.

The Fallopian tube was present and uninjured, the fimbriated end free and patent, and the layers of the mesosalpinx undisturbed.

The uterus was intact, and the appendages on the opposite (left) side were normal.

The possibility of the pregnancy being ovarian is suggested.

The following case is, I think, worthy of bringing before the Society, as the specimens exhibited present unusual features which lead one to suppose that the gestation has probably been primarily ovarian. The patient unfortunately did not recover, but as an autopsy was performed, and the pelvic organs examined and removed, further details could be obtained not otherwise possible.

I am indebted to Mr. Cecil Pierson for the original notes from which I make the report.

E. R—, aged 25, married, two children, no abortions. Her first labour, severe and instrumental, was followed by an attack of puerperal fever. Menstruation subsequently returned regularly, but there were symptoms of some chronic uterine trouble until the second labour, about sixteen months before admission to hospital. The labour was easy, but lactation was prevented by the development of mastitis. The lochia continued red for six weeks, then ceased for three months, afterwards the catamenia became regular but scanty, with an intermenstrual leucorrhœa, until eleven weeks before admission, when the last period is stated to have occurred as usual. Two weeks after this sudden severe colicky pains came on, accompanied with vomiting. For the next six weeks, there were symptoms attributed to pregnancy (vomiting, pain in breasts, etc.). Then followed another severe attack, the pains being like labour pains, and situated chiefly on the right side of the lower abdomen, radiating to the back, hips, and thighs, and being accompanied with a slight blood-stained vaginal discharge.

The attacks of pain and bleeding were repeated at intervals and, in addition, defæcation and micturition became difficult and painful. The passage of a decidual membrane was not observed.

She was admitted into the Hospital for Women, at Leeds, on February 4th, 1898.

General condition.—Anæmic, but otherwise healthy;

urine normal. Breasts: full, tense, nipples prominent; large veins visible, secondary areola marked, no fluid expressed.

Abdomen.—No general distension. Over inner part of right iliac and hypogastric regions there is dulness on percussion, and on deep pressure, which is painful, a tumour is felt, softish, irregularly oval, and smooth. The swelling does not vary in outline on repeated observations. No souffle can be detected, nor any pulsation.

Vaginal examination.—The uterus is displaced to the left, the cervix approaching close to the pelvic wall on that side. The cervix is soft, and the os patulous. There is resistance, tenderness, and pain on pressure to the right of the uterus.

Bimanually.—The uterus a little enlarged and its mobility impaired. To the right of uterus and almost in contact with it a smooth rounded mass is felt of about the size of a very large orange. It is situated high up in the pelvis, its under surface only being felt with difficulty. The uterus is rather more mobile than the tumour, and its fundus reaches a little higher than the summit of the tumour. At the lower and outer part of the tumour a large pulsating vessel can be felt. There is some pain and tenderness in the situation of the left appendages.

Diagnosis.—Some variety of ectopic gestation; operation advised.

February 10th, 1898.—The patient was put under ether, and I opened the abdomen in the middle line. There was no fluid or blood in the peritoneum. To right of uterus, a roundish, smooth, fluctuating, dark reddish-brown coloured tumour was found, free above, somewhat fixed below, where a few soft adhesions were found in Douglas's pouch and separated. The sac was tapped in front to lessen its bulk, and two or three ounces of pale fluid (liquor amnii) escaped, followed by the cord and limbs of the fœtus, which was wholly extruded. On raising the sac from the pelvis it ruptured at its lower

Illustrating Dr. E. O. CROFT's specimen of Ectopic Pregnancy, probably ovarian.

Bale & Danielsson, Ltd., Lith.

DESCRIPTION OF PLATE XXIV,

Illustrating Dr. E. O. Croft's specimen of Ectopic Pregnancy, probably Ovarian.

a. Upper opening; it was originally the apex of the cyst when in the abdomen.

b. Lower opening.

c. Gestation sac, probably ovarian.

part, and there was profuse bleeding, which was checked by placing clamps on the pedicle. The latter was then secured with silk ligatures and the cyst removed. Owing to some further oozing, I packed and drained the bottom of the pelvis with a strip of iodoform gauze. The patient was much collapsed after the operation, and the pulse remained very rapid until she died, on February 16th.

Post-mortem examination.—There was no peritonitis nor evidence of further bleeding. The pelvic organs were removed entire.

Description of specimens.—The gestation sac is somewhat oval, and measures (without fœtus and liquor amnii) about 6 inches in diameter. It contains the placenta and fœtal membranes, but no blood or clot. The umbilical cord and a portion of the placenta protrude from the upper opening. There is also a ragged opening at its lower part, this being the site of the bleeding from rupture during the operation. The surface is generally smooth, but studded here and there with small cystic elevations, which on puncture are found to contain clear fluid. The larger ones are about the size of a dried pea.

The Fallopian tube is present, and measures from its cut proximal end to the fimbriated extremity about 5 inches. The tube itself appears perfectly normal, there being no evidence of distension, thickening, or rupture. The fimbriated extremity is normal, the ostium patent, and there are no adhesions about any part of the tube. Between the Fallopian tube and the sac the mesosalpinx appears normal, its layers are not separated, and are transparent, showing the usual structures (parovarium, vessels, etc.) when held up to the light. The depth of the mesosalpinx measures $\frac{3}{4}$ to 1 inch at various parts. In all respects the cyst appears to bear to the Fallopian tube the relations of an ovarian tumour. There is no evidence of any separate body corresponding to the ovary.

The fœtus is well developed, and measures about 5 inches in length.

Remaining pelvic organs, removed post mortem.—This part of the specimen consists of the uterus with the remains of its appendages, the bladder, rectum, etc. The peritoneum covering the anterior surface of the uterus and utero-vesical pouch is normal and intact. The uterus is enlarged, its external length being 4 inches, and breadth 2½ inches. The cavity measures 3 inches. It contains some pulpy blood-stained material, but no distinct decidua. The intra-mural portions of the tubes are normal. The uterine wall is everywhere intact. The posterior surface of the uterus is normal, the peritoneum of Douglas's pouch having its usual relations.

On the left side.—The ovary (1½ × 1 inch) is normal; it contains no corpus luteum. The Fallopian tube and its fimbriated extremity are normal. The ostium is patent, and there are no adhesions.

On the right side.—The remains of the ligatured pedicle are seen to consist of broad ligament and tube. The ligatures have been removed in order to restore the original position of the parts as far as possible. The stump of the Fallopian tube is about ¾ inch long, and appears normal. The layers of broad ligament below the ligatures are not separated. There is a distinct double layer of mesometrium between the side of the uterus and the ligatures. There is no evidence of any structure resembling an ovary on this side.

The theory that my specimen is possibly one of primary ovarian pregnancy is suggested by the apparent exclusion of the more usually accepted varieties originating in the tube, and also by special features of the specimen itself more or less directly pointing to an ovarian origin.

By Exclusion.

Primary uterine, with rupture into the peritoneal cavity or into broad ligament. Excluded by the intact condition of the uterine wall, and unseparated layers of mesometrium.

Tubo-uterine.—The interstitial portion of both tubes intact.

Tubo-abdominal.—No evidence of rupture of tube into peritoneum, or of distension of open end of tube. Placenta apparently not attached to any part that could have been the lining of the tube.

Tubo-ligamentary.—Seems impossible, owing to the undisturbed condition of the mesosalpinx between the tube and the sac. The tube does not in any way form the roof of the sac.

Gestation in an ovarian sac is practically a variety of the tubo-abdominal form already referred to.

Pregnancy in the ovarian fimbria, or *pregnancy in an accessory tube-end* adherent to the ovary, do not seem to explain the case.

Special Features.

The general appearance and relations of the cyst, and the presence of a number of small follicles on the surface, with a strong naked-eye resemblance to Graafian follicles. The intact condition of the tube, and the normal condition of the mesosalpinx. The absence of any adhesion, or connection in any way of the tube or its ostium with the gestation sac. The fact that the fœtus, together with the placenta and membranes, were contained in a complete sac, having the relations of an ovarian tumour, and being unconnected with the tube or uterus.

I have had microscopic sections made from various parts of the sac-wall by several independent observers, but the resulting opinions were not unanimous as to the presence of ovarian structure. Some of these sections are shown.

The criteria of an ovarian pregnancy.—Lawson Tait ('Ectopic Pregnancy,' 1888) :—"It is impossible to admit any case as one of ovarian pregnancy in which no *post-mortem* has been made . . . . . the uterus and both tubes would have to be recorded as intact, and we should

have one ovary present and the other not accounted for, save by its existence on the cyst of the ovum, and in the cyst-wall of such a case microscopic evidence of the presence of ovarian tissue would be required." My case fulfils most of these conditions.

Is it essential that ovarian tissue should be demonstrated in all parts of the cyst-wall?

Supposing the possibility of impregnation of the ovum in the Graafian follicle. The spermatozoa must have gained access through the thin projecting outer wall of the follicle, either penetrating it (?) or entering through the aperture caused by rupture. Would a section of a mature follicle at this spot, even under normal conditions, show tissue that could be recognised *per se* as ovarian? Less is it likely after the opening has become closed, and the tissue further altered by its development into the wall of the sac. Recognisable ovarian tissue would exist over a cup-shaped portion of the cyst, and would thus be very difficult to distinguish from the flattened out ovary spread on the surface of a sac formed of other structures.

Spiegelberg said "that the tube is intact, and has no organic connection with the gestation sac; that the tumour is connected with the uterus by the utero-ovarian ligament, and that the walls of the sac contain Graafian follicles."

The case of Konwer's—described in a paper by van Tussenbroek ('Annales de Gynécologie et d'Obstétrique') and quoted in 'British Medical Journal' (April 14th, 1900)—showed a distinct gestation sac, containing embryo in direct relation with a Graafian follicle, the tube being normal. No decidua was present. This case bore evidence of the possibility of ovarian pregnancy, and also that the so-called "decidual reaction" is not a *sine quâ non*.

It is with much hesitation that I suggest my case to be one of primary ovarian pregnancy; but recognising the importance of any doubtful case being carefully observed

and examined, I venture to bring what, at any rate, is a specimen of some interest before this meeting, and hope to have the privilege of obtaining the opinion of Fellows of the Society as to its origin.

The specimen was referred to a Committee composed of Dr. Eden, Dr. H. Roberts, Mr. Bland-Sutton, and Mr. Targett.

A CASE OF REPEATED ECTOPIC GESTATION IN THE SAME PATIENT; LAPAROTOMY ON EACH OCCASION.

By Arthur H. N. Lewers, M.D.Lond.,

OBSTETRIC PHYSICIAN TO THE LONDON HOSPITAL.

(Received September 21st, 1900.)

(See Plate XXV.)

(*Abstract.*)

The author relates the case of a patient, twenty-nine years of age, who has been the subject of ectopic gestation on two occasions. There has been no uterine pregnancy. The first ectopic pregnancy occurred early in 1894. Laparotomy was performed in March, 1894, and the left Fallopian tube was removed, containing a tubal mole. This specimen was reported on by a committee of the Obstetrical Society ('Obstet. Soc. Trans.,' vol. xxxviii, p. 87). The ostium of the tube was open, but not dilated. The case on that occasion was one of *threatened tubal abortion.*

In May, 1900, *i. e.* after an interval of a little more than six years, the patient was again the subject of ectopic gestation, and laparotomy was again performed. The parts removed consisted of the right Fallopian tube and ovary, and a tubal mole. The ostium of the tube was widely dilated, and the mole had either been expelled into the peritoneal cavity, or was lying loose in the dilated ostium, at the time of the operation; so that on the second occasion the case was one of *complete tubal abortion.* The patient recovered well on both occasions.

Reference is made to Dr. J. Haig Ferguson's paper on "Repeated Ectopic Gestation in the same Patient" ('Ed. Med. Journ.,' 1899, p. 145), from which it appears that, while there is a considerable number of cases reported of repeated tubal pregnancy in the same woman, laparotomy performed twice on the same woman is only mentioned in fourteen cases. According to the same authority the interval between the ectopic pregnancies in the same patient has varied from six weeks to five years. In the author's case the interval, which was more than six years, seems therefore to have been exceptionally long.

Reference is also made to Dr. Edgar's paper on the same subject, also published in the 'Ed. Med. Journ.' for 1899.

S. M—, a married woman aged 29, was admitted under my care into the London Hospital on May 2nd, 1900.

Previous history.—She has been married nine years, but has had no children or miscarriages. She was operated on for ectopic gestation in the London Hospital by me in March, 1894. The specimen removed at that operation was the left ovary and the left Fallopian tube, containing a tubal mole; it was shown at a meeting of the Obstetrical Society, and was reported on by a committee consisting of Mr. Alban Doran, Mr. Bland-Sutton, and myself. The report of that committee is to be found in vol. xxxviii of the Society's 'Transactions,' p. 87.

The patient recovered well from that operation, and has remained well till the present illness began. When she was in the hospital in 1894, she incorrectly gave her age as twenty-eight, but she now says that she is twenty-nine, so that, if she is right on the point now, she must have been only twenty-three when she was in hospital on the former occasion.

Present illness.—The menstrual periods have occurred regularly every four weeks since 1894. She has always lost a good deal at these times, but has not passed clots or shreds, and the periods have not been attended by much pain.

The last proper menstrual period previous to admission to the hospital was at the end of February, 1900. The loss on this occasion was much less than usual. She then "saw nothing" till April 21st, when there was a slight "show," with great pain right across the lower abdomen. This came on suddenly, and was accompanied by vomiting. The pain lasted a whole night, and she had to walk about on account of it. The discharge was of a much darker colour than usual. The pain has continued more or less, and is described as being a continuous aching in both groins, extending to the rectum and the vagina. There have been two especially severe attacks of pain since the first, one attack seven days before admission, and another on the day she was admitted. Since the illness began there has been pain on micturition and on defæcation, and the bowels have been constipated.

Present state—May 3rd.—*On examining the lower abdomen*, a distinct swelling was felt in the right iliac region, not reaching higher than a line joining the umbilicus and the right anterior superior iliac spine. The lower abdomen was extremely tender. A little clear fluid was squeezed out of the right nipple, but none could be squeezed out of the left.

On vaginal examination, a little brown discharge was seen about the vaginal orifice; there was also some blueness of the vaginal mucous membrane. The uterus was fixed. A fixed swelling was felt occupying the left posterior quarter of the pelvis, and extending across Douglas's pouch to the right posterior quarter. The sound passed 3½ inches.

The swelling found on examining the abdomen was on the right side, while on vaginal examination the chief part of the swelling was to the left and behind the uterus, though some swelling could also be felt in the right posterior quarter.

The whole of the examination was conducted under difficulties, as even gentle examination caused great pain.

I considered the case to be one of ectopic gestation, and I determined to watch the patient for a time and be guided by circumstances.

10th.—The swelling felt in the right lower abdomen seemed to be rather larger. On vaginal examination the physical signs were much the same as on May 3rd. There was still some blood-stained discharge.

She had been in more or less pain since her admission, sometimes felt more in the left lower abdomen, sometimes more on the opposite side. Movement in bed caused severe pain.

12th.—This morning the patient had an attack of most intense pain in the right iliac region, not relieved by a hypodermic injection of morphine. The swelling on the right side seemed to be decidedly larger, so I concluded that operation should not be further delayed. Dr. Herman also kindly saw the case, and agreed with me on this point.

Operation.—Accordingly at 5 p.m. the abdomen was opened along the line of the old scar. The omentum was adherent immediately in the line of the scar, and a coil of intestine was adherent to the abdominal wall just to the left of the scar. As a Keith's tube had been used at the previous operation, and the abdominal parietes sutured by a single set of stitches passing through the whole thickness of the abdominal wall, it was interesting to see that the recti were in perfect apposition, so much so that some fibres had to be divided, as no clear interval could be found between the muscles.

On opening the abdomen a good deal of dark blood-clot was found, chiefly on the right side and below. Most of the clot was removed by the hand, and among the clots was a tubal mole. The right uterine appendages were then removed in the usual way. The blood-clot was sponged out as completely as possible, and then the pelvis and immediate neighbourhood were washed out with sterilised saline solution. A Keith's tube was

inserted, and the rest of the wound was closed. The patient made an uninterrupted recovery.

Description of the specimen.—The parts removed consist of the right Fallopian tube and ovary, and the tubal mole, which was removed separately at the operation. The Fallopian tube is much enlarged, so as to measure $1\frac{1}{8}$ inches from above down. The fimbriated end of the tube is open and widely dilated, so as to measure $1\frac{1}{4}$ inches in diameter. The ovarian fimbria is well seen. There has been no rupture of the tube. The ovary on section shows a very typical corpus luteum measuring $\frac{7}{8}$ and $\frac{5}{8}$ of an inch; there is a central white area about a $\frac{1}{4}$ of an inch in diameter, outside which comes the broad band of yellow tissue.

The mole has a shape closely corresponding to that of the Fallopian tube in which it had been contained. The length is $2\frac{1}{2}$ inches, and at its broadest (outer part) the breadth is $1\frac{1}{4}$ inches. On section it shows no cavity.

Sections of the mole examined under the microscope show numerous chorionic villi.

It is not absolutely certain whether the mole had been completely expelled from the tube before the operation, or whether it was pressed out of the tube by the manipulation during the operation. As, however, the fimbriated end of the tube is so widely open (to the size needed to allow the widest part of the mole to pass), I think it had either been expelled before the operation, or was in process of being expelled at that time.

Remarks.—There is a very interesting paper on "Repeated Ectopic Pregnancy in the same Patient," by Dr. J. Haig Ferguson, published in the 'Edinburgh Medical Journal,' vol. v, 1899, p. 145. According to him, while there is a considerable number of cases reported of repeated tubal pregnancy in the same woman, laparotomy performed twice on the same case is only mentioned by fourteen operators, whose names he enumerates, so that cases of the kind still appear to be sufficiently rare to be worth recording. Dr. Ferguson

DESCRIPTION OF PLATE XXV,

Illustrating Dr. Lewers's specimen of Repeated Ectopic Pregnancy.

The Plate shows the parts removed at the second laparotomy.

Fig. 1.—*a*. Tube.
b. Ovary.

Fig. 2.—A section through the ovary.

Fig. 3.—The mole.

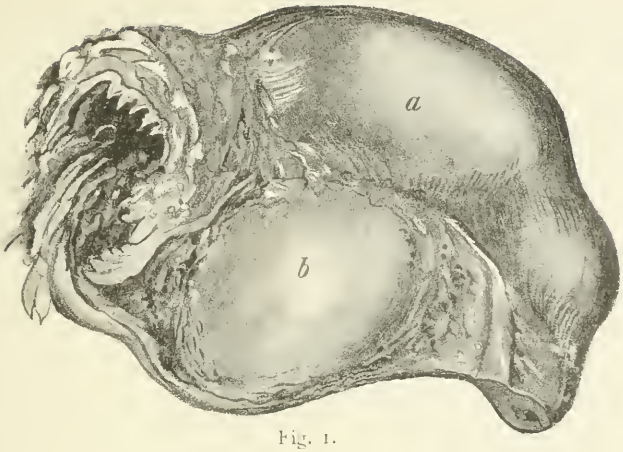

Fig. 1.

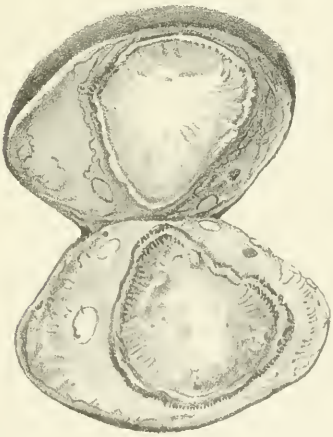

Fig. 2.

Fig. 3.

Illustrating Dr. LEWERS'S case of repeated Ectopic Gestation.

Bale & Danielsson, Ltd., Lith.

gives reasons for thinking that in every hundred cases of extra-uterine pregnancy five cases of both tubes being affected, either at the same time, or at different times, may be expected. According to Zangemeister, quoted by Dr. Ferguson, the interval between two repeated tubal pregnancies varies from six weeks to five years. In my own case the interval was more than six years. At the first operation the tube was removed, still containing the mole ; the fimbriated end of the tube was open, but not dilated, and intra-peritoneal hæmorrhage had occurred, so that on the first occasion the case was an example of *threatened tubal abortion*. On the second occasion the mole was removed separately, and the fimbriated end of the tube was widely dilated, so that it had either been expelled from the tube before the operation, or was in process of being expelled. The case on the second occasion was therefore either *a complete tubal abortion*, or one just in process of becoming complete at the time of the operation.

It is curious that on neither occasion did the ectopic pregnancy proceed sufficiently normally, if the term may be allowed, to lead to the production of a fœtus large enough to be detected, but that on both occasions the ovum had degenerated into a mole. There was a much larger quantity of blood and blood-clot in the peritoneal cavity on the second occasion than at the first operation.

There is another interesting paper on the same subject by Dr. Edgar, also published in the 'Edinburgh Med. Journ.' for 1899. In the case he reports both sets of uterine appendages were removed at the same operation ; a recent tubal mole was found on one side, and an older one on the other. Dr. Edgar says "that all cases quoted as repeated ectopic gestations are really such is, however, doubtful," and he gives instances which appear to him to be of a doubtful nature. He contends that where the diagnosis rests on clinical facts alone the cases should be placed in a separate list, instead of being

classified with those where definite proof has been obtained by operation or otherwise.

Dr. Peter Horrocks thought that the specimen shown by Dr. Croft was well worthy of further examination and report by a sub-committee. He did not think the fact that ovarian tissue was not found in all parts of the wall was proof that it was not an ovarian ectopic gestation. Neither could he see any *a priori* reason why an ovum should not become impregnated and develop whilst still in a Graafian follicle. He had seen one or two instances of repeated ectopic gestation in the same patient. He related a case in which he had removed a ruptured tubal gestation by abdominal section some eight years ago with the late Dr. Waller, in Sydenham. A year or more later he was called to see the same lady by Dr. Jolly, of Sydenham, who considered that she had a second ruptured gestation. There was a mass behind the uterus which pushed the latter forwards, but he had considered that in all probability it was not another extra-uterine fœtation, chiefly on the ground of its rarity. However, as the pain increased and the temperature rose, an incision was made *per vaginam*, and a lot of black clots were removed. These were examined by the Clinical Research Association, and chorionic villi were found. He did not know whether there was any instance on record of ectopic gestation occurring three times in the same patient.

Mr. Bland-Sutton, in reply to the President's suggestion, said he could not in any satisfactory manner discuss the question of ovarian pregnancy on a specimen in which gestation had gone so far as in Dr. Croft's specimen. He would be convinced when he saw "an early embryo and its membranes contained in a sac in the ovary." This he considered a fair requisition, and corresponded with the facts on which tubal pregnancy was based. Only those who were familiar with the flimsy evidence, false facts, and fancy on which the notion that pregnancy in the ovary occasionally occurred, could appreciate the necessity for a rigorous proof such as he required. Mr. Bland-Sutton said he was quite open to conviction on the matter of ovarian pregnancy, and that his attitude towards the whole question was that of a very active sceptic.

After a few remarks by Dr. Heywood Smith,

The President agreed with Mr. Bland-Sutton that van Tussenbroek's evidence, though important, was not conclusive. He himself had indicated sources of error in accounts of cases of alleged primary ovarian gestation in his notes on Dr. Arthur Beale's case of minute fœtus found in the peritoneal cavity. The notes were published in the Obstetrical Society's 'Transactions,' for 1893. Still, it was unscientific to insist

that this form of gestation was impossible. Perhaps Dr. Croft's specimen, which would be examined by a committee, might be quoted in future days as historical, being with van Tussenbroek's report the evidence which first convinced us of the possibility of primary ovarian gestation. The fact that both Fallopian tubes were normal did not preclude the possibility of very recent tubal gestation in one of them. This fact was interesting in relation not only to Dr. Croft's, but also to Dr. Lewers's case. The President had reported in the 'British Medical Journal,' vol. ii, 1891, p. 789, a case where repeated gestation had probably occurred within a very short interval, remarking that "tubal abortion very early in pregnancy need not necessarily spoil the tube for its functions, nor prevent subsequent pregnancy in its canal."

Dr. Croft, in reply, thanked the Fellows for the interest they had taken in his paper, and would much appreciate the opinion of a committee appointed to examine further and report on the specimen. He then referred briefly to a case that had occurred in the practice of a colleague since the paper had been sent in. The patient was operated on for abdominal hæmorrhage thought to be due to a ruptured tubal gestation. On the abdomen being opened and the blood removed, the tubes were found normal and free, but the bleeding was found to be proceeding from a small ruptured cavity in an ovary of ordinary size. The cavity proved to have the structure of a corpus luteum, and its contents to be a small ovum presenting on microscopic examination definite evidence of chorionic villi. He thought this specimen, which he had himself seen, would be likely to accord with the criteria of a primary ovarian gestation as stated by Mr. Bland-Sutton. Dr. Croft hoped that he would be able to persuade the owner, Mr. G. P. Anning, of Leeds, to bring his specimen before the Society at a future meeting.

Dr. Lewers also briefly replied.

DECEMBER 5TH, 1900.

ALBAN DORAN, F.R.C.S., President, in the Chair.

Present.—32 Fellows and 6 Visitors.

Books were presented by the Council of University College, the Clinical Society, the Edinburgh Obstetrical Society, and the Société de Médecine de Rouen, and Dr. Temesváry.

The following gentlemen were proposed for election: Hughes Reid Davies, M.R.C.S., L.R.C.P.Lond.; Harry Littlewood, F.R.C.S. (Leeds); Henry Higham Wigg, M.D.Brux. (Adelaide); F. J. I. Willey, M.B., B.S.

James Sherren, L.R.C.P.Lond., M.R.C.S.Eng., was elected a Fellow of the Society.

TWO CASES OF PAROVARIAN CYST WITH TWISTED PEDICLE, IN WHICH THE OVARY ONLY (AND NOT THE CYST) WAS CONGESTED AND INFLAMED.

(See Plate XXVI.)

Shown by HERBERT R. SPENCER, M.D.

THE two specimens shown to-night are parovarian cysts, with the corresponding ovary and broad ligament.

The pedicles (the broad ligaments) were twisted, with the result that in each case the ovary became strangulated and inflamed, and adherent to the surrounding structures. The parovarian cyst, however, was neither congested, nor inflamed, nor adherent (except to the ovary). It is to place on record this peculiar feature that I exhibit the specimens.

The effect of the torsion of the pedicle on *ovarian* cysts—the strangulation, engorgement, degeneration, inflammation, and adhesion to surrounding parts—is well known to all gynæcologists. The explanation of the limitation of the engorgement to the ovary in the cases of the parovarian cysts exhibited may perhaps be the dense covering of the ovary, and the greater vascularity of that organ, while the parovarian cyst can relieve its engorgement by hæmorrhage into the cyst, or into the peritoneum (as happened in these cases), the blood in the ovary, confined by the dense capsule, infiltrates the tissues of the ovary, and gives rise to the inflammation of the organ which is seen in the two specimens. The following are brief notes of the cases.

Case 1.—Miss C. I. P—, aged 16 years, a virgin, was seen by me, in consultation with Dr. Walter Rigden, on September 26th, 1900, for pains in the abdomen and a tumour which Dr. Rigden thought to be ovarian.

The patient was first unwell at twelve years of age. She was at first regular every three weeks, but of late every four weeks, the flow lasting for one week. She always had pain in the lower abdomen, sometimes before the flow, and generally for two days after the flow, and occasionally for the third day.

The patient first noticed pain in the abdomen apart from menstruation a year and a half ago, when she awoke with the pain on two consecutive mornings. The attack of pain came on again six weeks later, and again after a month's interval; it was "like a stomach-ache." During the present year she has had attacks of this pain

DESCRIPTION OF PLATE XXVI,

Illustrating Dr. Herbert Spencer's specimen of Parovarian Cyst with Twisted Pedicle, in which the ovary only (and not the cyst) was congested and inflamed (Case 1).

The parovarian cyst is seen to be healthy, and surrounded by a healthy Fallopian tube and ovarian fimbria; both are free from signs of congestion or inflammation except the cyst in the neighbourhood of the ovary, where there is a layer of lymph which glued the ovary to the cyst. The ovary is of a dark red colour, is inflamed, and has a thin layer of lymph on its surface.

every few weeks. During the last two months she has had two severe attacks, but has only once had to lie up in bed on account of the severity of the pain, and then only for two days. When this pain was present she always felt sick, and vomited on a few occasions. The pain was also located in the left hip, and generally went into the knee. There were also two tender spots, one above the left anterior superior iliac spine, and the other over the left side of the lower lumbar vertebræ. On examination I found a tumour of the size of a large fist, tender, not freely moveable, but distinct from the uterus. I diagnosed it as an ovarian dermoid, with torsion of the pedicle. At the laparotomy, performed on October 5th, 1900, I found that the tumour was a unilocular parovarian cyst of the left side. The pedicle was twisted one whole turn, as by the tumour's rotating in the direction of the hands of a clock, when the tumour was held in the hands of the operator standing on the right side of the patient.

The ovary (see Plate XXVI) was of twice its normal size, of a black-red colour, and adherent to the adjacent surface of the broad ligament covering the cyst, and slightly to a coil of small intestine. The tumour was otherwise not adherent, and not even appreciably congested. The operation (which lasted thirty minutes) was simple, and the recovery uneventful; the wound healed by first intention, and the patient has had no trouble since the operation, and is quite well.

Case 2.—H. H—, aged 23, a virgin, was admitted into University College Hospital on October 26th, 1900, complaining of pain in the lower part of the abdomen and sickness. She first had attacks of pain and sickness three or four years ago, and since then she has had several similar attacks; one of these a fortnight ago lasted seven days. Menstruation came on during this attack, and the patient lost less blood than usually. Menstruation began at fourteen years of age; the

patient had been regular every four weeks, the flow lasting three or four days. She does not lose much, only using one diaper daily. The past history contains nothing of importance. On admission the patient was healthy-looking, but rather pale. The breasts were rather small. The abdomen was distended (unequally, more on the left side than on the right) by a tumour, which reached up to a height of 8½ inches above the pubes. It was dull to percussion, very soft and cystic, evidently thin-walled, and distinctly fluctuating, though not yielding a clear fluctuation-thrill. There was resonance in the epigastrium and flanks. On vaginal examination the hymen was intact, the cervix small, the uterus slightly retroverted, not enlarged, and freely moveable. The tumour could be pushed down till it was felt in front of the uterus. It was diagnosed as a tumour of the ovary.

Abdominal section was performed on October 30th, 1900, by an incision about 2¾ inches in length. There was a little blood-stained fluid in the peritoneum. The tumour was in the right broad ligament, and was distinct from the ovary. The tumour was but slightly congested, if at all. The ovary was enlarged to twice its normal size, and of a deep black-red colour, and slightly adherent to the adjacent part of the cyst and of the abdominal wall. The congestion of the ovary was due to twisting of the pedicle, *i. e.* of the broad ligament.

The pedicle was tied with silk, and the tumour and ovary were removed; the abdomen was closed by silkworm gut through-stitches, silk stitches to the fascia and horse-hair to the skin. The operation lasted eighteen minutes. The highest four-hour temperature after the operation was 99·2° next day; during the next four days the highest temperature was 98·6°; afterwards it did not rise above 98·4° till her discharge, quite well, on November 23rd. The wound healed by first intention, and the scar was 2 inches in length.

Dr. Boxall suggested that the absence of congestion in the cyst might be accounted for by the tension within it acting on the cyst-wall.

Dr. McLean and the President having spoken,

Dr. Spencer, in reply, said that he was surprised to hear that Dr. McLean considered that parovarian cysts underwent torsion more frequently than ovarian cysts; he was glad to find that the President's experience was in accordance with his own on this point. Dr. McLean's method of describing rotation as "from without inwards," or *vice versâ*, was very faulty, firstly, because a tumour which was centrally situated might be described with equal correctness as rotating in either direction; secondly, because a tumour might twist its pedicle by rotating from above downwards, or *vice versâ*. He especially drew attention to this point, as the greatest carelessness or inaccuracy was noticeable in the records of twisted pedicles. An accurate but cumbersome way for an operator to describe a case of torsion was to say that "the pedicle was twisted as by the tumour's rotating in the direction of the hands of a clock (or *vice versâ*) when the tumour was held in the hands of the operator standing at the right (or left) side of the patient." He (Dr. Spencer) did not clearly see how Dr. Boxall's suggestion explained the absence of congestion in the cyst, though perhaps it might do so in some degree.

A CONTRIBUTION TO THE DIAGNOSIS AND TREATMENT OF RETROFLEXIO-VERSIO UTERI GRAVIDI.

By W. J. Sinclair, M.D.,

PROFESSOR OF OBSTETRICS AND GYNÆCOLOGY, OWENS COLLEGE, VICTORIA UNIVERSITY.

[Received November 19th, 1900.]

(*Abstract.*)

In a typical case of retroflexion of the gravid uterus the symptoms produce a *tout ensemble* which is quite characteristic, and should make diagnosis easy and certain. The striking constant feature is irritability of the bladder with more or less retention of urine. Simple and complicated illustrative cases are stated.

The contributions to the journals on the diagnosis and treatment of the condition have a tendency to exaggerate the frequency of complications, and the literature of the subject seems to indicate a too ready resort to operative treatment.

The special method of treatment which is advocated in the paper is extremely simple. It consists essentially in the introduction of a watch-spring pessary, care having previously been taken to empty the bowel and bladder. After the introduction of the pessary, if the patient is made to rest on her side, lying over with her face downwards as far as she can with comfort, it will be found that the action of the pessary alone restores the uterus to its normal position in a few hours. Illustrative cases are given. The whole number of cases in which the method of

treatment has been tried by the author is fifteen. These have been consecutive, and in all the method of treatment has been successful.

One case is mentioned in which the watch-spring pessary treatment was adopted owing to a misunderstanding in a case of fibroid tumour attached to the fundus uteri, which had fallen back into Douglas's space and produced the bladder symptoms of retroflexion of the gravid uterus. In this case the action of the pessary raised the tumour into the abdominal cavity.

The question of retroflexion of the uterus as a cause of abortion is mentioned incidentally. Abdominal section or any severe method of treatment of retroflexion of the gravid uterus is deprecated.

Ventro-fixation after abortion and involution is recommended in cases of adherent retroflexed uterus.

When the symptoms produced by retroflexion of the gravid uterus in an otherwise healthy woman begin to appear, they present a *tout ensemble* which should make the diagnosis absolutely certain, and the treatment should be prompt, easy, and efficacious. This must be so obvious to those among us with any considerable experience of cases of the kind, that it may seem to be a waste of the time of the Society to bring forward so soon again a subject so well worn, and hence presumably devoid of interest. But it is largely the difference of opinion displayed in the discussion referred to, taken along with the impression produced by some recent cases in my practice, and also by some recent literature, which has induced me to call the attention of the Obstetrical Society once more to the subject.

In the typical case there are always bladder symptoms, and these are usually the earliest and most prominent symptoms in the cases. They begin with frequency of micturition, followed by retention more or less marked; and this is followed by dribbling, retention, and great distress from distension of the bladder. If the relations between early pregnancy of the displaced uterus and the bladder troubles, which are constant, were better kept in mind, there would be few seriously complicated

cases to record. It is overlooking the pregnancy altogether, or seeing no causal relation between it and the most prominent symptoms, which leads to the worst consequences. As long as such oversights occur it must continue to be useful to record the histories. By way of illustration let us take two such cases brought, after futile treatment at their homes, into the Manchester Southern Hospital comparatively recently. The first case was a young married woman, who gave the usual history of amenorrhœa and early signs of pregnancy. Early in the third month of pregnancy she began to suffer from irritability of the bladder, and about three weeks later she had to send for a doctor on account of complete retention. The doctor used the catheter twice in the course of a week. According to his account he did not use it oftener because he was told the patient was passing water frequently. When the patient was admitted to the hospital she was in great pain, and the abdomen was enormously distended. The width of this cystic tumour low down above the pubis made it strikingly in contrast to the pregnant uterus rising the same height in the abdomen. Inquiries were naturally made with regard to the bladder, and we were assured that urine was passed frequently, with dribbling at times. When the catheter was passed slightly turbid urine began to come with considerable force, and altogether 120 oz. of urine were drawn off, becoming more turbid towards the end; then under pressure from above the pubes 18½ oz. of a thick purulent fluid passed through the catheter. By this time the abdominal tumour had completely disappeared; it was a distended bladder, and there was nothing else abnormal in the abdomen. The pregnant uterus was so pressed down as to make the perineum distinctly bulge out, and there was even some œdema about the anus. Apart from the bladder troubles arising from atony and moderate cystitis, the after-treatment of the case was simple and completely successful by the method to be described in the sequel.

Another and a worse case illustrates several points of importance in the treatment of bladder complications. It did not appear that pregnancy had been diagnosed during the time the patient was at home under treatment. There was a history of amenorrhœa for fully three months; the age of the patient was said to be thirty-eight years, and she had had nine children. She was admitted to the Southern Hospital very late one night, apparently in great pain, and almost collapsed. The story was that she had been attended for thirteen days by a medical practitioner, who for the last eight days had been passing the catheter daily on account of retention. The day before admission the medical attendant had punctured the bladder above the pubis, and at the time of the patient's admission, thirty hours afterwards, no urine had been passed by the catheter or otherwise since the puncturing. On examination it was found that the bladder was greatly distended; there was a hæmatoma in the anterior vaginal wall to the right, and the rest of the anterior vaginal wall was sodden either by œdema or infiltration of urine. The displaced uterus was pressed very low on to the perineum, and dilating the anus. On closer examination, with the aid of the speculum it was discovered that the anterior vaginal wall was quite black and evidently largely gangrenous, while exploration of the urethra, with a suitable probe, revealed false passages leading chiefly into the cellular tissue between vagina and bladder. A male catheter was passed, but only a few ounces of urine came through. Incision through the black wall of the vagina and bladder appeared to be the best course, and this was adopted. The tissues contained a good deal of gas and extravasated urine, and when the bladder was opened there was a rush of foul-smelling urine, pus, slime, and blood-clots. The reposition of the uterus was easily effected by a modification of the method to be described later. The patient recovered after abortion, and with the loss of a considerable portion of the bladder and vagina, which sloughed away. She declined any further opera-

tion, and has still, I believe, a large vesico-vaginal fistula.

There can be little doubt that in this case the puncture practised the day before caused the hæmorrhage into the bladder, and the formation of a hæmatoma about its neck. The injury done to the urethra is also a point of great interest. The pressure of the cervix uteri upon the neck of the bladder, and the distortion and lengthening of the urethra by the dragging upon it by the cervix, are facts which are not universally kept in mind. It is not easy to pass the catheter in a well-marked case of retroflexion of the gravid uterus producing retention of urine.

In the case just mentioned the free incisions into the vaginal tissues and the opening of the bladder probably saved the patient's life. As a rule the vesico-vaginal fistula can be closed when the vesical catarrh is cured, if it does not close spontaneously. It is difficult to conceive of a case, in which any bladder complications could be so easily and safely treated by abdominal section. Incision through the vagina is probably also the best treatment in sloughing and exfoliation of the bladder mucosa after great distension.

As a rule the cases are easy to diagnose, and the treatment is simple in the extreme. Adhesions and consequent incarceration or fixation must be of rare occurrence. In all my experience I have met with only two such cases: in one the adhesions must have been slight, for manipulation under anæsthesia and the introduction of a padded pessary sufficed to replace and retain the uterus in position, and the patient went to full time; in the other abortion occurred, and I lost sight of the patient. It stands to reason that such complications of pregnancy must be very rare, for a perimetritis of such severity as to produce retroflexion with strong adhesions must almost inevitably also cause sterility.

In the full conviction that cases of retroflexion of the gravid uterus are, almost without exception, originally simple uncomplicated abnormalities which are easy of

correction, I have read with wonder and regret a contribution by Dührssen, which appears to me to greatly exaggerate the number and importance of certain displacements. Its title, when translated, amounts to—"On Sacculations, Retro-deviations, and Flexions of the Gravid Uterus, with special reference to the so-called Retroflexio Uteri Gravidi Partialis." The paper was read at a meeting of the Obstetrical Society of Leipzic, and was published in the 'Centralblatt für Gynäkologie,' August 13th, 1898. There is much that is startling in this contribution besides the title: it contains a schema of classification of varieties, introducing heads and subheads, and further subdivisions down to *epsilon*. But most of all is to be deprecated the levity with which methods of treatment are discussed, including abdominal section, symphysiotomy, vaginal section of the uterus, and even total extirpation, as if these operations might be by no means extraordinary occurrences. After these the method of treatment by puncture of the ovum through the cervix or vagina, when the ordinary manipulations have failed, must appear to the inexperienced reader as simple, safe, and ordinary.

In the discussion which followed no mention was made of the simplest and most efficacious method of treatment of all, from which fact may be inferred that it was not practised by any of the gynæcologists present. The treatment was, therefore, not known or not appreciated. It is, however, satisfactory to mark that a tone of polite deprecation of the heroic measures mentioned by Dührssen pervaded the discussion.

This incident has perhaps received too much attention here, but it is introduced to indicate the unnecessary lengths to which some operators will go unless firmly checked by professional opinion. The publication of cases treated in a somewhat heroic fashion, in this country and abroad, must have the same misleading if not demoralising effect upon many comparatively inexperienced men who, faced with the responsibility of treating diffi-

cult cases, are groping for guidance from the writings of "authorities" which their own experience may not supply. There is already in the English and American literature of the subject a considerable number of cases of abdominal and vaginal section and puncturings of the uterus and bladder, which, with ordinary care and patience at the outset, should never be necessary.

The usual method of treatment is, as a rule, successful; the emptying of the bladder and rectum, followed by manipulations. These manipulations are usually accompanied with placing the patient in certain postures and administering an anæsthetic.

This method has its drawbacks; manipulations of the uterus are liable to be followed by abortion, and all patients dislike, many dread, being made unconscious by ether or chloroform.

Owing to these drawbacks, and the occasional failure of manipulation, other comparatively simple measures have been tried, such as the use of soft rubber bags or balloons introduced into the vagina or rectum, and filled with air, water, or even quicksilver.

In the discussion on Dr. Munro Kerr's paper on "Incarcerated Retro-displaced Gravid Uterus," read at a meeting of the Obstetrical Society on the 4th of last April, as reported in the 'British Medical Journal,' I do not see any reference to the adoption of what I believe to be the simplest and best method of all, viz. the use of a watch-spring pessary introduced into the vagina after due preparation of the patient. Since I began to employ this method of treatment, between five and six years ago, it has been invariably successful in a series of fifteen cases. It would be absurd to claim for it universal suitability, but the record, even in the hands of a single individual, must at the least mark it as a useful addition to our own methods of treatment.

The efficacy of the elastic ring was to me an accidental discovery. A lady suffering a good deal of distress from the bladder, owing to retroflexion of the gravid uterus,

came under my care, and it was arranged that in the morning she should be put under an anæsthetic and have the uterus replaced by manipulations in the ordinary way. When visited in the evening she was complaining a good deal of bladder discomfort, and the fundus of the uterus was found to come very low, causing also some undue consciousness of the presence of the rectum. I emptied the bladder completely with the catheter, and, thinking of diminishing the uneasiness, I pushed the uterus up a little and introduced an elastic ring in the hope of giving some relief during the night. In the morning I learned that the patient had passed a fairly good night, and felt much easier. The anæsthetist arrived, and without more ado proceeded to administer gas and ether. When the patient was ready she was put on the operating table, and when I made an examination before beginning manipulations, I was surprised to find a tumour above the pubes. This was discovered to be the pregnant uterus ; the ring had found its way deep into the hollow of the sacrum, and was maintaining the uterus well up in the pelvis. Nothing was done ; the patient was put back to bed, the pessary was left *in situ*, and the treatment of the case was finished.

In thinking over this incident it did not seem to me to be a mere accident. The pessary was slightly too large to have been used by a patient not lying in bed ; it must have assumed in the vagina a more or less elliptical form, and acted as a lever, whatever may be said on theoretical grounds to the contrary. The lower anterior portion of the vaginal canal is looser and more moveable than the upper portion. Every respiration depresses the lower anterior wall, and with it the lower portion of the ring ; a cough or a sneeze must produce a sudden depression of the lower end, and a tilting upwards of the upper end ; voluntary efforts, such as in attempts at micturition, if they do not displace the ring, must produce the effects of manipulation, but by pressure more evenly applied, and therefore less likely to produce

hæmorrhage into the tissues of the ovum, and consequent abortion.

So much for theory. An opportunity soon came for a practical trial—a typical case of retroflexion of the gravid uterus at three months, with distended bladder. The preparation consisted in putting the patient to bed and making her lie on the left side. To make sure of having the rectum empty, an aperient, consisting of calomel, followed by sulphate of magnesia in acid syrup, was administered, and in due course was reported to have acted well. The catheter was passed, and the bladder was emptied just before the ring was introduced. A ring was selected of which the lower end when compressed by the vagina could be got to pass just within the ostium vaginæ without causing discomfort, and the patient was told to lie as much as possible on the left side. Next day the uterus was in its normal position, and the patient required no further attention. The ring was left *in situ* for several weeks.

Take as another example a very simple case. M. D—, aged 32, admitted to the Southern Hospital May 13th, 1899. Last menstruation February 15th. Complains of pain in back and bearing-down discomfort. No retention of urine. Diagnosis as result of examination, retroflexion of gravid uterus.

May 13th.—*Soft ring* inserted.

May 14th.—Fundus has risen considerably, but not yet quite normal in position. *Watch spring* pessary introduced.

May 15th.—Uterus normal in position; patient discharged.

Again, for illustration, take House Surgeon's notes of a more complicated case. F. F—, aged 36, admitted to the Southern Hospital June 27th, 1900. Married ten years, eight children. Last confinement seven months since. One miscarriage at two months, seven or eight

years ago. Says that when two months pregnant eight years ago, she had a fall which caused a miscarriage. About three years later, when pregnant about four months, she fell off the sofa, and found that night she could not pass water. Consulted a doctor, who did something without using instruments, and she then went to full time without more trouble. Since then she has had two children without any unusual symptoms.

Present condition.—She has not menstruated since March 17th. On the night of June 21st she found she could not pass water, so she went to a doctor, who drew off the urine. Since then till to-day (June 27th) the doctor has drawn off the urine twice a day.

Examination. — *Abdomen :* large distended bladder. *Per vaginam :* A large mass filling hollow of sacrum and nearly whole of pelvis continuous with the cervix uteri, which is pushed high above the symphysis pubis and directed forwards. Urine, *which was ammoniacal,* was drawn off. Salol, etc., prescribed.

The patient was again examined in the afternoon by Dr. Sinclair, who inserted a large watch-spring pessary in the vagina.

June 26th.—Resting; comfortable; but catheter required.

29th.—Can now micturate freely; tumour felt in pelvis and in hypogastrium.

30th.—Uterus in normal position above the brim. Morphia administered owing to irritable bladder. Salol, etc., continued.

July 4th.—Pessary changed. Treatment of cystitis continued.

10th.—Discharged well. Urine clear.

The action of the elastic ring is well illustrated in the history of the following somewhat curious case. The ring was inserted in the mistaken belief that the case was one of retroflexed gravid uterus. In the evening of July 23rd, 1900, the House Surgeon sent word to inform

me that he had admitted a patient with a distended bladder and retention, and a tumour down under it in the pelvis. He suggested retroflexion of the gravid uterus, and asked if he should do the usual things and introduce a ring. To this I agreed. When I called at the hospital next forenoon, expecting another successful case, I found the following notes:

"E. Y—, aged 52. Admitted July 23rd, 1900. In December, 1899, patient ceased to menstruate; till then regular; twenty-eight days; duration four days; quantity moderately large; dysmenorrhœa a day before the flow. Eighteen months ago patient first had difficulty with her water. This occurred only at the menstrual periods. On one occasion the catheter had to be used. Difficulty in micturition increasing during last six months. On the night before last (July 21st) patient got up to pass water and found she could not. A doctor was sent for, and he drew it off. On Sunday (yesterday) she could micturate spontaneously. This morning the difficulty has returned.

"*Examination in out-patient room.*—Bladder distended, retention. Urine drawn off.

"*Abdominal palpation.*—No swelling or tumour remaining.

"*Examination per vaginam.*—Cervix and vaginal portion pushed up behind symphysis—high up. Anterior fornix empty; posteriorly an elastic mass in Douglas's space.

"*Patient admitted to the hospital.*—A large ring pessary was inserted in the vagina, so large that as it rested there it assumed an elliptical shape.

"July 24th.—A mass can now be felt in the hypogastrium, reaching a little short of the umbilicus. That in Douglas's space is smaller, but not quite gone." The patient was comfortable, and had passed urine without the catheter. The case struck me as a curious illustration of the action of the ring aided by posture, and I did not interfere except with regard to medicinal treatment. In other two days the uterus with a fibroid tumour was

felt in the abdomen. The pessary was changed for one more suitable for active work. The patient was discharged well on August 4th. She was seen on the 29th of October, and was then quite comfortable. The case illustrates the occurrence of symptoms produced by downward displacement of a fibro-myoma of the uterus undergoing involution, and shrinking so as to allow it to drop after the menopause. I have known of the resort to hysterectomy in such a case, but that is another subject. The relevant point here is that the ring acted on the tumour as it has done in every case of retroflexion of the gravid uterus that has come under my care since the treatment was first adopted.

There was one partial exception to which attention may be drawn. In the badly managed case previously referred to in which there were hæmatoma, hæmaturia, and gangrene of the bladder and vagina, the vaginal portion of the uterus could not be reached by the finger on ordinary examination, and there was no room in the vagina for a pessary. It was only after a vesico-vaginal fistula had been made under anæsthesia, and the blood in the bladder and in the hæmatoma had been cleared away, that it was possible to touch the external os. The vaginal portion was then seized with a volsella and traction made upon it, while the lowest portion of the body of the uterus was manipulated upwards in order that room might be made for the elastic ring. After that the case, as far as the action of the ring was concerned, proceeded as in all the rest. The operation, followed by the introduction of the pessary, took place on the 29th of April. Abortion occurred on the 5th of May, with the uterus in its normal position. If it had come on with the uterus in an extreme position of retroflexion, with ammoniacal urine and the débris of a sloughing vagina constantly flowing into the vagina, the final result would probably have been even worse than a vesico-vaginal fistula three quarters of an inch long by half an inch wide.

In order that the ring treatment without anæsthesia, without disagreeable posturing, without manipulations, may be universally successful, it will be necessary to get patients to follow implicitly the directions laid down by the medical attendant. Hitherto I have heard of only one failure. The treatment was recommended in answer to a letter of inquiry about the case of a patient on whom I had operated a year or two before. As far as the doctor was concerned the treatment was carried out in every detail, and he kindly took the trouble of letting me know it had failed after several days' trial. This led to the admission of the patient into the Southern Hospital. The same treatment was repeated, and the uterus was in its normal position within twenty-four hours. The presence of a nurse and the absence of any excuse or pretext for getting up probably made all the difference between failure and success.

Without going into any further details of cases, it may be as well to refer in conclusion to some points connected with the subject.

There is the question of the part played by retroflexion of the uterus in producing abortion. It is, in my opinion, probably the most common cause of repeated abortions in the same woman, just as deep laceration of the cervix uteri is the most common cause of repeated miscarriages or premature labours. In *chronic* retroflexion of the uterus the posterior lip is *always* found thickened and eroded at the child-bearing time of life. When after abortion, or during the treatment required for incomplete abortion, the posterior lip is thick and eroded, we may with confidence assume chronicity of the displacement, and infer that the retroflexion is the cause, or part of the cause, of the abortion, and act accordingly.

An objection to the elastic-ring treatment may be raised by some, who assume a difficulty in differentiating between simple retroflexion of the gravid uterus and extra-uterine pregnancy. If we trust only to digital

examination mistakes may occur; but with care and patience in obtaining the facts of the case from the patient, mistakes are hardly possible. Without discussing the differential diagnosis, I should like to call attention once more to the fact that in retroflexion of the gravid uterus the first prominent and constant symptom is distress referred to the bladder; in ruptured tubal pregnancy, whether the blood be intra- or extra-peritoneal, the constant and prominent symptom is pain not referred to the bladder. It is only after suppuration in a broad-ligament hæmatoma that the bladder may suffer.

There are many varieties of complications arising in pregnancy of the retroflexed uterus with tumours either of the uterus or ovary, but I would submit, with all respect for the judgment of those who have discussed them, that in the early stage they are cases of tumour complicated with pregnancy, and to be dealt with from the gynæcological, not from the obstetrical, standpoint, and consequently in pathology and treatment they belong to an entirely different category.

In many discussions much, vastly too much in my opinion, has been made of adhesoins binding down the uterus in its abdominal position. As has been already hinted, I am strong in the conviction that firm adhesions producing retroflexion and pregnancy cannot exist in the same case. If they could exist then reposition by manipulation would be impossible. When such a condition is diagnosed, would it not be best to conduct an abortion as an operation to be finished at a sitting, not to risk infection, or incomplete abortion, by hesitating or feeble measures? After involution the uterus could be put in a position favourable to conception, normal pregnancy, normal labour, and normal puerperium, by ventrifixation. Hysteropexy in the non-pregnant uterus is an easy and safe operation; on the pregnant uterus it is formidable and dangerous. Any operative proceedings which might be adopted in order, to some extent, to diminish the danger, would almost certainly cause abortion. Is hystero-

pexy in the pregnant woman then a justifiable operation?

Have not the ill effects of the use of the catheter received too little attention? An advantage claimed for the pessary treatment is that it reduces to the minimum the necessity for employing the catheter.

With regard to nomenclature, I have used Latin terms, in order to avoid controversy. Is it *retroflexio* or *retroversio?* My own conviction is that retroflexion is the common and formidable complication. With version you do not find the dragging on, and lengthening, and distortion of, the urethra, which produce retention and the evils that arise from that condition.

The terms "incarceration" and "fixation" have been purposely avoided. In all cases of retroflexion there is incarceration by the pelvic muscles, even when the uterus is still too small for incarceration by the promontory of the sacrum; every gynæcologist who has any considerable experience of hysteropexy must be convinced of this. If, then, every case, or almost every case is incarcerated, the term is superfluous; the few exceptions, if they exist, are those in which the uterus is bound down by adhesions. "Fixation" is the proper term for this condition; and for it might be reserved the designation *retroflexio uteri gravidi fixati*. The absence of any such qualifying term would indicate a simple case of retroflexion with incarceration by the normal pelvic structures, whether muscles or bones, or both.

How does the pessary act? Is it a lever? My belief is that it acts as a lever of the first kind, with a very short limb posteriorly; but it will be soon enough to discuss the theoretical point when there is a fair concensus of opinion that the clinical results of its action are such as I have endeavoured to describe.

The PRESIDENT agreed that retention of urine and irritability of the bladder were very important symptoms for diagnostic purposes. Of recent cases, Konrad's, of Buda-Pesth, was interesting ('Centralblatt f. Gynäk.,' 1900); relief came too late. Sloughing of the mucous membrane of the bladder and

death followed abortion, which occurred three days after reduction of the uterus. He had referred at the April meeting to Unterberger's case, where the displaced pregnant uterus obstructed the bladder and forced open the urachus. Lastly, he dwelt on Gemmell's case, at Liverpool, where a woman was seized with abdominal pain and retention of urine at the third month, and backward displacement of the gravid uterus was suspected. The mass in the pelvis, however, was found to be a fibroid, which was enucleated through an abdominal incision. Pregnancy continued to term ('Lancet,' Nov. 17th, p. 1413). As to difficulty in keeping the reduced uterus in place, the President referred to Szánto's case ('Centralbl. f. Gynäk.,' 1900) where the displacement was attributed to relaxation of the supports of the uterus, caused by typhoid fever; the uterus was replaced manually. Under such circumstances recurrence of the displacement was no doubt very probable.

Dr. Inglis Parsons had found that the air-ball pessary, which could be distended after its introduction into the vagina, answered very well, and had succeeded in every case. He preferred this gradual method of reducing the uterus to the more rapid method of manual reposition, because it was less likely to produce abortion. Cases of retroversion bound down by adhesions were not, in his experience, at all common, and he had never come across a case of this kind in which pregnancy had occurred. If confronted with this complication he would prefer to open the abdomen, free the adhesions, and hope the pregnancy would go to term, rather than allow abortion to occur before the abdomen was opened.

Dr. Galabin said that he thought Prof. Sinclair's paper was valuable in calling attention to a mode of treatment the value of which would seem not to have been duly appreciated, provided that it proved as successful in the hands of others as in those of the author. He did not think, however, that this treatment ought to supersede the even simpler one of immediate taxis. He was accustomed to place the patient in the knee-elbow position, and apply pressure to the fundus, first from the vagina, then, if that failed, from the rectum. His experience was that an anæsthetic was not required in one case out of twenty. He had been accustomed, twenty-five years ago, to restore retroversion of the gravid uterus in the out-patient room without even admitting the patient to the hospital. In some cases, however, an anæsthetic alone rendered the taxis practicable. He had never finally failed to reduce a uterus, nor had found it necessary to induce abortion, and for many years had employed nothing but immediate taxis; but formerly had occasionally had to employ elastic pressure by an air-ball in the vagina. Either this restored the uterus by itself, or after the uterus was somewhat raised the taxis succeeded. His experi-

ence, therefore, strongly confirmed Prof. Sinclair's view, that firm adhesions in connection with retroversion of the gravid uterus are very rare. He had not found abortion follow immediate taxis, but had known it occur during the use of elastic pressure. He had not employed the watch-spring pessaries as a primary treatment, but had always employed them, both for keeping up the uterus when restored, and in cases in which the restoration at first did not appear quite perfect. In future he should certainly try the plan when restoration could not be effected without an anæsthetic. As regards the mechanism of the pessary, he attached even more importance to a leverage which Prof. Sinclair had not mentioned than to the one which he did mention. This resulted from the traction on the cervix produced by stretching backward the posterior vaginal fornix. In this case the uterus itself was the lever; the fulcrum was the position of the internal os, where the uterus is most fixed by its ligaments; and the dragging of the cervix backward tended to tilt the fundus forward. It was well known that both kinds of leverage are attributed to the Hodge's pessary in its action on the unimpregnated uterus, and the same would apply to the gravid uterus.

Dr. Herbert Spencer agreed with Dr. Galabin that manual reposition was usually all that was required. He always recommended the wearing of an elastic ring pessary *after* the uterus had been replaced. On one occasion the displacement recurred while the ring was *in situ*; since then he had employed a somewhat stiff ring to retain the organ in position. He thought the method advocated by Dr. Sinclair was of value for those cases which could not be easily or immediately replaced by hand.

Dr. Drummond Robinson referred to a case of incarcerated retroverted gravid uterus which he had seen when he was clinical clerk to the late Dr. Matthews Duncan. Patient, aged twenty-four, pregnant for the first time, had retention of urine on November 6th, soon followed by constant dribbling of urine. On November 28th nine pints of ammoniacal urine were drawn off by catheter. On December 6th, after many unsuccessful attempts to replace the retroverted gravid uterus, Dr. Duncan induced abortion. On December 5th protrusion and redness of the umbilicus was noticed, and a few hours afterwards offensive urine began to ooze from it; this continued until the patient's death on December 20th. The mucous membrane of the bladder began to slough and to be passed *per urethram* soon after patient's admission to hospital. At the post-mortem examination, the mucous membrane of the bladder was almost completely absent; the bladder communicated with a fistula at the umbilicus. The uterus was not adherent in Douglas's pouch; the right broad ligament contained an abscess. Dr. Duncan

stated that he had never previously been obliged to induce abortion for this condition.

Dr. Boxall thought that we were much indebted to Prof. Sinclair for drawing attention to the fact that abdominal section, or any severe method of treatment, is rarely called for. For his part, he had never met with a case which would not yield to well-directed pressure, and he doubted if any one present had met with a case which necessitated even puncture before the uterus could be replaced. He regarded chloroform as useful in enabling the reduction to be effected with less force, and consequently with less danger of producing abortion than when no anæsthetic was given.

Dr. Ewen Maclean cited a case of retroverted gravid uterus at the fourth month in a primipara. The symptoms were urgent and, the usual manipulations failing, the patient was admitted to hospital with a view to the administration of an anæsthetic. After left decubitus, however, for several hours the uterus suddenly reduced itself into normal position.

THE ESSENTIAL FACTOR IN THE CAUSATION OF SEX: A NEW THEORY OF SEX.

By E. Rumley Dawson, L.R.C.P.Lond., M.R.C.S.

(Received October 3rd, 1900.)

(*Abstract.*)

The ovaries normally discharge ova independently of each other,—that is, they do not work simultaneously, they probably work alternately. Proof—the number of cicatricial pits or depressions the result of ruptured Graafian follicles are nearly equal in each ovary, and together they equal the number of menstrual periods passed.

Normal single pregnancy is the result of the fertilisation of an ovum from one ovary only, by the combined secretion of both testicles; therefore the male parent does not influence the sex of the coming child.

The sex of the child depends upon which ovary supplied the ovum fertilised; if the right a male, if the left a female.

This is proved by cases of ovariotomy where one ovary only is removed. The subsequent pregnancy gives a child corresponding in sex to the ovary which is not removed (see Dr. Wetherell's and Dr. McKerron's cases).

It is also proved by cases of tubal pregnancy where by operation a male fœtus is removed from the right tube, the corpus luteum being in the right ovary; and *vice versâ* a female fœtus occupies the left tube, the corpus being in the left ovary.

Cases are quoted to show that the affected tube in tubal pregnancy, and in tubal moles, is generally on the same side as the corpus-luteum-bearing ovary.

Cases where either tubal or cornual pregnancy occurs on the opposite side to the corpus-luteum-bearing ovary are unusual, and explained by two theories, viz. :

(*a*) The grasping by the tube of one side, of the ovary of the opposite side.

(*b*) The transmigration of ova.

Both theories are criticised, and both are shown to be probable ; each occasionally occurs. That the tubes can cross over is proved by cases from operations and post-mortems.

The sex theory is also proved by the presence of a portion of healthy ovary on one side, the other being disintegrated by advanced disease.

The production of twins and plural births is also considered. Here the ovaries must act at or about the same time when the sex of the twins is different, while when twins are the same sex it is proved (see Tufnell's case) that the ovary of one side had provided two ova.

Unilateral sterility is shown to account for those cases where the children are all the same sex, or where, after a child of one sex is born, the remainder are of the opposite sex.

The usual mixture of children as regards sex, which most parents have, is due to both ovaries usually being active, and thus supplying children of each sex.

There are two ovaries only, and two sexes only.

Fibroids of the uterus account for those rare cases where corpora lutea simulating, at least in size, those of pregnancy occur independently of pregnancy.

The rarity of true hermaphroditism is pointed out, no case of functional activity of both genital glands in one individual being known.

A short history of the paper is also given.

The problem of the origin and determination of sex is certainly one of the most interesting and fascinating in the whole realm of medicine ; it has, however, remained so far unsolved. It has not hitherto been discussed by this Society.

It has given rise to endless theories, most of which are incapable of proof, or else are easily disproved.

The following are some of the theories which have been advanced:

1. Due to age of parents.
2. Strength of parents.
3. Number of spermatozoa.
4. Night and morning coitus.
5. Side of wife you sleep on. (Left a female, right a male.)
6. Nutrition theories.

Geddes and Thomson ('Evolution of Sex') say a *katabolic* habit of body, *i. e.* tendency for waste to exceed repair, leads to *males*. *Anabolic* habit, where construction or repair exceeds waste, leads to *females*. Attempts to prove this theory made on tadpoles!

Dr. Andrew Wilson, F.R.S.E. ('Lancet,' September 26th, 1891, p. 713), thinks exactly the opposite—*anabolism* producing males, *katabolism* females.

Professor Schenk, of Vienna, has also a nutrition theory.

I do not propose to discuss other people's theories, but to bring before you one for which I am myself responsible, and of which I claim to be the originator, it having been evolved by me; further, I try to prove it in an entirely new and original manner.

In introducing this subject it will be necessary to shortly allude to both menstruation and ovulation.

We know that Graafian follicles are scattered through the substance of the ovary; that the Graafian follicle contains the ovum or ovule, which "contains a *germinal vesicle* or nucleus which is sometimes *double*." This vesicle contains a germinal spot or nucleolus. (Playfair, 'The Science and Practice of Midwifery,' 1884, vol. i, p. 59. See also Norris and Dickinson's American Text-Book of Obstetrics, 1897, vol. i, p. 71).

We know that the chief function of the *genital gland or ovary* is the maturing of Graafian follicles, and that on rupturing an *ovum is discharged*. The rent in the substance of the ovary then begins to heal, and its cavity

fills up, giving rise to the formation of the corpus luteum. This corpus luteum varies according to whether the ovule or ovum discharged is fertilised or not; if *not fertilised*, the site of the follicle becomes gradually obliterated, so that after about two months only a depressed cicatrix, or pit, shows on the surface of the ovary from whence the ovum was discharged. This is shortly *ovulation*.

Most authorities agree that ovulation and menstruation occur together; some hold that ovulation starts menstruation, others say there is no connection, as ovulation may occur independently of menstruation.

Dr. Robert Cory ('Lancet,' November 7th, 1891) says, "Menstruation properly considered is only the abortion of an unimpregnated ovum or egg."

If the discharged ovum *is fertilised* we get pregnancy, and the so-called corpus luteum of pregnancy. This corpus luteum of pregnancy is a very much enlarged edition of the other, and at the ninth month of pregnancy is very evident on section of the ovary, while "cicatrisation is not complete till two months after delivery" (Playfair, vol. i, p. 68).

As to which ovum is fertilised when pregnancy occurs, that of the last period, or that of the first period missed, which is Loewenhardt's theory,* opinions differ, but it does not concern us now; while as to which ovary supplied the ovum that was fertilised we are absolutely ignorant without either an operation, say for ectopic pregnancy, or a post-mortem allowing us to see the corpus luteum.

Normally both ovaries are active; in both the maturation of Graafian follicles is an almost continuous process. A Graafian follicle matures, approaches the surface, and eventually rupturing discharges an ovum, which, unless fertilised, is finally washed out of the uterus.

Now I wish especially to point out that in spite of there being *two* ovaries, they do *not normally work synchronously*, but that one ovary only discharges an

* Hart and Barbour, 'Manual of Gynæcology,' 1883, p. 87.

ovum at a time ; in fact, that double or bilateral ovulation is not normal.

Négrier says [' Researches (Anatomical and Physiological) on the Human Ovary ' (Paris, 1840)] " the ovaries perform alternately, for he finds in one ovary a recently ruptured follicle, and in the opposite ovary one coming forward." Further, he says that " in women, having double uterus and vagina, the menses have come from each side alternately."

That unilateral ovulation is the rule is proved post mortem by cases where only a few and definite number of menstrual periods have occurred ; we are then able to see and count the cicatricial pits or scars, the remains of the corpora lutea, and find them in the two ovaries together to equal the number of periods passed. We do not find that each ovary has pits or scars equal in number to the number of menstrual periods, but that if, for example, as in one of the following cases, only three periods had been experienced during life, each ovary has not three pits or scars, but the two ovaries have three scars between them.

The following cases support this :

Mr. Girdwood (Braithwaite's ' Retrospect of Medicine and Surgery,' vol. vii, January to June, 1843, Article 102, pp. 261—263) exhibits a preparation taken from a young unmarried female who he knew had menstruated thirty-six times. " The ovaries presented several indentations or small cicatrices about the size of mustard seeds. From thirty-two to thirty-four of these marks could be detected, about eighteen in one, and sixteen in the other ovary."

" A young woman died under my care. She had menstruated three times. The surfaces of one ovary presented two cicatrices, that of the other, one."

" Jane C—, aged 18, died of consumption. She had menstruated only six times. We could readily detect five depressions or cicatrices, three on one, two on the other ovary, of a sixth we were doubtful."

If, now, this single ovum be fertilised, we get what is normal in mankind, viz. a single birth; if double or bilateral ovulation were the rule, and there were always two ova shed, surely both would usually be fertilised, and twins would become the rule and single pregnancies the exception.

If, as must and does sometimes occur, the two ovaries happen to have equally matured each a Graafian follicle, we get a simultaneous, or nearly so, rupture of the follicles and discharge of the contained ova; that is, we get two ova to be possibly fertilised; for, of course, this does not necessarily always occur.

Should fertilisation of both occur we get two fœtuses, that is twins, owing their origin to the fertilisation of ova or ovules from different ovaries, the sexes differing, as we shall see later. This is not, however, the only mode of origin of twins, but it is the commonest; but I will refer to the subject of twins further on.

This brings me now to the dominant influence of the supplying ovary over the sex of the resulting fœtus. The supplying ovary is in reality the ESSENTIAL FACTOR IN THE CAUSATION OF SEX.

This, then, is my theory, that the sex of the fœtus is *not* due to the male parent, but depends on which ovary supplied the ovum which was fertilised, and so became that fœtus.

I find that a *male* fœtus is due to the fertilisation of an ovum that came from the *right* ovary, and a *female* fœtus is due to the fertilisation of an ovum that came from the *left* ovary. This I shall now proceed to prove.

We have just seen that normally one ovary discharges an ovum, and this when fertilised leads to a normal single pregnancy; if on examining a child we find it to be a male, and the right ovary to contain a well-marked corpus luteum, we are justified in saying that the ovum from that right ovary produced a male fœtus. This I find to be always so, and the following cases will prove it.

Bernutz and Goupil * (vol. i, p. 249).—"A woman, aged 34, had had three children prematurely, and was pregnant the fourth time, the condition being accompanied by extreme prostration and a good deal of pain on the right of the pelvis. At the end of the third month she expelled *per vaginam* a mole the size of an egg. [Probably uterine decidua.—E. R. D.] Six days after this she experienced most agonising pain in the hypogastric region, accompanied by severe vomiting, and soon after this she died.

"On examination a male fœtus was found in the right iliac fossa, but still attached to the right ovary by the umbilical cord. The ovary itself was ruptured on its under side. The organs on the left side were healthy. The uterus was much thickened, and large enough to admit a fœtus of three months; such an one was found in the abdomen."

Bernutz and Goupil † (vol. i, pp. 249, 250).—"A lady had borne eight children when, after an interval of five years, she became pregnant for the ninth time.

"At the third month she became very weak, had colicky pains, with symptoms of approaching labour, and died in nine hours. On opening the abdomen a large quantity of blood was found effused, and in removing this a *male* fœtus about an inch long was discovered.

"It was found afterwards that the *right* ovary was ruptured in its length, and that the fœtus had been developed therein."

Jemima Hammond.—Jemima H—, aged 40, four

* Bernutz and Goupil, 'Diseases of Women,' vol. i, p. 249, published by New Sydenham Society, 1866, quoted from 'Bibliothèque médicale,' vol. xxxviii, p. 265; and Dezeimeris, 'Journal des connaissances medico-chirurgicales,' 1837.

† Quoted by Bernutz and Goupil from 'Observation de M. de Saint Moressy, medicin de Riberac en Saintonge,' 1662 (dans Duverney, 'Œuvres anatomiques,' Paris, 1761, vol. ii, p. 350).

months pregnant. Admitted an in-patient at Westminster Hospital for stiff knee-joint.

She suddenly developed acute suppurative peritonitis, which led to her aborting. The fœtus was removed shortly before her death, which occurred on November 30th, 1889.

On examination the fœtus was found to be a *male*.* Post mortem the left ovary was normal, the *right* slightly enlarged, and containing a well-marked corpus luteum.

Tufnell's case ('New Sydenham Society's Year Book,' 1862, p. 339).—"The patient had seven years before given birth to a living child. Again pregnant. . . .

"*Post mortem* three or four quarts of fluid and clotted blood were found in the abdomen, with a small fœtus floating therein. There was a rent in the *right* Fallopian tube, and a cyst, from which the fœtus had escaped. Right Fallopian tube and ovary agglutinated; fœtus one inch long. The uterus contained a healthy male fœtus, proportionate to the date of conception. The cystic cavity in the right Fallopian tube contained a solid organised mass like a miniature placenta. There were two distinct corpora lutea in the *right* ovary."

We have here two fœtuses and two corpora lutea in the same ovary, *the right;* the sex (*male*) is only given of one fœtus. It is a twin *male* conception undoubtedly.

Dr. J. A. Wetherell's case (*left* ovary removed, subsequent birth of *male* child), 'Lancet,' April 28th, 1888.—Conception after ovariotomy.

"The patient, Ann H—, unmarried; at the age of 25, in 1882, her menstruation became irregular, and she first noticed a tumour rising in her abdomen. Her medical attendant diagnosed the case as one of ovarian tumour. She placed herself under the care of Dr. Granville Bantock in the Samaritan Free Hospital. The case was one

* By Drs. B. Potter, R. G. Hebb, and E. R. Dawson.

of fibroid tumour of the uterus in a state of cystiform degeneration. I tried to lift out the tumour, but it so invaded the broad ligament on the right side that its removal in the usual way was impossible. Fancying there was nothing to be done but to remove the ovaries, with the view of checking the growth of the tumour, I removed the *left* ovary, which was easily got at.

"The right ovary was nowhere to be found.

"I now looked again very carefully at the tumour, and as it felt as if there might be some deep-seated fluid in it, I tapped it, and got out nearly a pint of a dirty-looking fluid. There was no way of removing the tumour. I laid the tumour very freely open. She left the hospital a mere shadow of herself before her illness.

"For four years she enjoyed fairly good health. She was now quite stout and married.

"In July, 1887, I delivered her of a fine healthy child. She nurses her baby boy herself."

Here is a case of a tumour implicating the right broad ligament; the right ovary was evidently pushed away by this growth, and was not found, or it too would have been removed. The left ovary was removed. Some years after (being married) she was delivered of a child (a male). The ovum here must necessarily have been derived from the right ovary; for, although not found at the time, the right ovary or some portion of it must have been able to perform its function, in spite of the tumour in the right broad ligament four years before. Although the ovary was displaced by the tumour, the right ovary, or part of it, retained the power to mature and discharge an ovum, which, becoming impregnated, led to the birth of a *male* fœtus.

Dr. H. R. Spencer's three cases of Porro's operation ('Trans. Obstet. Soc.,' 1896, pp. 397 and 399).—Dr. H. R. Spencer removed pregnant uterus owing to fibroids in the first case. The child was a *female*, and

though the corpus luteum is not mentioned, the *left* ovary was the larger of the two.

In the third case, however (pp. 417 and 418), child boy. Corpus luteum in right ovary.

"The child extracted was a boy, and there was a well-marked corpus luteum in the *right* ovary."

Mrs. P. was delivered of a *boy* who survives. The patient died of puerperal sépticæmia. At the P.M., at which I was present, there was a well-marked corpus luteum in the *right* ovary, *none in the left*. Placental site in mid-line of the anterior wall of uterus.

The following cases help to prove my theory, though they are not conclusive, owing to the absence of mention of corpus luteum.

Taylor's case (J. W. Taylor, 'Obstet. Trans.,' 1897, pp. 183—185).—Abdominal pregnancy. Right tube, male child. "The pregnancy may be regarded as originally one of the *right* Fallopian tube. The child weighs 7 lbs., and is a *male* fœtus."

"It was impossible to say whether the right ovary had been removed with the placenta, or whether it had been left in the pelvis below the reflections of the sac."

Cullingworth's case (C. J. Cullingworth, 'Obstet. Trans.,' 1893, pp. 157 and 159).—Sac on right side; male child.

"The sac containing the fœtus consisted of the *right broad* ligament. The stretched Fallopian tube ran diagonally upwards and outwards, and then ceased to be traceable as a distinct tube."

"The fœtus was one of the *male* sex."

Meredith's case (W. A. Meredith, 'Obstet. Trans.,' 1892, p. 240, etc.).—Both ovaries diseased, right the least. Child a male. Performed double ovariotomy during pregnancy.

"The larger tumour of the two was extremely multi-

locular. The *right* ovary, situated anterior to the main or larger tumour, contained one main cavity, etc."

"Subsequently the pregnancy terminated in the birth of a well-developed *boy*."

It is only reasonable to expect that the ovary that was only slightly affected should have yielded the ovum. It was the *right* ovary that had the smaller tumour, and the resulting child was a *boy*.

J. Bland-Sutton's case (J. Bland-Sutton, 'Trans. Obstet. Soc.,' 1891, pp. 71 and 72).—Tubal pregnancy. Drawing shows sex *male*, and (?) corpus luteum in *right* ovary.

"Fluid blood has escaped from a rent in the *right* broad ligament. The Fallopian tube on that side was enlarged, and was removed with the ovary. The embryo appears to have lodged in the *right* Fallopian tube." The drawing which accompanies the case shows the fœtus to be a *male*, and what is possibly the corpus luteum in the right ovary, for the left was not removed.

On the other hand, I find that the left ovary produces ova which, when fertilised, give rise to female children. The following cases support this:

Left tubal gestation. Child female. Corpus luteum not mentioned.

Jonathan Hutchinson's case ("Case of Extra-uterine Fœtation simulating Ovarian Dropsy," 'Lancet,' July 19th, 1873, p. 71, by J. Hutchinson, F.R.C.S.; 'Braithwaite's Retrospect,' vol. lxviii, 1873).

"At the post-mortem examination we found the tumour adherent everywhere to the abdominal wall and omentum. On cutting into the cyst the body of a macerated fœtus was found. It was a *female*, and at full term. On further dissection of the parts the case proved to be one of gestation in the *left* Fallopian tube. The *left* Fallopian tube could be traced for a short distance on the front of the cyst. The left broad ligament passed downwards from the front of the cyst, and between its extremity and that of the Fallopian tube was a thickened

mass, which might perhaps be the remains of the ovary, but it was not practicable accurately to identify it."

Reeves's case ("Ectopic Ovarian Gestation," H. A. Reeves, F.R.C.S.Edin., 'Lancet,' October 25th, 1890, p. 872).—Left-sided pregnancy; child female. Right ovary cirrhotic.

"On opening the abdomen a large tumour was exposed. The shoulder and head of a fœtus were then felt. The broad ligament was then tied close to the uterus. The placenta was inside the fœtal membranes, which were enclosed between the layers of the *left* broad ligament, and the normal-looking Fallopian tube was stretched across the upper and anterior aspect of the tumour. No trace of the *left* ovary could be seen or felt, and in peeling off the membranes, which were firmly adherent in places, a portion of the posterior layer of the broad ligament, corresponding to the usual position of the ovary, was removed with them.

"The *right ovary was cirrhotic*, and was not removed. The fœtus, which looked like a full-termed one, was a *female*."

Mr. Reeves says, "There can be no doubt this was a genuine case of true ovarian pregnancy."

Remarks.—Although this is probably not the case, yet it was an undoubted *left-sided* pregnancy, with the resulting fœtus a *female*.

That the ovum came from the left ovary is rendered more evident by the fact of the cirrhotic condition of the opposite or right ovary.

Dr. Herman's case ('Trans. Obstet. Soc.,' 1897, pp. 135—137).—Disease of right ovary. Child female. No corpus luteum.

"On the *right* side a cheesy-matter-containing body was attached to the right broad ligament; examined microscopically it was thought to be the ovary.

"The fœtus was a female." Corpus luteum not mentioned.

The right ovary being disintegrated and diseased, the left ovary must have supplied the ovum, and the child was consequently a female.

Dr. Cullingworth's case ('Lancet,' August 25th, 1888, p. 391).—Left tube; child female. No corpus luteum given.

"On August 16th, at St. Thomas's Hospital, Dr. Cullingworth removed a fœtus weighing 2 lbs. 13 oz., and measuring 17 inches in length, through an incision in the anterior abdominal wall. The sac in which this was contained was very thin, and formed by the greatly dilated *left* Fallopian tube. The duration of the pregnancy was sixteen months; the fœtus was well preserved, and had the appearance of fully eight months' development."

On writing to Dr. C. to ascertain the sex, he says (September 1st, 1888), "The *child was a female.*"

I am aware that this case is not very complete, there being no site of corpus luteum given; but in tubal pregnancies it is, I think I may say, almost invariably the case that the tube affected and the ovary which supplied the ovum are on the same side of the uterus, so that I feel myself justified in ascribing the ovum to the left ovary, and hence the fœtus was a female. See a case by Dr. Lewers in 'Diseases of Women,' 1897, p. 375—*right* tubal pregnancy, large corpus luteum in *right* ovary, no corpus luteum in left ovary; also the case in Tait's 'Ectopic Pregnancy,' p. 94, by Dr. Maury, of Memphis.—Pregnancy in the *right* tube, no trace of right ovary, being lost in sac wall. Left ovary much shrivelled, and otherwise changed in appearance; also Tait's case (p. 46), and Herman's (quoted by Sutton, 'Diseases of Ovaries,' 1891, p. 367), where after removal of one gravid tube and ovary that of the other side is similarly affected.

Dr. Amand Routh ('Trans. Obstet. Soc.,' 1898, p. 307), in a case of "Uterine appendages showing hæmatosal-

pinx," says, "These bilateral appendages were removed. The uterus was enlarged, and this condition, with the dilated tube and the corpus luteum, was taken to mean that an early tubal gestation was present, especially as the corpus luteum was on the same side as the tubal swelling."

Subsequently the patient was found to be pregnant five months, "so that at the date of the removal of the appendages she must have been two and a half months pregnant. Her labour was uneventful. Her child was small." Dr. Routh now informs me that the corpus luteum was in the *left ovary;* the child subsequently born *was a girl.*

That the affected tube and the corpus luteum are usually on the same side is confirmed in the same volume (p. 318) by the drawing in Mr. Sutton's paper, the affected tube and the corpus-luteum-containing ovary being shown on the same side.

J. W. Taylor, of Birmingham ('Trans. Obstet. Soc.,' 1891, pp. 118 and 124).—Extra-uterine pregnancy. Female fœtus from left tube; no corpus luteum.

"The pregnancy had originally been tubal. It had ruptured into the broad ligament on the *left* side. The infant, a *female,* was fully developed."

Although the details in this case are few, it helps the theory, as usually the supplying ovary is on the same side as the affected tube, as I have just shown.

The following cases will help also to prove this.

Dr. Amand Routh ('Trans. Obstet. Soc.,' 1898, p. 222).—"Pregnancy in *left* tube; corpus luteum in *left* ovary. The *right* tube was normal; a nodule could be felt on the *left* tube." The report on the specimen by Mr. J. H. Targett says, "The specimen consists of the (left) Fallopian tube, ovary, and adjacent portion of the broad ligament. The ovary contains a recent corpus luteum. The Fallopian tube is dilated with an oval cyst. The histological evidence of gestation is thus assured."

Dr. Routh kindly allows me to add that this patient, whose *left ovary* was thus removed on May 9th, 1898, gave birth to a *boy* in April, 1899.

E. R. Dawson's case ('Trans. Obstet. Soc.,' 1898, p. 156). Pregnancy in *right* tube; corpus in *right* ovary.—The right Fallopian tube had contained the ovum. "The *right* Fallopian tube had ruptured. The *right* ovary contained a *corpus luteum*."

Dr. W. Duncan ('Trans. Obstet. Soc.,' 1894, p. 68) has a drawing of a case of tubal gestation. "The *right* tube had ruptured. The *right* ovary contained a large corpus luteum."

Dr. Pocock ('Lancet,' March 3rd, 1888, p. 416). Pregnancy in *right* tube; corpus in *right* ovary.—Case of extra-uterine gestation.

"The fœtus had escaped from the ruptured sac formed at or near the fimbriated extremity of the *right* Fallopian tube, where the placenta was placed. There was a well-marked corpus luteum in the *right* ovary. The fœtus was about three months." No sex is given, and though I wrote privately for it could not discover it.

Tait ('Lectures on Ectopic Pregnancy and Pelvic Hæmatocele,' p. 102, 1888) quotes a case by Dr. Wagner ('Arch. der Heilk.,' 6th, No. 2, p. 174). Left tube and ovary implicated. Child female.

"The patient was a widow 68 years old. Up to the age of 24 she had given birth to five children; in her thirty-seventh year she again became pregnant, but was never delivered of the child. Labour pains were not present. For a long period the abdominal enlargement remained constant in size, and Cæsarean section was advised. Finally the tumour began to grow smaller. Her menses returned, and fair health was experienced, the only complaint being of a feeling of weight in the abdomen. At the autopsy the tumour was found to fill the lower pelvis, and to be attached to the bladder, rectum, and uterus.

The tumour weighed about $\frac{3}{4}$ lb., and was about the size of a man's head. It was covered by a yellowish membrane. The *left tube and ovary* seemed to be growing from the tumour, the uterus being pushed from the right. The fœtus was of *female sex*."

Dr. Spencer ('Trans. Obst. Soc.,' 1898, pp. 16 and 18). —Dermoid of right ovary, child female. Incarcerated ovarian dermoid, obstructing labour. Ovariotomy during labour.

"An incision was made. The tumour was then drawn up out of the abdomen and removed. The forceps was applied. After the child was born the uterus was kneaded. The placenta was expressed. The child was a well-developed *female*, weighing at birth $8\frac{1}{2}$ lbs. The tumour was an ovarian dermoid of the *right* side, containing 16 oz. of sebaceous material and hair. It measured $4\frac{1}{2} \times 4\frac{1}{4} \times 3$ inches." Corpus luteum not mentioned. Here we have a case showing that owing to the condition of the right ovary the left ovary must have provided the ovum which was fertilised, and hence the child was a female.

Dr. McKerron has a paper on "Obstruction of Labour by Ovarian Tumours in the Pelvis" ('Trans. Obst. Soc.,' 1897, pp. 337 and 339). Right ovariotomy, subsequent pregnancy, and birth of female child. His first case was pregnant, and at the labour the child could not be delivered until the tumour—a dermoid of the *right* ovary —had been pushed up above the brim. A *male* child was then delivered. Later the tumour was removed. It was a right ovarian dermoid. She subsequently became pregnant once more, having, of course, then only the *left* ovary in her body. She was delivered on January 15th, 1897, of a living *female* child. Evidently the right ovary, though dermoid, provided the ovum for the first pregnancy described—how I shall describe under the next case quoted,—while after the *right* ovariotomy the *left* ovary must of necessity have supplied the

ovum for the later pregnancy, which was consequently of the *female* sex.

Dr. H. R. Spencer ('Trans. Obst. Soc.,' 1898, pp. 22 and 23).—Incarcerated ovarian dermoid obstructing labour; manual elevation; removal seven months later.

"The tumour was of hard consistence. . . . Applying forceps I easily delivered a large *female* child, which soon breathed, and survives. The tumour at once came down again into Douglas's pouch, and could be felt to contain two plates of bone. It was clear that the tumour was a dermoid of the *left* ovary. The *right* ovary felt normal.

"On December 9th, 1897, I removed the tumour, which occupied the *left* ovary." Unfortunately the presence of a corpus luteum is not mentioned. This case, which might at first sight seem to disprove my theory, although the great majority support it, may be explained thus. Bland-Sutton, in his 'Surgical Diseases of Ovaries and Fallopian Tubes,' 1891, pp. 66 and 67, says, "It is a fact of great interest that ovaries, even when occupied by fairly large dermoids, sometimes successfully discharge their functions." He quotes several cases—*e. g.* Mr. Thornton reported to the Obstetrical Society a case in which he performed double ovariotomy during pregnancy; the patient was twenty-two years of age. Both tumours were dermoids. The *left* one had a well-developed corpus luteum on its *outer* surface.

In 1890 Dr. Bantock performed double ovariotomy on a lady in the third month of pregnancy. Both tumours were dermoids.

That one ovary gives only one sex, and the other ovary only the opposite sex, that is to say that an ovary always breeds true, is proved by cases such as the following, where if unilateral ovariotomy is thoroughly performed any subsequent children must be developed from ova from the one remaining ovary only, and are then always of the same sex.

We do not find after the *complete* removal of one ovary that the remaining ovary yields first a boy say, and at a later pregnancy a girl.

Dr. Balding, after ovariotomy by Spencer Wells (whether bilateral, or which side is not mentioned), delivered a patient of male triplets,—not two boys and a girl, note. That is, the ovary not removed yielded three children *all the same sex*.

In a case of pregnancy occurring twice after so-called double ovariotomy—the operation was done on October 20th, 1892,—a *boy* was born June 10th, 1894, and a second child, also a *boy*, on February 25th, 1896. (Case read by Dr. R. Stansbury Sutton at Geneva Gynæcological Congress, September, 1896.)

A portion of an ovary must have been left behind in the abdomen, and of whichever ovary it was (I maintain it was a portion of the right ovary) the fact remains, that that portion of ovary "bred true,"—that is, it yielded two boys, not first a boy and then a girl. This can surely not be looked upon as a coincidence.

I now proceed to discuss those cases which seem at first sight to disprove my theory; I allude to those where the corpus luteum is on one side, while the pregnancy is on the other side.

Dr. Giles ('Trans. Obst. Soc.,' 1897, pp. 242 and 243) has a paper,—"Two unusual cases of tubal gestation." Corpus luteum in right ovary. Pregnancy in left tube. Sex not given.—"The ampullary portion and fimbriated end of the *left tube* are involved in the formation of the gestation sac. The *left* ovary is much contorted by its compression between the uterus and sac. There is no corpus luteum corresponding to the pregnancy. Right appendages. The distal portion of the tube is dilated and distended into a thin-walled fluctuating sac of hen's-egg size and shape. The tube is sealed at its

outer end" (in fact, a hæmatosalpinx). "The *right* ovary contained a recently ruptured follicle and a well-marked corpus luteum. The sex of the fœtus, which was 12 cm. in length, is not given." This is a type of those cases where the corpus luteum is found in the ovary on the opposite side to that of the tubal gestation, and though it does not help my theory, there are reasons to account for the seeming disparity, and so prove that it is, at all events, not a flaw in the theory. The blocking of the end of the right tube shows that the ovum from the right ovary must have been received by the left tube. Playfair (vol. i, p. 50 and p. 193) says, "So great is the mobility of the Fallopian tubes that there is reason to believe that a Fallopian tube may even grasp the ovary of the opposite side;" so that in this case I should have expected the child to be a male though developing in the left tube.

That in this case the receiving of a right ovum by the left tube was what probably happened, is borne out by the following detailed account of the position the tubes occupied.

'Trans. Obst. Soc.,' p. 241, 1897.—"The uterus is pushed to the right front of the pelvis, the ectopic gestation-sac of the *left tube* has developed in the posterior pelvis and hollow of sacrum, the left ovary thus being sandwiched between the sac and the left posterior surface of the uterus. The *right tube,* terminating in a fluctuating swelling, is also bent backwards, and the corresponding ovary is compressed between the swelling and the right posterior surface of the uterus. Thus the parts which are seen to present above the level of the true pelvic brim are the fundus uteri, the proximal portion of the left tube leading to the upper surface of the gestation-sac, and the proximal portion of the right tube leading to the upper surface of its terminal cystic dilatation."

Both tubes are bent backwards behind the uterus, and both ovaries are similarly displaced; so that the receipt

of the ovum from the *right ovary by the left tube* is not difficult to realise.

If, on the other hand, in this case we look upon the closure of the fimbriated end of the right tube as having occurred subsequently to impregnation (and there are no grounds on which to assume this, it being diseased), then we are forced to believe in the migration of ova.

Kussmaul ('New Sydenham Society's Year Book,' 1859, pp. 340—343) looks upon the migration of an ovum across the body of the uterus and into the opposite tube as a cause of tubal pregnancy. He gives a case, and quotes five others in support.

It would also account for a child being found in a tube of the sex which the ovary of the opposite side should produce.

The 'New Sydenham Society's Year Book,' 1862, p. 331, contains an abstract of a paper by Klob ('Wiener Wochenbl.,' xvii, p. 40, 1861) on the migration of ova.

He says: "The fact that occasionally when the uterus is duplex, and in some cases of Fallopian pregnancy, an ovum is found in that half of the uterus opposite to the ovary in which the corpus luteum is met with, has been explained by supposing that the ovum migrated, after passing into the uterus, from one side to the other." Klob contends "that in such cases the ovum really enters on the side on which it is found, that the Fallopian tube of one side becomes under such circumstances the recipient of the ovum from the opposite ovary."

This opinion is justified by a case of uterine pregnancy reported by Rokitansky, in which the corpus luteum was found in the *left* ovary, while the *left* Fallopian tube was adherent in such a manner that there could be no doubt that the *right* Fallopian tube must have been the means of conveying the ovum to the uterus.

"Further, in post-mortem examinations the existence of long tubes and moveable ovaries is far from uncommon."

The explanation of Kussmaul that there is a migration in the uterus due to spasmodic contractions of this organ Klob considers inadequate and erroneous.

I shall confine the term "Transmigration of the Ovum" to the cases termed "Intra-uterine Transmigration" by Barnes (p. 347).

B. S. Schultze's case ('New Sydenham Society's Year Book,' 1864, p. 364; 'Würz. med. Zeitsch.,' 1863, vol. iv).—Pregnancy in right tube, corpus in left ovary, "a fully matured tubo-uterine gestation and transmigration of the ovum."

"Cæsarean section was performed. . . . ."

"The placenta was adherent to the posterior wall, and through an aperture in the right segment of the fundus the right foot of the child protruded. The *right* ovary lay much nearer to the uterus than the *left*, was only half its size, and contained very few follicles. The *right* tube terminated at its abdominal end in a closed sac without any traces of fimbriæ. The *left* ovary contained the corpus luteum. The *left* tube was adherent to the uterus and impervious in the outer third of its course. The seat of rupture was a pouch as if out of a dilation of uterine end of the right Fallopian tube. This pouch was the seat of the early development of the ovum, which had been received from the *left* ovary and tube, and had crossed over the fundus uteri towards the saccular dilation formed by the uterine mouth of *right* tube. The complete closure of the abdominal end of the right tube must have completely prevented the reception of the ovum in this tube; but the obstruction of the outer third of the left tube might have occurred after the passage of the ovum from the left ovary, which contained the corpus luteum."

Sex of child not given.

This case by Schultze is by no means a convincing one of the intra-uterine transmigration of the ovum.

It may be, as he alleges, an example of it, the ovum from the left ovary and tube having crossed the cavity of the fundus uteri and developing in that portion of the right Fallopian tube which traverses the uterine wall, the so-called "interstitial" portion of the tube.

Argument for migration of ovum.—It must not be overlooked that this journey for the ovum from one uterine ostium of the tube, across the uterine cavity, to the other uterine ostium, is not a long journey, for the uterine cavity transversely (the uterus not being at the time pregnant, and so enlarged) has a lesser diameter than the vertical one, which latter constitutes the usual length of journey made by the ovum on its passage out of the uterus, and in placenta prævia cases; so that if it is capable of making the longer one, it should not be unusual for it to sometimes make the shorter or transverse journey.

Richet (quoted by Hart and Barbour, p. 16, second edition) gives the following as the measurements:

	Virgin.	Multipara.
Vertical diameter of cavity of uterus	1·80 in.	2·44 in.
Transverse ,, ,,	·60 ,,	1·24 ,,

—that is to say, the journey *down* the uterus is three times as far in the virgin as *across* the uterus, while it is twice as far in a multipara. Placenta prævia cases prove the complete vertical journey of the ovum.

Another point which is in favour of the occasional migration of the ovum, is that a woman lying in bed on her side makes the transverse diameter of her uterine cavity (or shorter journey) into, for the time being, a vertical diameter, so that gravity may help the passage of the ovum from one uterine Fallopian opening to the other.

Kussmaul, quoted by Playfair (p. 194), thinks the muscular contractions of the uterus may work the ovum across.

Arguments for the tube of one side grasping the ovary of the opposite side ("Extra-uterine Transmigration" of Barnes, 1878, p. 346).—The other theory to account for the pregnancy and the corpus luteum being on opposite sides is that the tube of one side grasps, or receives the ovum from, the ovary of the other side. This theory has the support of Playfair (p. 193), and of Klob, in his paper already referred to, and seems very probable. The case by Oldham and Wharton Jones, quoted by Barnes (p. 346), also supports it.

By this theory we can explain the closure of the abdominal end of the right tube in Schultze's case as being due to the pregnancy *in* the tube, it having previously grasped an ovum from the left ovary.

That the abdominal ostium gradually closes in cases of tubal pregnancy is becoming more widely known and admitted, and has been strongly pointed out by Bland-Sutton in his 'Surgical Diseases of Ovaries,' where (edition 1891, p. 312) he says, "Changes are in progress at the abdominal ostium, which in most cases gradually bring about its occlusion, an event usually completed by the eighth week. Occasionally at the tenth or twelfth week, or even later, the ostium is only partially closed." As, therefore, the case by Schultze is described as fully-matured tubo-uterine gestation, the closure of the abdominal end of the affected tube would be complete.

I feel therefore justified, in spite of the heading of Schultze's paper, in looking upon his case as of the right tube getting the ovum from the left ovary, especially as the right ovary is undeveloped or atrophied, *i. e.* it is extra-uterine, not intra-uterine transmigration (Barnes). I may mention that Bland-Sutton (p. 361) says that "the theory known as 'transmigration of the ovum' is unsupported by facts;" while on p. 362 he says "the corpus luteum of pregnancy has been found in the ovary on the side opposite to the gravid cornu. To explain this it has been imagined that the tube reached across the middle line and grasped the opposite ovary." Such

guesses, he says, "do not call for serious consideration;" but at all events he does not bring forward any fact or argument to disprove it. I shall try by the following cases to show it to be more than a guess, in fact a probability.

Firstly, the tubes may be of extra or abnormal length, and owing to their known mobility such a lengthened tube might easily grasp the opposite ovary. Dr. Thomas Wilson ('Obst. Trans.,' 1897, p. 172) mentions "the left Fallopian tube runs horizontally to the left for *nine* inches;" normal length is four to six inches. Mr. Sutton's own case in 'Obst. Trans.,' 1892, pp. 9 and 10, shows by the accompanying diagram both tubes on the same side of the uterus; he says "the left Fallopian tube was dilated into a cyst. The right tube is simply an impervious cord; the corresponding ovary was not detected. The atrophied tube is seen on the left side, whilst with the hydrosalpinx on the right side rupture appeared to be imminent."

As the ovary corresponding to the right tube was not found, the ovary shown in the drawing must be the left one, but both tubes are lying to that, the left side, of the uterus, and the right must therefore have crossed over the body of the uterus to the opposite side, as the drawing shows, so that Mr. Sutton's drawing helps to refute his own statement.

Mr. Alban Doran ('Obst. Trans.,' 1900, p. 135) has a case of right tubal mole which also proves that one tube may cross over to the other side; "the uterus lay rather high, the *left* tube and ovary, perfectly normal, still higher; they were pushed up by the dilated *right* tube, which had fallen *behind* the uterus, and developed towards the left side." Besides proving this point, it is confirmatory evidence of what I am trying to prove, that a tube may cross to the other side, and thus get an ovum from the opposite ovary; for, as we have just seen, the right tube developed towards the left side; the ovary contained no corpus luteum. The left ovary was

normal, and therefore was not removed; had it been I am confident it would have contained the corpus luteum.* In the following case, by Dr. Herman ('Obstet. Trans.,' 1897, pp. 135—137), "the placenta was attached to the top of the uterus, and he proceeds to explain that the pregnancy being at first tubal, the chorion protruded towards the peritoneal cavity; that at this time (from some cause he could not explain) the end of the tube was near the top of the uterus, and so the chorionic villi became attached to this part."

If therefore we have, as here, proof that the abdominal end of the Fallopian tube can be up at the top of the uterus, why should it not sometimes be close to the opposite ovary? In the 'Obstet. Trans.,' 1897, pp. 164, 165, Mr. Bland-Sutton has an article with an illustration showing a Fallopian tube bound to the top of the fundus uteri.

The ovaries, too, may be displaced, so that one tube may almost have a choice of ovaries to get an ovum from. Dr. Rivers Pollock ('Obstet. Trans.,' 1898, p. 120) says, "In both ovaries there was a dermoid tumour; the left ovary was lying over the right in the right iliac fossa, and was fixed there by a piece of omentum."

Dr. Giles's case, already given, showed "both tubes bent backwards behind the uterus, and both ovaries are similarly displaced." We therefore have proof of—

(1) Extra long tubes.

(2) Displaced tubes, either backwards or both over to the same side of uterus, or to the top of the uterus.

(3) Displaced ovaries.

With these evidences I am satisfied that the tubes occasionally grasp the opposite ovary, though I admit none really show a tube doing so, nor will it ever be possible to catch the tube virtually "in the act."

The woman lying on her side, gravity may help the upper tube to cross or fall over to the lower ovary.

* Mr. Doran informs me he removed the whole of the *right* ovary on December 2nd, 1899; that the uterus was *not* pregnant at the time of the operation; that the patient was confined of a *girl* in December, 1900, having thus only the *left* ovary in her abdomen.

Dr. J. R. Ratcliffe reports a case ('Obst. Trans.,' 1892, p. 469, etc.) of pregnant uterus bicornis. "The *left* horn contained the fœtus. The *right* ovary (that on the opposite side to the pregnant horn) showed a true corpus luteum; none in the *left* ovary. The cervix was short and broad, only a quarter of an inch deep." The sex of fœtus, which was between the second and third month of gestation, is not given.

The committee appointed to report on this specimen say, "The ovum from the right ovary may have been washed up the left cornu just as it left the right cornu immediately above the os externum, but from the shallowness of the os this seems hardly probable."

Why this shallow cervix, which was a quarter of an inch deep, should be an obstacle to an ovum of at most one hundredth of an inch diameter I cannot understand; but, of course, the most probable explanation is that the tube of the left or pregnant side grasped the right or ovum-yielding ovary.

The child, I maintain, would have been a male.

Briefly, then, there are two theories to explain these cases where pregnancy occurs on the opposite side to the corpus luteum, viz. the transmigration of ova, and the grasping of an ovum from the opposite ovary by the tube of the pregnant side.* Probably cases of both occur; but probably the transmigration of ova is the least likely, or at all events least often occurs.

I have certainly not discovered anything to prove that either is impossible. The possibility of both, and the probability of at least one of the theories, strengthens my attempt to explain the causation of sex.

I have not been able to discover a single case of, say, female fœtus in left tube and corpus luteum in right ovary; if there is a female fœtus in the left tube, then I say the

* Dr. Galabin ('Manual of Midwifery,' 1900) supports the trans-peritoneal migration of the ovum, which avoids the necessity of movement on the part of the tube towards the opposite side.

corpus luteum must be in the left ovary. If the corpus is in the right ovary, and there is a fœtus in the opposite or left tube, it must, I say, be a male, or else not old enough to distinguish the sex; and *vice versâ*, I have not found a male fœtus in the right tube and a corpus in the left ovary, for a left corpus means a female child, while a fœtus in the right tube may be male or female according to which ovary supplied the ovum, but if a *male* the corpus must be in the *right* ovary.

If such a case were found, then both ovaries must have contained corpora lutea, one of which had been overlooked, the second fœtus having been shed as a mole, either uterine or tubal; in fact, it would have been a twin gestation.

In a case quoted by Bernutz and Goupil (p. 244) from Duverney, the post-mortem showed "rupture of *left* Fallopian tube, which *contained a fœtus* and placenta; I also found that the uterus contained a placenta alone, the cord of which was broken, showing the *fœtus had been expelled.*"

"On examining the left tube I found the obstruction which had prevented the ovum passing on to the uterus."

Unfortunately no corpora lutea are mentioned, but I feel confident that one would have been found in each ovary; neither is sex of tubal fœtus given.

The case is a twin gestation, one extra- the other intra-uterine.

While having thus looked upon the presence of a true corpus luteum as direct evidence of pregnancy, it is well to point out that a large corpus luteum has been found in a few cases where no pregnancy existed, but a large fibroid of the uterus has then usually been present.

Two such cases are mentioned by Bland-Sutton in his 'Surgical Diseases of Ovaries' (1891), p. 15; and he further mentions that a Dr. Popow, in 'Obst. Trans.,' vol. xxiv, p. 100, narrates two others, in one of which at least there was a fibroid present.

I have not seen the paper, but we must not forget

that a tubal pregnancy or mole may have been overlooked by Dr. Popow. Dr. Herman ('Obst. Trans.,' 1892, p. 10) says he too has seen a large corpus luteum in an ovary without pregnancy, but a uterine fibroid was present.

It will thus be seen that the instances are very few, and they may probably be explained thus, that the fibroids present in the uterus may have acted reflexly on the ovary, and thus caused the corpus luteum of menstruation to assume at all events the size, if not the characteristics, of a corpus luteum of pregnancy, the irritation of the fibroid acting in a somewhat similar manner to what a fœtus usually does.

It is therefore shown that what few cases of corpora lutea, apart from pregnancy, have occurred, can be explained by the presence of a different irritating body, viz. a fibroid; so that I may conclude with the following quotation from Parry, mentioned by Bland-Sutton (p. 14): "The presence (of the corpus luteum in pregnancy) is the rule, its absence is the exception, especially in the early months of gestation."

Having thus considered the cases of single births, I now consider the applicability of my theory of sex to cases of twin births.

Twins.—As regards the origin of twins, there are four ways in which they arise. Sexes opposite. Two G. Fs.* from two ovaries.

Variety "A."—The commonest has already been mentioned. It is where each ovary matures a Graafian follicle at or about the same time, so that we get one G. F. with an ovum from *each* ovary; therefore the fœtuses are of opposite sexes, one male, one female. Playfair (vol. i, p. 184, edit. 5) says, "In the largest number of cases of twins the children are of opposite sexes;" this I look upon as cause and effect.

Variety "B."—Sexes similar. Two G. Fs. with one ovum *each*, from *either* ovary. In these cases, which are

* G. F. = Graafian follicle.

not so common, we find (instead of Variety "A," each ovary supplying an ovum) one ovary alone will supply two Graafian follicles, so that two ova are derived from the same ovary, and therefore the twins are the same in sex, either two males or two females, according to which ovary the ova came from. Playfair (p. 184) says "The most common cause of multiple pregnancy is probably the nearly simultaneous maturation and rupture of two G. Fs., the ovules being impregnated at or about the same time;" this therefore applies to both the above varieties.

The negress who has both a black and white child comes under the above two varieties.

'New Sydenham Society Year Book,' 1862, p. 339, quotes the following:

"*Tufnell's case.*—Patient pregnant between three and four months. *Post-mortem.*—There was a rent in *right* Fallopian tube, and a cyst from where the fœtus had escaped. Right Fallopian tube and ovary agglutinated. Fœtus one inch long. The uterus contained a healthy *male* fœtus proportionate to the date of conception. The cystic cavity in the right Fallopian tube contained a solid organised mass like a miniature placenta. There were two distinct corpora lutea in the right ovary."

This case proves a twin male pregnancy, with both ova coming from different Graafian follicles, but from the same ovary, the right. Hence the same sex, and that male.

Variety "C."—Sexes similar. One G. F. with two ova from either ovary.

Other cases of twins arise when the single G. F. ruptured by either ovary contains two ova; here the twins will be of the same sex, and will depend on the supplying ovary. Playfair (i, 185)—"it may happen that a single Graafian follicle contains more than one ovule, as has actually been observed before its rupture." See also Lusk's 'Midwifery,' 1889, p. 37.

Variety "D."—Sexes similar. One G. F. with one

ovum with two germs. If, on the contrary to variety "C," the single G. F. contains a *single* ovum, but that ovum contains a double germ or germinal vesicle (as is common in fowls' eggs), we get the so-called unioval twins, which are stated to be seven times more rare than other forms, and we find them not only *always* alike in sex (which fact Schroeder pointed out long ago), but often joined together. Playfair (p. 186) says "conjoined twins must of necessity arise from a single ovule with a double germ, and there is no instance on record in which they were of opposite sexes." This should, I think, help to prove my theory, by showing that *one ovary always "breeds true."*

Dr. T. Wilson ('Obst. Trans.,' 1899, p. 237) says "there is a much greater predisposition to the occurrence of hydramnion in cases of twins derived from a single ovum than in the commoner variety of twins developed from separate ova."

"The unioval variety of twins is of interest for many reasons. The fœtuses are always of the same sex, and are much more alike than are those developed from different ova. They have a single placenta, in which an anastomosis takes place between their vessels; acardiac monsters are generally admitted to arise only in this variety of pregnancy."

It does not, however, follow that if two follicles rupture, and two ova are discharged, they are sure both to be impregnated; one may easily die. "This is proved by the occurrence of cases in which there are two corpora lutea with only one fœtus" (Playfair, 'The Science and Practice of Midwifery,' vol. i, p. 184).

Triplets.—It will be quite easy to understand how triplets occur from what has been said about twins, and how triplets follow the same rule as to their sex. One ovary gives rise to twins, and the other a single birth. In this case two of the children are alike in sex. If the children are all of the same sex, one or other ovary provided them all, one G. F. providing either two ova, or else

one ovum with a double germ, and the other G. F. supplying a single ovum.

No case has so far been reported of three corpora lutea of pregnancy in one ovary, unless Doran ('Obst. Trans.,' 1893, p. 225) describes one:—"A great part of the interior of the left ovary was occupied by a large corpus luteum of about the second month of pregnancy, also two smaller well-developed corpora lutea" (? menstrual only).

G. W. Thompson ('Indian Medical Journal,' April, 1899) records a case of triplets, a double female monster, and a single male child. "The single male child was born first, was stillborn, and had a separate placenta and membranes. The sex was female of the united fœtus, which had two heads, four arms, and four legs, and two bodies united by the thoraces." This is absolute proof that the female monster came from the ovary opposite to that from which the single male child did.

Quadruplets.—If both ovaries give rise to twins, we get quadruplets; or if one ovary gives triplets and the other a single birth, as in the case by Simpson, three males and one female. Here the right ovary must have ruptured two G. Fs., one of which contained two ova, or else had a double germ in one, while the left ovary supplied a single ovum only.

If all four children are the *same* sex, it is possible only two G. Fs. are present, both G. Fs. containing two ova; or one G. F. with two ova, the other G. F. having one ovum but a double germ. If there were three G. Fs. the arrangement is quite simple.

It is possible for one G. F. to supply quadruplets; the children would be all the same sex. The G. F. would then contain two ova, and each ovum a double germ.

This theory of mine will also account very naturally for those cases with which we are all familiar, where married couples have such strange variations in the sexes of their children. Thus:

Children all the same Sex.

Mr. T. F. had	Mr. S. had	Mr. W. had
5 drs. 0 sons.	7 sons 0 drs.	7 drs. 0 sons.
Mr. G. D. had	Mr. B. had	Mr. H. had
4 sons 0 drs.	8 sons 0 drs.	5 drs. 0 sons.
While Mr. Hll. had	and	Mr. Hrt.
13 drs. 0 sons		4 sons 0 drs.
Last confinement twin girls.		Last confinement twin sons.

In these cases the probability is that the ovary which did *not* supply the ovum which was first fertilised, became, as an after-effect of the confinement, either bound down by adhesions, or the F. tube was thus affected. Hart and Barbour say (p. 159), "It is the rare exception to examine a parous female pelvis without finding some traces of a previous cellulitis or peritonitis;" and on p. 155 (prognosis as to sterility after pelvic peritonitis), "The mechanical closure by pressure, of the F. tube, and ovaritis rendering ovulation impossible, are conditions often produced."

The above, then, are cases where the activity of one ovary is lost, the first fertilised-ovum-supplying ovary being the only one remaining active, and hence all the children are of the same sex.

Such a case as the following would account too for the same sex of children.

At the post-mortem examination of a case dying of malignant disease of the breast, under Mr. Cowell, in Hollond Ward, Westminster Hospital, the report is, "Ada Watson, aged 42, case of undeveloped ovary. Uterus large, subinvoluted; right ovary rudimentary."

Other causes of only one-sexed children being born would be advanced disease of one ovary. Such was the case by Dr. Galabin ('Obstet. Trans.,' 1886, p. 101). Dr. Galabin showed tumours of both ovaries removed at the fourth month of pregnancy. "The *right* tumour was a dermoid cyst containing gruel-like fluid, which

solidified on cooling. It contained also hair, loose teeth, and bone.

"The left tumour was an ordinary cystic adenoma, except that three small cysts in it were evidently dermoid. In the left tumour was seen a large corpus luteum of pregnancy, and near it a small fragment of unaltered ovary."

Unfortunately the sex of the child when ultimately born was not given; but I feel confident it was a girl.

The entire absence or even non-development of one ovary would also account for such cases. To *unilateral* sterility we must ascribe these cases.

The next class of family is where the sex of the first pregnancy differs from those that follow, thus:

Mr. Brdn. had	Mr. Egle had
first a son then 5 drs.	first a dr. then 16 sons.
Mr. My.	Mr. McC. had
first a son then 6 drs.	first a dr. then 6 sons.

Here the ovary which supplied the ovum for the first pregnancy became after *that* pregnancy functionally useless, either from adhesions, or disease in it or its tube, so that in all the subsequent pregnancies the ova came from the other uninjured ovary, and the children were all of the same sex, and different from the first or primary pregnancy.

Here *unilateral* sterility after the first pregnancy is the cause. It would not be difficult to recount cases of matting of appendages causing *unilateral* sterility, but I refrain from doing so.

In the cases like that of the German Empress, where *several sons* are *followed by a daughter*, or these:

Mr. Psy. had seven sons followed by one girl;

Mr. Hwkns. had	Mr. Rssll. had
7 drs. then last pregnancy a son;	11 drs. followed by 1 son at last pregnancy;

Mr. Glg. had nine girls, then *twin girls*, and lastly a son;
Mr. Jdn. had two sons, then *twin sons*, and lastly a girl,

the binding down of the ovary and tube which *did not act* must have been undone by the number of pregnancies, or by the last one, so that the ovary and tube were set free, as it were, once more, and at last were able to act, with a change of sex as a result. That this liberation from adhesions is possible is stated by Hart and Barbour (p. 155) :—"The adhesions (of Fallopian tubes) may ultimately yield to the stretching brought to bear on them by the developing uterus." Note the cases of twins just previously to the change in sex.

The more usual mixture of boys and girls which most people have, goes to prove that the ovaries act, as stated by Négrier, alternately, or at least are both active.

Mr. L— had his children thus—1st boy, 2nd girl, 3 b.,* 4 g.,* 5 g., 6 b., (7 mis.,) 8 b., 9 g., 10 b., 11 b., 12 g. ; this is a typical case of alternate action.

Mr. K— had his children thus—1, 2, 3, 4, 5 boys, 6 and 7 girls, 8 b., 9 g., 10 b., 11 twin boys. While Mr. O— had 1st g., 2nd b., 3 b., 4 g., 5, 6, 7 b., 8 and 9 g., 10 b. ; these are both examples of well-assorted ovarian activity.

The fact that both ovaries act normally alternately, so that the production of either sex is equally liable to occur, is proved by there being no great difference in number between them at birth ; *i. e.* there is a normal numerical relation between the sexes at birth, the proportion being 106 male to 100 female children.

In those cases where the birth of one child is followed by entire cessation of child-bearing, sterility "bilateral," must have followed, and is probably inflammatory in origin. Other causes of absolute sterility need not be referred to here.

The next question which naturally arises is, Does the father or male parent have any influence over the sex of the forthcoming fœtus ? The answer is No, decidedly not.

In the act of insemination the discharge (semen) comes

* b = boy; g = girl.

vid the ejaculatory ducts from both testicles simultaneously, and from the reservoirs (vesiculæ seminales) which hold the secretion from both testicles. The spermatozoa, which thus come from both testicles at once, fertilise the ovum which has come from one or other ovary only, and thus we get the normal single pregnancy. If the spermatozoa meet and fertilise more than one ovum, whether the ova come one from each ovary, or two or more from the same ovary, we get a plural birth, and these are then looked upon as an abnormality of pregnancy.

Playfair ('Science and Practice of Midwifery,' 1884, p. 182) says "plural births must not be classified as natural forms of pregnancy." We are therefore justified in saying that normally the united secretion of the two testicles fertilises the production of one ovary only.

The character and idiosyncrasies of the resulting fœtus may be influenced by the father, but not the sex. This fact which I just point out, that the semen is the united product of both testicles and that this normally fertilises the product of one ovary only, leads up to the other fact, that there are two ovaries and there are also only two sexes; and this is cause and effect, for according to which ovary supplies the ovum, so we get one or the other sex produced. Had there been three ovaries instead of two we should have expected a third sex, but Bland-Sutton ('Dis. of Ovaries,' p. 22, and again 482) tells us "there is no authentic instance on record of a third ovary," neither is there a third sex. The so-called hermaphrodites are *not* a third sex.

That the male parent does not influence the sex of the coming child is proved by such cases as these:

Mrs. A. by her first husband had 2 girls } 0 boys by either.
" " second " 3 " }

Mrs. Mk. by her first husband 3 boys }
" " second " 3 boys } 0 girls by either.

Surely if the husbands settled the sex the above would have had mixed children, instead of only one-sexed

children by two different men ; the wives were unilaterally sterile.

In the following cases the husband of more than one wife gets one-sexed children only from each wife ; but as they differ in the different wives, while the sexual act is the same for each wife, the inference must be that the wife settles the sex.

Mr. G. Y. by his first wife had 3 girls, 0 boys.
,, ,, second ,, 3 boys, 0 girls.
,, ,, third ,, 1 boy, 0 girls.

Mr. L. by his first wife had 3 boys, 0 girls ; then he married a widow who already had one girl by her first husband ; by the widow, his second wife, he had 3 girls, 0 boys.

In these cases the fathers produced both-sexed children with *different* wives, but only *one* sex with *each* wife,—*i. e.* the father did not influence the sex ; the women were "unilaterally" sterile.

In the following cases the man gets both-sexed children with one of his wives, but only one sex with the other, because she is "unilaterally" sterile ; if it depended on the male he should get both-sexed children with both wives.

Mr. Mll. by his first wife had 4 girls, 0 boys ; by his second wife had first, a girl ; second, a boy ; third, a girl.

Mr. C. by his first wife had 2 boys, 7 girls.
,, ,, second ,, 4 boys, 0 girls.

I have shortly and finally to consider how the origin of hermaphroditism affects my theory.

Firstly, then, true hermaphroditism is extremely rare ; very few if any cases have occurred where both ovaries and testicles have been active in one and the same individual. Sutton ('Dis. of Ovaries,' p. 5) says, "No case has yet been recorded of a functional ovary co-existing with a functional testis."

Dr. G. F. Blacker ('Obstet. Trans.,' 1896, p. 265, etc.) has a most elaborate paper on the subject. He admits with Sutton that if both forms of glands be present, they are not both functionally active. He proves (p. 307)

that certainly not more than seven cases of true hermaphroditism have so far been shown worthy of any belief.* Most cases of so-called hermaphroditism are false or pseudo-hermaphrodites, the external genitals only being abnormal. The clitoris is hypertrophied, the ovaries herniated, or the scrotum split or absent; but there is only one set of genital glands.

In these few possible cases of hermaphroditism the added gland is, we have seen, inert and functionless. Dr. Blacker says, "If functional activity for the two kinds of glands is insisted upon, it is most unlikely that any case of true hermaphroditism will ever be met with in man."

We must therefore look upon the origin of these cases as a developmental one, arising subsequently to the second month of intra-uterine life.

That the clitoris should hypertrophy, or the uterus masculinus should abnormally develop, are facts, but why they should do so, and thus resemble their homologues, it is impossible to say or prove; but their very infrequency and their abnormality cannot be held to in any way disprove this theory of normal sex causation. It is only abnormal growth, the same as three thumbs in a man, a webbed-toed girl, or a one-eyed idiot.

Concerning my claim of originality for this sex theory, it is well to point out that—

This theory was thought out by me in 1887, and facts in support of it have been gradually accumulated.

I have a card from Dr. H. Briggs, of Liverpool, dated November 18th, 1887, in my possession, besides two private letters, dated September 1st, 1888, from Dr. Cullingworth; and October 2nd, 1888, from Dr. A. Pocock, in answer to my queries as to cases I thought would support my theory, which shows when I began work on the subject.

It was not till four years after I started work on this theory, viz. on the publication in 1891 by Dr. Neale of

* These have still further been reduced in number by Dr. Ballantyne in Allbutt and Playfair's 'System of Gynæcology.'

his 'Medical Digest,' that I therein found that two medical men had broached the idea that the ovaries had "something to do with the sex."

However, so incomplete were their observations that no text-book has (as far as I can discover) ever adopted or even mentioned the idea, and only the 'Digest' has saved their ideas from being for ever lost.

In the first case, Dr. Thos. F. Tuckey, of Castletownroche, County Cork, Ireland, has a short paper in the 'Practitioner' (vol. ii, 1878, p. 412)—"Further remarks on the Relation of the Ovaries to the Sex of the Child," in continuation of a paper in March, 1878, in the 'Medical Press and Circular.'

He endeavours from the site of the placenta in the uterus, especially in fifteen cases, to prophesy the sex of the child; saying that "if the placenta is situated on the left of the uterine mid-line it was a female; if to the right of the mid-line a male."

He then says, "I do not yet know whether my idea that the right ovary is intended for the production of males, and the left for that of females, has been thought worthy of proof, or the reverse; but I know, to my mind and experience, the arguments that such is the case are growing stronger every day."

"Believing, as I do, that there is a close relation between the position of the placenta and the sex of the child, and consequently between the sex of the child and the ovaries, I am very anxious to get further proofs of the matter."

I cannot find that Dr. Tuckey ever wrote anything further on the subject, and it only seems to have occurred as an idea, for no proof was brought forward by him. The theory here mooted was certainly never adopted by the profession.

In the second case, Dr. Hamilton ('Lancet,' vol. i, 1848, p. 191) says, "May not the particular ovary have something to do with the sex?"

He advances no definite theory, gives no proof what-

ever, and which ovary produces which sex is not suggested.

I therefore think, having certainly started this theory quite independently, and in ignorance of the writings of Drs. Tuckey and Hamilton, who did not dissociate the male or father from the causation of sex, that I am justified in claiming originality for it, as I undoubtedly am for the methods adopted to prove it.

That there is at present no accepted theory is borne out by the 'British Medical Journal' of December 1st, 1900, p. 1623, which says, "There is not, so far as we can ascertain, any accepted view of the causation of the sex of offspring."

NOTE.—Since the paper was written, Dr. Routh has kindly sent me the following interesting case. Mrs. Stanley Boyd entirely removed the *right* ovary from a patient, and a portion only, for early cystic disease, of the *left* ovary; a healthy portion of the latter being allowed to remain in the abdomen. The patient *subsequently* became pregnant, and was delivered of a *girl*.

The PRESIDENT remarked that discussions on sex problems had been popular from time immemorial, but however interesting they might be, they seemed ever barren of useful results. Mr. Dawson had taken great pains to collect what must certainly be called clinical evidence, and had thus avoided *a priori* arguments founded on one or two cases of unilateral ovariotomy. Did he seriously believe that where a male heir was a matter of national importance the removal of a queen's left ovary would at least avoid disappointment?

Dr. BLACKER thought the subject was one of great interest, and that the Society was indebted to Mr. Dawson for bringing the matter before them. He was surprised to see that this theory was called a new one. He had imagined that it was one of some antiquity. It was quite certain that Galen taught that the warmer right side of the body produced males, and the colder left side of the body females, and as far back as 500 B.C. Anaxagoras taught the same thing as that of Mr. Dawson. In the ninth century Rhazes, the earliest Arabian writer on obstetrics, also taught it, and since his time it had been put forward by many writers, only in the majority of

instances to be condemned as untenable. In 1816 Millot, a French physician, published a very interesting little book, in which he not only propounded this theory in detail, but also gave minute instructions as to how fertilisation of ova from the right or left ovary respectively could be effected at the will of the parents, and so children of whichever sex desired obtained. A theory which dated back to 500 B.C. could hardly be termed new. If any such theory was to be accepted, we must admit, firstly, that the male parent plays no part in the causation of sex; and secondly, that the sex of the ovum was determined at the time of its expulsion from the ovary, and could not be influenced either by fertilisation, or by any changes occurring subsequently to this. The large number of observations collected by various writers upon the subject, and the numerous experiments carried out upon animals, seemed to prove beyond doubt that the male parent did play some part, and the evidence to be obtained from the lower animals, especially bees and tadpoles, showed that by changes in nutrition the sex could be influenced, even after fertilisation had taken place. Jung had succeeded by feeding young tadpoles upon beef or frog's flesh, in raising the percentage of females from 57 per cent. to 92 per cent., a very evident proof of the great influence of nutrition. It was, of course, absurd to argue from the tadpole to man, but it was quite permissible to compare the human embryo with the tadpole embryo. Sutton holds, and he is no doubt right, that the early condition of the sexual organs in man is one of embryonic hermaphroditism, and that the development of nonsexuality depends upon the preponderant growth of one set of organs over the other. If this be so, then the fact that changes in nutrition can influence the development of sex is not a matter for surprise. Any theory of sex put forward for acceptance must explain certain well-ascertained facts with regard to the relative proportions of the sexes, viz. the preponderance of male births in Europe; the excess of female births amongst Mulattoes, hybrids, and polygamous animals; and the general equality of the sexes amongst animals as a whole. Mr. Dawson's theory did not and could not explain any of these, with the possible exception of the last. Not only was he not prepared to accept the author's conclusions, but he could not accept as sufficient the data upon which they were based. Certainly the cases of extra-uterine gestation Mr. Dawson had instanced were of a striking character; but if a theory of this kind was to be supported by statistics, the numbers must be of sufficiently large dimensions to eliminate all possibilities of error. Mr. Dawson's figures were not of such dimensions. He felt sure that many of the Fellows of the Society could instance cases of unilateral ovariotomy and subsequent pregnancy which would not bear out the conclusions arrived at in this paper. He personally could

recall two such cases. The first was that of a patient who had had the right ovary removed and had subsequently given birth to two boys, and the second that of a patient who had had the left ovary removed twelve years ago, and had since given birth to one boy and three girls. No doubt they would ultimately be able to explain the exact causation of sex; but when that time came he felt sure that the cause would be found to lie not in any one theory, or in any one factor, but in a number of factors interacting under varying conditions. Any theory of sex to be accepted must apply to the whole of the vertebrata. Birds as a class had only one ovary. The common fowl, for example, had only one, the left ovary, and it was only amongst a few of the diurnal birds of prey that any rudiments of the right ovary could be found in the adult animal. In view of this fact, would Mr. Dawson explain where, according to his theory, cocks came from?

Dr. Herbert Spencer said the paper was supported by what appeared at first sight to be an imposing array of facts, and contained some statements of opinion which were not facts. It was a pity that more inquiry had not been made as to the sex of the children born after unilateral ovariotomy. He had himself removed a left-sided ovarian tumour completely, and the patient had in a subsequent pregnancy borne twins of different sexes. There was no doubt whatever that the tumour had been completely removed. Cases of this kind absolutely disproved the theory of the author.

Mr. Dawson, in reply, having thanked the President and Fellows for their kind reception of his paper, stated, in answer to Dr. Inglis Parsons, that the removal by operation of the tube of one side, and of the ovary of the opposite side, did not prevent pregnancy. Apart from the possibility of the remaining tube grasping or receiving an ovum from the opposite or remaining ovary, we had the statement in Dr. Galabin's 'Manual of Midwifery,' 1900, that there was a transperitoneal or extra-uterine migration of the ovum, *i. e.* without any necessity for tubal movement. He denied, in answer to Dr. Blacker, that the male parent had anything to do with the causation of sex, and in this particular his theory differed from those old and mythical theories quoted by Dr. Blacker as evidence that the author's theory was not original. The authors of these old theories believed that each testicle contained special spermatozoa, which were only able to fertilise the special ova in their own corresponding ovary. Galen assumed that the right side of the body was warmer than the left, and that the warmer side produced males, but no proof was forthcoming. The cases given in the paper serve to show that the father does not influence the sex of the offspring, without descending to seek instances among mammals. He did not, to prove his theory,

go for facts to bees or tadpoles, water-fleas, trout, or plants, and from them attempt to argue that the same conditions are applicable in the human species. He must refuse to associate tadpoles with women, or to look upon the human ovum which was capable of developing a human brain as comparable to a frog's egg. Neither could the author agree that the case narrated by Dr. Blacker, where he removed the right ovary (two boys being afterwards born), disproved the theory; for no single case could be held to disprove a theory, any more than the absence of one breast in a woman disproved the normality of bilateral mammæ in women, or tubal pregnancies disproved the uterus as the normal site of gestation. The fact, recorded by Mr. Bland-Sutton, that three different abdominal sections, by three different experienced operators, were required to successfully remove both ovaries in a woman, in order to stop menstruation, showed how very easy it was for a portion of an ovary to be left behind, and thus give rise to a pregnancy with the fœtus corresponding in sex to the ovary thought to be removed. In this manner, too, he explained Dr. Spencer's case of "pigeon-pair" twin pregnancy occurring after the removal of the left ovary, which was stated to be bound down by adhesions. Mr. Dawson had narrated in his paper the case of pregnancy occurring twice after so-called removal of both ovaries. Both the children were the same sex, male, because an ovary always "breeds true." A piece of one ovary had evidently not been removed; he maintained it was a portion of the right ovary, hence the sex of the children was male.

INDEX.

PAGE

Abdomen, macerated fœtus removed two months after spurious labour from the cavity of (Alban Doran) . . 8

Abdominal section, and removal of sac in a full-term pregnancy in a rudimentary horn of uterus; missed labour (five months) (J. H. Targett) 276

—— for removal of suppurating ovarian cyst which had obstructed labour (W. W. H. Tate) . . . 164

—— in a case of extra-uterine gestation in which fœtal death occurred at the eighth month after spurious labour, (A. Doran) 213

—— performed after four or five months in a case of extra-uterine gestation in which fœtal death occurred at term after spurious labour (John Phillips) . . . 121

—— Porro-Cæsarean hysterectomy with retro-peritoneal treatment of the stump in a case of fibroids obstructing labour; with remarks upon the relative advantages of the modern Porro operation over the Sänger-Cæsarean in most other cases requiring (A. Routh) . . 244

Abortion, tubal, in which the "mole" was in process of extrusion at the time of operation (J. Bland-Sutton) . 311

Acardiac acephalic fœtus, see *Monsters*.

ADDINSELL (Augustus W.), solid tumour of the ovary removed from a woman aged thirty-six (shown) . . 139

Address (Annual) of the President, Alban Doran, F.R.C.S., February 7th, 1900 43

Adenoma of the uterus (T. W. Eden) . . . 2

Anasarca and large placenta in a fœtus (R. Boxall) . . 98

Anatomy and nature of two acardiac acephalic fœtuses (A. Keith) 99

PAGE

ANDREWS (E. Collingwood), *Remarks* in discussion on Amand Routh's paper on Porro-Cæsarean hysterectomy with retro-peritoneal treatment of the stump, in a case of fibroids obstructing labour . . . 261

ANDREWS (H. R.), imperforate rectum and congenital prolapse of the uterus (shown) 169

—— *Report* of Committee 266

—— rudimentary supernumerary digits (shown) . . 266

—— sarcoma of the uterus, with a microscopic section (shown) 210

Aneurysm of the splenic artery, fœtal rupture of, immediately after labour (J. D. S. Nodes and Frank Hinds) . 305

BLACK (James Watt), *Report* as Treasurer for 1899 . 38

BLACKER (G. F.), frozen sections of a uterus at the tenth week of pregnancy, showing hæmorrhages into the placenta, decidua reflexa, and decidua vera, from a patient who died of heart disease 235

—— spinal column exhibiting want of ossification in the inter-articular portion of the lumbar vertebræ (shown) . 90

—— *Remarks* in discussion on T. Wilson's paper on the relations of organic affections of the heart to fibro-myoma of the uterus 208

—— —— in discussion on E. R. Dawson's paper on the essential factor in the causation of sex; a new theory of sex 394

BLAND-SUTTON (John), tubal abortion in which the "mole" was in process of extrusion at the time of operation (shown) 311

—— *Remarks* in reply 315

—— —— in discussion on E. O. Croft's paper on an anomalous case of ectopic pregnancy, probably ovarian, and A. H. N. Lewers's paper on a case of repeated ectopic gestation in the same patient; laparotomy on each occasion 330

BOULTON (Percy), *Report* as Chairman of the Board for the Examination of Midwives for 1899 . . . 39

BOXALL (Robert), fœtus with anasarca and large placenta (shown) 98

—— *Remarks* in discussion on J. M. Munro Kerr's paper on three cases of incarceration of the retro-displaced gravid uterus, and one of extra-uterine pregnancy simulating that condition 157

PAGE

Boxall (Robert), *Remarks* in discussion on A. Doran's paper on a case of extra-uterine gestation in which fœtal death occurred at the eighth month after spurious labour; abdominal section two months later . . 233

—— —— in discussion on H. R. Spencer's specimen of two cases of parovarian cyst with twisted pedicle, in which the ovary only (and not the cyst) was congested and inflamed 337

—— —— in discussion on W. J. Sinclair's paper on the diagnosis and treatment of retroflexio-versio uteri gravidi 355

Butler-Smythe (A. C.), *Remarks* in discussion on J. M. Munro Kerr's paper on three cases of incarceration of the retro-displaced gravid uterus, and one of extra-uterine pregnancy simulating that condition . . 158

—— —— in discussion on W. W. H. Tate's specimen of large fibro-myoma of the cervix removed by enucleation, followed by vaginal hysterectomy . . . 164

—— —— in discussion on P. Horrocks's specimen of fibroid tumours of the uterus with great distension of the Fallopian tubes from tubercle . . . 167

—— —— in discussion on A. Doran's paper on a case of extra-uterine gestation in which fœtal death occurred at the eighth month after spurious labour; abdominal section two months later 231

—— —— in discussion on Amand Routh's paper on Porro-Cæsarean hysterectomy with retro-peritoneal treatment of the stump in a case of fibroids obstructing labour . 262

Cæsarean section, ruptured uterus at term through scar of old (J. H. Targett) 242

Cancer of the cervix associated with an œdematous growth in the fundus (C. Hubert Roberts) . . . 267

—— primary, of the Fallopian tube (Alban Doran) . . 6

Carcinoma of the body of the uterus (J. H. Targett) . 281

—— of ovary, primary solid (W. S. A. Griffith) . . 34

Cast of the uterus (T. W. Eden) 5

Cervix uteri, see *Uterus, Cervix of.*

Chadwick (James R.), election as Honorary Fellow . 40

—— letter acknowledging election as Honorary Fellow . 132

Chorion, myxoma of, not discharged till the seventh month (C. H. Roberts) 168

PAGE

CROFT (E. Octavius), anomalous case of ectopic pregnancy, probably ovarian 316
—— *Remarks* in reply 331
CULLINGWORTH (C. J.), incarcerated fibro-myoma of uterus in an unusually young subject (shown) . . 132
—— and J. S. FAIRBAIRN, large inflamed cyst (? ovarian) communicating with an inflamed Fallopian tube (shown) 96
—— *Remarks* in discussion on Alban Doran's specimen of macerated fœtus removed from the abdominal cavity two months after spurious labour . . . 8
—— —— in discussion on J. D. Malcolm's specimen of double pyosalpinx in which the tubal sacs communicated . 12
—— —— in discussion on John Phillips's paper on a case of extra-uterine gestation in which fœtal death occurred at term after spurious labour, and abdominal section was performed four to five months later . . 129
—— —— in discussion on A. Doran's specimen of tubal mole 139
—— —— in discussion on P. Horrocks's specimen of fibroid tumours of the uterus with great distension of the Fallopian tubes from tubercle 167
—— —— in discussion on A. Doran's paper on a case of extra-uterine gestation in which fœtal death occurred at the eighth month after spurious labour; abdominal section two months later 231
Cyst, dermoid ovarian, the size of a child's head in a case of ruptured uterus (A. H. N. Lewers) . . . 95
—— multilocular, of oöphoron (Cuthbert Lockyer) . . 37
—— (? ovarian) communicating with an inflamed Fallopian tube (C. J. Cullingworth and J. S. Fairbairn) . . 96
—— suppurating ovarian, obstructing labour. removed by abdominal section eighteen months later (W. W. H. Tate) 164
Cystoma, ovarian, complicating pregnancy; infection of the cyst five days after labour; operation on the forty-third day; extensive peritoneal and bowel adhesions; recovery (H. Macnaughton-Jones) 140

DAKIN (W. R.), *Remarks* in discussion on Amand Routh's paper on Porro-Cæsarean hysterectomy with retro-peritoneal treatment of the stump in a case of fibroids obstructing labour 259

PAGE

DAWSON (E. Rumley), the essential factor in the causation of sex: a new theory of sex 356
—— *Remarks* in reply 396
Decidua reflexa and decidua vera from a patient who died of heart disease, frozen sections of a uterus at the tenth week of pregnancy, showing hæmorrhages into the (G. F. Blacker) 235
Degeneration, myxomatous and cystic, in a pedunculated subserous fibro-myoma of uterus (A. F. Stabb) . . 133
Dermoid cyst, see *Cyst.*
Diagnosis and treatment of retroflexio-versio uteri gravidi (W. J. Sinclair) 338
Digits, rudimentary supernumerary (H. Russell Andrews) . 266
DORAN (Alban), *Annual Address* as President . . 43
—— extra-uterine gestation in which fœtal death occurred at the eighth month after spurious labour; abdominal section two months later 213
—— *Remarks* in reply 233
—— for *Prof. Pawlik*, photographs from a case of primary cancer of the Fallopian tube . . . 6
—— macerated fœtus removed from the abdominal cavity two months after spurious labour (shown) . . 8
—— *Remarks* in reply 9
—— tubal mole; fœtus three quarters of an inch in length, in perfect preservation 134
—— *Remarks* in reply 139
—— —— in discussion on T. W. Eden's specimen of adenoma of the uterus 3
—— —— in discussion on T. W. Eden's specimen of cast of the uterus 6
—— —— in discussion on J. D. Malcolm's specimen of double pyosalpinx in which the tubal sacs communicated . 10
—— —— in discussion on H. R. Spencer's paper on four cases of rupture of the uterus successfully treated by packing the tear *per vaginam* with iodoform gauze . . 24
—— —— on the report on specimen of fœtus thoracopagus, shown by Amand Routh 33
—— —— in discussion on C. Lockyer's specimen of multilocular cyst of the oöphoron 37
—— —— in discussion of A. Keith's paper on the anatomy and nature of two acardiac acephalic fœtuses . . 119

PAGE

DORAN (Alban), *Remarks* in discussion on John Phillips's paper on a case of extra-uterine gestation in which fœtal death occurred at term after spurious labour, and abdominal section was performed four to five months later . 128

—— —— in discussion on A. F. Stabb's specimen of pedunculated subserous fibro-myoma of uterus which had undergone myxomatous and cystic degeneration . 133

—— —— in discussion on A. W. Addinsell's specimen of solid tumour of the ovary removed from a woman aged 36 . 140

—— —— in discussion on J. M. Munro Kerr's paper on three cases of incarceration of the retro-displaced gravid uterus, and one of extra-uterine pregnancy simulating that condition 155

—— —— in discussion on P. Horrocks's fibroid tumours of the uterus with great distension of the Fallopian tubes from tubercle 166

—— —— in discussion on H. R. Andrews's specimen of imperforate rectum and congenital prolapse of uterus . 172

—— —— in discussion on T. Wilson's paper on the relations of organic affections of the heart to fibro-myoma of the uterus 206

—— —— in discussion on Amand Routh's paper on Porro-Cæsarean hysterectomy with retro-peritoneal treatment of the stump in a case of fibroids obstructing labour . 262

—— —— in discussion on C. Hubert Roberts's short communication on a case of cancer of the cervix associated with an œdematous growth in the fundus . . 273

—— —— in discussion on J. H. Targett's specimen of a full-term pregnancy in a rudimentary horn of uterus: missed labour (five months); abdominal section and removal of sac; recovery 281

—— —— in discussion on A. E. Giles' note on a case of fibro-myoma of the uterus in a patient aged twenty-three, with remarks on enucleation and myomectomy . 304

—— —— in discussion on J. Bland-Sutton's case of tubal abortion in which the "mole" was in process of extrusion at the time of operation . . . 315

—— —— in discussion on E. O. Croft's paper on an anomalous case of ectopic pregnancy, probably ovarian, and A. H. N. Lewers's paper on a case of repeated ectopic gestation in the same patient; laparotomy on each occasion 330

PAGE

Doran (Alban), *Remarks* in discussion on W. J. Sinclair's paper on the diagnosis and treatment of retroflexio-versio uteri gravidi 352
—— —— in discussion on E. R. Dawson's paper on the essential factor in the causation of sex; a new theory of sex 394
Duncan (William), multiple myxomatous polypi from cervix uteri (shown) 243
—— *Remarks* in discussion on Amand Routh's paper on Porro-Cæsarean hysterectomy with retro-peritoneal treatment of the stump in a case of fibroids obstructing labour . 258
—— *Report* of Committee 209

Ectopic gestation, see *Pregnancy, extra-uterine.*
Eden (T. W.), adenoma of the uterus (shown) . . 2
—— cast of the uterus (shown) 5
—— *Report* of Committee . . . 209, 266
Election of Honorary Fellows 40
Election of New Fellows . . . 1, 75, 131, 235, 265, 333
Enucleation for removal of large fibro-myoma of cervix, followed by vaginal hysterectomy (W. W. H. Tate) . 161
—— remarks on, in connection with a case of fibro-myoma of the uterus in a patient aged twenty-three (A. E. Giles) 299
Epithelioma, squamous-celled, invading surrounding tissues like a columnar-celled variety (W. S. A. Griffith) . 210
—— —— of the cervix uteri in a very early stage (W. S. A. Griffith) 210

Fairbairn (J. S.), and C. J. Cullingworth, large inflamed cyst (? ovarian) communicating with an inflamed Fallopian tube (shown) 96
—— *Remarks* on C. J. Cullingworth's and J. S. Fairbairn's specimen of large inflamed cyst (? ovarian) communicating with an inflamed Fallopian tube . . 96
Fallopian tube, primary cancer of (Alban Doran) . . 6
—— with a large inflamed cyst (? ovarian) communicating with an inflamed (C. J. Cullingworth and J. S. Fairbairn) 96
—— double tuberculous pyosalpinx with intercommunication of (A. L. Galabin) 173
—— great distension of, from tubercle in fibroid tumours of the uterus (P. Horrocks) 166
Fellows, see *Lists, Elections.*

PAGE

Fibroid tumours of the uterus with great distension of the Fallopian tubes from tubercle (P. Horrocks) . . 166
Fibroids, see *Tumours* (fibroid).
Fibro-myoma, cystic, of the cervix uteri (C. H. Roberts) . 211
—— large, of cervix, removed by enucleation, followed by vaginal hysterectomy (W. W. H. Tate) . . 161
—— of uterus in a patient aged twenty-three, with remarks on enucleation and myomectomy (A. E. Giles) . 299
—— of uterus, incarcerated, in an unusually young subject (C. J. Cullingworth) 132
—— —— relations of organic affections of the heart to (T. Wilson) 176
Fœtus, death of, at the eighth month after spurious labour, in a case of extra-uterine gestation, abdominal section two months later (A. Doran) . . . 213
—— macerated, removed from the abdominal cavity two months after spurious labour (Alban Doran) . . 8
—— thoracopagus (Amand Routh) . . . 29
—— three quarters of an inch in length, in perfect preservation in specimen of tubal mole (A. Doran) . . 134
—— with anasarca and large placenta (R. Boxall) . . 98
Frozen sections of a uterus at the tenth week of pregnancy showing hæmorrhages into the placenta, decidua reflexa, and decidua vera, from a patient who died of heart disease (G. F. Blacker) 235

Galabin (A. L.), double tuberculous pyosalpinx with intercommunication of the tubes (shown) . . . 173
—— *Remarks* in discussion on W. J. Sinclair's paper on the diagnosis and treatment of retroflexio-versio uteri gravidi 353
—— —— in discussion on Amand Routh's paper on Porro-Cæsarean hysterectomy with retro-peritoneal treatment of the stump in a case of fibroids obstructing labour . 258
—— —— in discussion on W. W. H. Tate's specimen of large fibro-myoma of the cervix removed by enucleation, followed by vaginal hysterectomy . . . 164
Genital organs, two cases of congenital malformation of (H. Macnaughton-Jones) 92
Gestation, extra-uterine, in which fœtal death occurred at the eighth month after spurious labour; abdominal section two months later (A. Doran) . . . 213

PAGE

GILES (Arthur E.), note on a case of fibro-myoma of the uterus in a patient aged twenty-three, with remarks on enucleation and myomectomy . . . 299
—— *Remarks* in reply 305
—— —— in discussion on Amand Routh's specimen of fœtus thoracopagus 30
—— —— in discussion on J. M. Munro Kerr's paper on three cases of incarceration of the retro-displaced gravid uterus, and one of extra-uterine pregnancy simulating that condition 156
—— —— in discussion on H. R. Andrews's specimen of imperforate rectum and congenital prolapse of uterus . 172
GRIFFITH (W. S. A.), primary solid carcinoma of the ovary (shown) 34
—— squamous-celled epithelioma invading surrounding tissues like a columnar-celled variety (shown) . . 210
—— —— —— of the cervix uteri in a very early stage (shown) 210
—— *Remarks* in discussion on C. Hubert Roberts's short communication on a case of cancer of the cervix associated with an adenomatous growth in the fundus . . 274
—— —— in discussion on J. Bland-Sutton's case of tubal abortion, in which the "mole" was in process of extrusion at the time of operation . . . 314

Hæmorrhages into the placenta, decidua reflexa, and decidua vera, from a patient who died of heart disease, frozen sections of a uterus at the tenth week of pregnancy showing (G. F. Blacker) 235
Heart disease, frozen sections of a uterus at the tenth week of pregnancy, showing hæmorrhages into the placenta, decidua reflexa, and decidua vera, from a patient who died of (G. F. Blacker) 234
Heart, relations of organic affections of, to fibro-myoma of the uterus (T. Wilson) 176
HERMAN (G. Ernest), on subcutaneous symphysiotomy . 282
—— *Remarks* in reply 297
—— —— in discussion on H. R. Spencer's paper on four cases of rupture of the uterus successfully treated by packing the tear *per vaginam* with iodoform gauze . 26

PAGE

HERMAN (G. Ernest), *Remarks* in discussion on C. Hubert Roberts's short communication on a case of cancer of the cervix associated with an adenomatous growth in the fundus 274

—— —— in discussion on A. E. Giles's note on a case of fibro-myoma of the uterus in a patient aged twenty-three, with remarks on enucleation and myomectomy . 304

—— —— in discussion on J. Bland-Sutton's case of tubal abortion in which the "mole" was in process of extrusion at the time of operation . . . 314

HINDS (Frank) and John D. S. NODES, fatal rupture of an aneurysm of the splenic artery immediately after labour 305

HORROCKS (Peter), fibroid tumours of the uterus with great distension of the Fallopian tubes from tubercle (fresh specimen shown) 166

—— pregnant uterus and fibroid tumour removed by abdominal hysterectomy (shown) 242

—— *Remarks* in discussion on J. D. Malcolm's specimen of double pyosalpinx in which the tubal sacs communicated 13

—— —— in discussion on H. R. Spencer's paper on four cases of rupture of the uterus successfully treated by packing the tear *per vaginam* with iodoform gauze . 24

—— —— in discussion on J. H. Targett's specimen of ruptured uterus at term through scar of old Cæsarean section; abdominal hysterectomy . . . 243

—— —— in discussion on Amand Routh's paper on Porro-Cæsarean hysterectomy with retro-peritoneal treatment of the stump in a case of fibroids obstructing labour . 259

—— —— in discussion on J. Bland-Sutton's case of tubal abortion in which the "mole" was in process of extrusion at the time of operation . . . 314

—— —— in discussion on E. O. Croft's paper on an anomalous case of ectopic pregnancy, probably ovarian, and A. H. N. Lewers's paper on a case of repeated ectopic gestation in the same patient; laparotomy on each occasion . 330

Hysterectomy, abdominal, pregnant uterus and fibroid tumour removed by (P. Horrocks) 242

—— —— ruptured uterus at term through scar of old Cæsarean section (J. H. Targett) . . . 242

PAGE

Hysterectomy, Porro-Cæsarean, with retro-peritoneal treatment of the stump in a case of fibroids obstructing labour; with remarks upon the relative advantages of the modern Porro operation over the Sänger-Cæsarean in most other cases requiring abdominal section (Amand Routh) 244

—— vaginal, after removal of large fibro-myoma of the cervix by enucleation (W. W. H. Tate) . . . 161

—— uterus with fibroid tumour undergoing mucoid change, successfully removed by abdominal, with intra-peritoneal treatment of the stump (A. H. N. Lewers) . . 94

Imperforate rectum and congenital prolapse of the uterus (H. R. Andrews) 169

Incarceration of the retro-displaced gravid uterus in three cases, and one of extra-uterine pregnancy simulating that condition (J. M. Munro Kerr . . . 146

Infection of the cyst five days after labour in ovarian cystoma complicating pregnancy (H. Macnaughton-Jones) . 140

Keith (Arthur), anatomy and nature of two acardiac acephalic fœtuses 99

Kerr (J. M. Munro), three cases of incarceration of the retro-displaced gravid uterus, and one of extra-uterine pregnancy simulating that condition . . . 146

—— *Remarks* in reply 158

Labour, see *Parturition*.

—— Porro-Cæsarean hysterectomy with retro-peritoneal treatment of the stump in a case of fibroids obstructing, with remarks upon the relative advantages of the modern Porro operation over the Sänger-Cæsarean in most other cases requiring abdominal section (A. Routh) 244

Laparotomy in a case of repeated ectopic gestation in the same patient (A. H. N. Lewers) . . . 324

Lawrence (T. W. P.), redescription of the specimen of spondylolisthesis in the museum of University College . 75

Lea (Arnold W. W.), myxo-sarcoma of the vagina in a child aged two and a half years (shown) . . . 143

Lewers (A. H. N.), repeated ectopic gestation in the same patient; laparotomy on each occasion . . 324

PAGE

LEWERS (A. H. N.), *Remarks* in reply . . . 331
—— ruptured uterus with dermoid ovarian cyst the size of a child's head (shown) 95
—— uterus with fibroid tumour undergoing mucoid change, successfully removed by abdominal hysterectomy with intra-peritoneal treatment of the stump (shown) . 94
—— *Remarks* in discussion on T. W. Eden's specimen of adenoma of the uterus 4
—— —— in discussion on H. R. Spencer's paper on four cases of rupture of the uterus successfully treated by packing the tear *per vaginam* with iodoform gauze . 26
—— —— in discussion on J. M. Munro Kerr's paper on three cases of incarceration of the retro-displaced gravid uterus, and one of extra-uterine pregnancy simulating that condition 156
—— —— in discussion on C. Hubert Roberts's short communication on a case of cancer of the cervix, associated with an adenomatous growth in the fundus . . 274
—— —— in discussion on G. Ernest Herman's paper on subcutaneous symphysiotomy 297
List of Officers elected for 1900 41
—— —— *for* 1901 v
—— *of Standing Committees* vii
—— *of Honorary Local Secretaries* viii
—— *of past Presidents* ix
—— *of Referees of Papers for* 1901 . . . x
—— *of Honorary Fellows* xi
—— *of Ordinary Fellows* xiii
—— *of Deceased Fellows* [with obituary notices, which see] . 54
LOCKYER (Cuthbert), multilocular cyst of the oöphoron (shown) 37

MACLEAN (Ewen J.), *Remarks* in discussion on W. J. Sinclair's paper on the diagnosis and treatment of retro-flexio-versio uteri gravidi 355
MACNAUGHTON-JONES (Henry), ovarian cystoma complicating pregnancy; infection of the cyst five days after labour; operation on the forty-third day; extensive peritoneal and bowel adhesions; recovery (shown) . . 140
—— two cases of congenital malformation of the genital organs (shown) 92

PAGE

MALCOLM (John D.), double pyosalpinx in which the tubal sacs communicated (shown) . . . 10
—— *Remarks* in reply 13
—— —— in discussion on A. Doran's paper on a case of extra-uterine gestation in which fœtal death occurred at the eighth month after spurious labour; abdominal section two months later. 233
Malformation of the genital organs, two cases of congenital (H. Macnaughton-Jones) 92
Missed labour (five months); abdominal section and removal of sac; recovery in a full-term pregnancy in a rudimentary horn of uterus (J. H. Targett) . . 276
Mole, in case of tubal abortion, in process of extrusion at the time of operation (J. Bland-Sutton). . . . 311
Monsters, anatomy and nature of two acardiac acephalic fœtuses (A. Keith) 99
MORRIS (Charles), remarks in discussion on A. W. W. Lea's specimen of myxo-sarcoma of vagina in a child aged two and a half years 144
—— —— in discussion on J. M. Munro Kerr's paper on three cases of incarceration of the retro-displaced gravid uterus, and one of extra-uterine pregnancy simulating that condition 157
Myomectomy, remarks on, in connection with a case of fibromyoma of the uterus in a patient aged twenty-three (A. E. Giles) 299
Myxoma of chorion not discharged till the seventh month (C. H. Roberts) 168
Myxo-sarcoma of vagina in a child aged two and a half years (A. W. W. Lea) 143

NODES (John D. S.) and FRANK HINDS, fatal rupture of an aneurysm of the splenic artery immediately after labour 305

Obituary notices of Deceased Fellows.
Farr, George Frederick, L.R.C.P.Edin., Twickenham . 54
Bright, John Meaburn, M.D.St. And., Forest Hill . 54
Dambrill-Davies, William Richard, M.R.C.S., L.S.A., Alderley Edge 56
Pound, Clement, L.R C.P., Odiham 57
Duncan, James Andrew, M.B., Henrietta Street, W.C. 58
Gibbings, Alfred Thomas, M.D., Dalston . . 58
Tait, Lawson, F.R.C.S., Birmingham . . 59

PAGE

Obituary Notices of Deceased Fellows—continued.
Nesham, Thomas Cargill, M.D., Newcastle-on-Tyne . 71
Johnson, Samuel, M.D., Stoke-upon-Trent . . 71
Ford, James, M.D., Exmouth . . . 72
Oöphoron, multilocular cyst of (Cuthbert Lockyer) . . 37
Ossification, spinal column exhibiting want of, in the inter-articular portion of the lumbar vertebræ (G. F. Blacker) 90
Ovaries, dermoid cyst of, size of a child's head, in case of ruptured uterus (A. H. N. Lewers) . . . 95
Ovary only congested and inflamed in two cases of parovarian cyst with twisted pedicle (H. R. Spencer) . . 333
—— primary solid carcinoma of (W. S. A. Griffith) . . 34
—— solid tumour of, removed from a woman aged thirty-six (A. W. Addinsell). 139

Packing with iodoform gauze in four cases of rupture of the uterus (H. R. Spencer) 14
Parovian cyst with twisted pedicle, two cases of, in which the ovary only (and not the cyst) was congested and inflamed (H. R. Spencer) 333
Parsons (J. Inglis). *Remarks* in discussion on W. J. Sinclair's paper on the diagnosis and treatment of retroflexio-versio uteri gravidi 353
Parturition, fatal rupture of an aneurysm of the splenic artery immediately after (J. D. S. Nodes and Frank Hinds) . 305
—— suppurating ovarian cyst obstructing, removed by abdominal section eighteen months later (W. W. H. Tate) . 164
Pedicle, twisting of, in two cases of parovarian cyst, in which the ovary only (and not the cyst) was congested and inflamed (H. R. Spencer) 333
Phillips (John), extra-uterine gestation in which fœtal death occurred at term after spurious labour and abdominal section was performed four to five months later . 121
—— *Remarks* in reply 129
—— —— in discussion on Alban Doran's specimen of macerated fœtus removed from the abdominal cavity two months after spurious labour . . . 8
Photographs from a case of primary cancer of the Fallopian tube (Alban Doran) 6
Placenta, frozen sections of a uterus at the tenth week of pregnancy, from a patient who died of heart disease showing hæmorrhages into (G. F. Blacker) . . 235

PAGE
Placenta, large, in a fœtus with anasarca (R. Boxall) . 98
Polypus, multiple, myxomatous, from cervix uteri (W. Duncan) 243
Porro-Cæsarean hysterectomy with retro-peritoneal treatment of the stump in a case of fibroids obstructing labour; with remarks upon the relative advantages of the modern Porro operation over the Sänger-Cæsarean in most other cases requiring abdominal section (Amand Routh) 244
Pregnancy, complicated by ovarian cystoma (H. Macnaughton-Jones) 140
—— extra-uterine, anomalous case, probably ovarian (E. Octavius Croft 316
—— —— in which fœtal death occurred at term after spurious labour and abdominal section was performed four to five months later (John Phillips) . . . 121
—— —— repeated, in the same patient; laparotomy on each occasion (A. H. N. Lewers) . . . 324
—— —— simulating a retro-flexed gravid uterus (J. M. Munro Kerr) 146
—— frozen sections of a uterus at the tenth week of, showing hæmorrhages into the placenta, decidua reflexa, and decidua vera, from a patient who died of heart disease (G. F. Blacker) 235
—— full-term, in a rudimentary horn of uterus; missed labour (five months); abdominal section and removal of sac; recovery (J. H. Targett) 276
Priestley (Sir William Overend), election as Honorary Fellow 40
—— letter acknowledging election as Honorary Fellow . 131
Prolapse of uterus, congenital and imperforate rectum (H. R. Andrews) 169
Pyosalpinx, double, in which the tubal sacs communicated (John D. Malcolm) 10
—— —— tuberculous, with intercommunication of the tubes (A. L. Galabin) 173

Rectum, imperforate, and congenital prolapse of the uterus (H. R. Andrews) 169
Relations of organic affections of the heart to fibro-myoma of the uterus (T. Wilson) 176
Report (audited) of the Treasurer for 1899 . . . 38
—— *of the Honorary Librarian for* 1899 . . . 39

PAGE

Report of the Chairman of the Board for the Examination of Midwives 39
—— *of Committee on specimen of myxo-fibroma (? sarcoma) of uterus, shown by A. F. Stabb on April 4th*, 1900 . 209
—— *of Committee on specimen of sarcoma of uterus, shown by H. R. Andrews on June 6th*, 1900 . . . 265
—— *on specimen of fœtus thoracopagus, shown by Amand Routh* 31
Roberts (C. Hubert), cancer of the cervix associated with an adenomatous growth in the fundus . . . 267
—— *Remarks* in reply 275
—— cystic fibro-myoma of the cervix uteri . . . 211
—— myxoma of chorion not discharged till the seventh month (shown) 168
—— *Remarks* in discussion on T. W. Eden's specimen of cast of the uterus 6
—— —— in discussion on Alban Doran's specimen of macerated fœtus removed from the abdominal cavity two months after spurious labour . . . 9
—— —— on the report on specimen of fœtus thoracopagus, shown by Amand Routh 33
—— —— in discussion on A. W. W. Lea's specimen of myxo-sarcoma of vagina in a child aged two and a half years 145
—— —— in discussion on J. M. Munro Kerr's paper on three cases of incarceration of the retro-displaced gravid uterus, and one of extra-uterine pregnancy simulating that condition 157
Robinson (G. H. Drummond), *Remarks* in discussion on H. R. Spencer's paper on four cases of rupture of the uterus successfully treated by packing the tear *per vaginam* with iodoform gauze 27
—— —— in discussion on W. J. Sinclair's paper on the diagnosis and treatment of retroflexio-versio uteri gravidi 354
—— *Report* of Committee 209
Routh (Amand), fœtus thoracopagus (shown) . . 29
—— Porro-Cæsarean hysterectomy with retro-peritoneal treatment of the stump in a case of fibroids obstructing labour; with remarks upon the relative advantages of the modern Porro operation over the Sänger-Cæsarean in most other cases requiring abdominal section . 244
—— *Remarks* in reply 263

PAGE

ROUTH (Amand), *Report* on specimen of fœtus thoracopagus . 32
—— —— as Honorary Librarian for 1899 . . . 39
—— *Remarks* in discussion on T. W. Eden's specimen of adenoma of the uterus 4
—— —— in discussion on J. M. Munro Kerr's paper on three cases of incarceration of the retro-displaced gravid uterus, and one of extra-uterine pregnancy simulating that condition 158
—— —— in discussion on T. Wilson's paper on the relations of organic affections of the heart to fibro-myoma of the uterus 207
—— —— in discussion on C. Hubert Roberts's short communication on a case of cancer of the cervix, associated with an adenomatous growth in the fundus . . 274
—— —— in discussion on J. Bland-Sutton's case of tubal abortion, in which the "mole" was in process of extrusion at the time of operation . . . 315
Rupture of the uterus, four cases successfully treated by packing the tear *per vaginam* with iodoform gauze (H. R. Spencer) 14

Sacs, double pyosalpinx in which the tubal sacs communicated (J. D. Malcolm) 10
Sänger-Cæsarean section, relative advantages of the modern Porro operation in most cases requiring abdominal section over (A. Routh) 244
Sarcoma of the uterus, with a microscopic section (H. R. Andrews) 210
Sex, the essential factor in the causation of: a new theory of sex (E. R. Dawson) 356
SHERREN (James), *Remarks* in discussion on H. Russell Andrews's specimen of rudimentary supernumerary digits 267
SINCLAIR (W. Japp), contribution to the diagnosis and treatment of retroflexio-versio uteri gravidi . . 338
SMITH (Heywood), *Remarks* in discussion on W. W. H. Tate's specimen of large fibro-myoma of the cervix removed by enucleation, followed by vaginal hysterectomy . 163
—— —— in discussion on T. Wilson's paper on the relations of organic affections of the heart to fibro-myoma of the uterus 208

PAGE

SMITH (Heywood), *Remarks* in discussion on E. O. Croft's paper on an anomalous case of ectopic pregnancy, probably ovarian, and A. H. N. Lewers's paper on a case of repeated ectopic gestation in the same patient; laparotomy on each occasion 330

SPENCER (Herbert R.), four cases of rupture of the uterus successfully treated by packing the tear *per vaginam* with iodoform gauze 14

—— *Remarks* in reply 27

—— two cases of parovarian cyst with twisted pedicle, in which the ovary only (and not the cyst) was congested and inflamed (shown) 333

—— *Remarks* in reply 337

—— —— in discussion on T. W. Eden's specimen of adenoma of the uterus 4

—— —— in discussion on A. H. N. Lewers's specimen of ruptured uterus with dermoid ovarian cyst . . 95

—— —— in discussion on H. Macnaughton-Jones's specimen of an ovarian cystoma complicating pregnancy . 143

—— —— in discussion on J. M. Munro Kerr's paper on three cases of incarceration of the retro-displaced gravid uterus, and one of extra-uterine pregnancy simulating that condition 158

—— —— in discussion on W. W. H. Tate's specimen of large fibro-myoma of the cervix removed by enucleation, followed by vaginal hysterectomy . . 163

—— —— in discussion on T. Wilson's paper on the relations of organic affections of the heart to fibro-myoma of the uterus 207

—— —— in discussion on Amand Routh's paper on Porro-Cæsarean hysterectomy with retro-peritoneal treatment of the stump in a case of fibroids obstructing labour . 261

—— *Report* of Committee 266

—— *Remarks* in discussion on C. Hubert Roberts's short communication on a case of cancer of the cervix associated with an adenomatous growth in the fundus. . . 274

—— —— in discussion on A. E. Giles's note on a case of fibro-myoma of the uterus in a patient aged twenty-three, with remarks on enucleation and myomectomy . 304

—— —— in discussion on G. Ernest Herman's paper on subcutaneous symphysiotomy 297

PAGE

SPENCER (H. R.), *Remarks* in discussion on W. J. Sinclair's paper on the diagnosis and treatment of retroflexio-versio uteri gravidi 354

—— —— in discussion on E. R. Dawson's paper on the essential factor in the causation of sex; a new theory of sex 396

Spinal column exhibiting want of ossification in the inter-articular portion of the lumbar vertebræ (G. F. Blacker) 90

Spleen, fatal rupture of an aneurysm of the artery of, immediately after labour (J. D. S. Nodes and Frank Hinds) . 305

Spondylolisthesis, redescription of the specimen in the Museum of University College (T. W. P. Lawrence) . 75

Spurious labour, extra-uterine gestation in which fœtal death occurred at the eighth month after, abdominal section two months later (A. Doran) 213

—— —— —— occurred at term after, and in which abdominal section was performed four to five months later (John Phillips) 121

—— —— macerated fœtus removed from the abdominal cavity two months after (Alban Doran) . . . 8

STABB (Arthur F.), pedunculated subserous fibro-myoma of uterus which had undergone myxomatous and cystic degeneration (shown) 133

—— *Report* of Committee 209

Symphysiotomy, subcutaneous (G. Ernest Herman) . . 282

TARGETT (J. H.), carcinoma of the body of the uterus (shown) 281

—— full-term pregnancy in a rudimentary horn of uterus; missed labour (five months); abdominal section and removal of sac; recovery (shown) . . . 276

—— ruptured uterus at term through scar of old Cæsarean section; abdominal hysterectomy (shown) . . 242

—— *Remarks* in discussion on Amand Routh's paper on Porro-Cæsarean hysterectomy with retro-peritoneal treatment of the stump, in a case of fibroids obstructing labour 262

—— —— on H. Russell Andrews's specimen of rudimentary supernumerary digits 267

TATE (Walter W. H.), large fibro-myoma of the cervix removed by enucleation, followed by vaginal hysterectomy (shown) 161

—— suppurating ovarian cyst obstructing labour, removed by abdominal section eighteen months later (shown) . 164

PAGE

Tubal mole; fœtus three quarters of an inch in length, in perfect preservation (A. Doran) . . . 134
Tubercle, great distension of the Fallopian tubes from, in fibroid tumours of the uterus (P. Horrocks) . . 166
Tumour, fibroid, and pregnant uterus, removed by abdominal hysterectomy (P. Horrocks) . . . 242
—— solid, of the ovary removed from a women aged thirty-six (A. W. Addinsell) 139
—— uterus with fibroid, undergoing mucoid change, successfully removed by abdominal hysterectomy with intra-peritoneal treatment of the stump (A. H. N. Lewers) . 94
Tumours, adenoma of the uterus (T. W. Eden) . . 2
—— fibroid, obstructing labour in which Porro-Cæsarean hysterectomy with retro-peritoneal treatment of the stump was performed; with remarks upon the relative advantages of the modern Porro operation over the Sänger-Cæsarean in most other cases requiring abdominal section (A. Routh) 244
Twins, conjoined (Amand Routh) . . . 29

Uterus, adenoma of (T. W. Eden) 2
—— cancer of the cervix of, associated with an adenomatous growth in the fundus (C. Hubert Roberts) . . 267
—— carcinoma of the body of (J. H. Targett) . . 281
—— cast of (T. W. Eden) 5
—— cervix of, multiple myxomatous polypi from (W. Duncan) 243
—— congenital prolapse of, and imperforate rectum (H. R. Andrews) 169
—— cystic fibro-myoma of cervix of (C. H. Roberts) . 211
—— diagnosis and treatment of retroflexion of the gravid (W. J. Sinclair) 338
—— fibroid tumours of, with great distension of the Fallopian tubes from tubercle (P. Horrocks) . . 166
—— fibro-myoma of, in a patient aged twenty-three, with remarks on enucleation and myomectomy (A. E. Giles) 299
—— —— relations of organic affections of the heart to (T. Wilson) 176
—— four cases of rupture of, successfully treated by packing the tear *per vaginam* with iodoform gauze (H. R. Spencer) 14

PAGE

Uterus, frozen sections of, at the tenth week of pregnancy, showing hæmorrhages into the placenta, decidua reflexa and decidua vera, from a patient who died of heart disease (G. F. Blacker) 235
—— full-term pregnancy in a rudimentary horn of; missed labour (five months); abdominal section and removal of sac; recovery (J. H. Targett) 276
—— incarcerated fibro-myoma of, in an unusually young subject (C. J. Cullingworth) 132
—— large fibro-myoma of cervix of, removed by enucleation, followed by vaginal hysterectomy (W. W. H. Tate) . 161
—— pedunculated subserous fibro-myoma of, which had undergone myxomatous and cystic degeneration (A. F. Stabb) 133
—— pregnant, and fibroid tumour removed by abdominal hysterectomy (P. Horrocks) 242
—— retro-displaced gravid, three cases of incarceration of (J. M. Munro Kerr) 146
—— ruptured, at term through scar of old Cæsarean section; abdominal hysterectomy (J. H. Targett) . . 242
—— —— with dermoid ovarian cyst the size of a child's head (A. H. N. Lewers) 95
—— sarcoma of, with a microscopic section (H. R. Andrews) 210
—— squamous-celled epithelioma of the cervix of, in a very early stage (W. S. A. Griffith) 210
—— with fibroid tumour undergoing mucoid change, successfully removed by abdominal hysterectomy with intra-peritoneal treatment of the stump (A. H. N. Lewers) . 94
Vagina, myxo-sarcoma of, in a child aged two and a half years (A. W. W. Lea) 143
Vertebræ, spinal column exhibiting want of ossification in the interarticular portion of the lumbar (G. F. Blacker) . 90

Wilson (Thomas), relations of organic affections of the heart to fibro-myoma of the uterus 176
—— *Remarks* in reply 208

OBSTETRICAL SOCIETY.

ADDITIONS TO THE LIBRARY

BY DONATION OR PURCHASE DURING THE YEAR 1900.

	Presented by
Bayer (Josef). Ueber Zerreissungen des Nabelstranges und ihre Folgen für den Neugeborenen. ('Volkmann's Sammlung' klinischer Vorträge, neue Folge, Nr. 265.) 8vo. Leipzig, 1900	Purchased.
Bland-Sutton (J.) and Arthur E. Giles. The diseases of women: a handbook for students and practitioners. Second edition. *illust.*, sm. 8vo. Lond. 1900	Authors.
Catalogue of books added to the Radcliffe Library, Oxford University Museum, during the year 1899. 4to. Oxford, 1900	Sir Henry W. Acland.
——— of the anatomical and pathological preparations of Dr. Wm. Hunter in the Hunterian Museum, University of Glasgow, prepared by John H. Teacher, and published at the cost of the Bellahouston Trustees. Two volumes. 8vo. Glasgow, 1900	The Glasgow University Court.
Chazan (Samuel). Die specifischen Lebenserscheinungen im weiblichen Organismus. ('Volkmann's Sammlung' klinischer Vorträge, neue Folge, Nr. 269.)	Purchased.
Chrobak (R.) und A. von Rosthorn. Die Erkrankungen der weiblichen Geschlechtsorgane. Theil I, Hälfte 2. *illust.*, 8vo. Wien, 1900	Ditto.
Claisse (André). Recherches sur le développement des fibro-myomes et des adéno-myomes de l'utérus. 8vo. Paris, 1900	Ditto.

Presented by

CRAMER (Heinrich). Zur Mechanik und Physiologie der Nahrungsaufnahme der Neugeborenen. ('Volkmann's Sammlung' klinischer Vorträge, neue Folge, Nr. 263.) 8vo. Leipzig, 1900 — Purchased.

CRISTALLI (Giuseppe). Ricerche sulla presenza dello zucchero nelle orine delle doune gravide e puerpere. 8vo. Napoli, 1900 — Author.

CULLEN (Thomas Stephen). Cancer of the uterus: its pathology, symptomatology, diagnosis, and treatment; also the pathology of diseases of the endometrium. *illust.*, la. 8vo. Lond. 1900 — Purchased.

DALCHÉ (Paul). See *Robin* (Albert).

DANEL (M.). Essai sur les tumeurs malignes primitives de la trompe utérine. Thèse pour le doctorat en médecine, 1899. 8vo. Lille, 1899 — Ditto.

DOBBIN (George W.). The operative treatment of labor complicated by pelvic deformities, based upon a critical review of the first thousand patients delivered in the Obstetrical Department of the Johns Hopkins Hospital. [Reprinted from 'Obstetrics,' vol. i, No. 7, 1899.] — Dr. Whitridge Williams.

"Festschrift" in honour of Abraham Jacobi, M.D., LL.D., to commemorate the seventieth anniversary of his birth, May 6th, 1900. *illust.*, 8vo. New York, 1900 — Dr. Jacobi.

FREUND (Hermann W.). Die Beziehungen der weiblichen Geschlechtsorgane zu anderen Organen. ('Volkmann's Sammlung' klinischer Vorträge, neue Folge, Nr. 274.) 8vo. Leipzig, 1900 — Purchased.

FRITSCH (Heinrich). Die Krankheiten der Frauen, für Aerzte und Studirende dargestellt. Neunte, völlig erneute Auflage. *illust.*, 8vo. Braunschweig, 1900 — Ditto.

GALABIN (Alfred Lewis). A manual of midwifery. Fifth edition. *illust.*, 8vo. Lond., 1900 — Author.

GOTTSCHALK (Sigismund). Zur Aetiologie der Uterusorgane. ('Volkmann's Sammlung' klinischer Vorträge, neue Folge, Nr. 275.) — Purchased.

JACOBI (Abraham). See *Festschrift*.

KAHANE (Max). Die Chlorose (Vegetationsstörung der weiblichen Pubertätsperiode), für praktische Aerzte dargestellt. (Separat-Abdruck aus der 'Wiener Klinik,' 1900.) — Ditto.

Presented by

KEHRER (Erwin). Das Nebenhorn des doppelten Uterus. Dargestellt im Anschluss an 82 Fälle von Gravidität und 12 Fälle von Hämatometra. *illust.*, 8vo. Heidelberg, 1900 — Purchased.

KLEINWÄCHTER (Ludwig). Die mangelhafte Entwickelung des Uterus. [Reprinted from 'Wiener medizinische Presse,' Nr. 48, 1899.] — Author.

LOWNE (B. Thompson) and Maxwell T. MASTERS. Descriptive catalogue of the teratological series in the museum of the Royal College of Surgeons of England. Animal malformations, by B. Thompson Lowne, F.R.C.S.; vegetable malformations, by Maxwell T. Masters, F.R.S. 8vo. Lond. 1893 — Purchased.

MACNAUGHTON-JONES (H.). Practical manual of diseases of women and uterine therapeutics, for students and practitioners. Eighth edition, revised and enlarged. *illust.*, 8vo. Lond. 1900 — Author.

MACREZ (Paul). Des tumeurs papillaires de la trompe de Fallope. (Thèse pour le doctorat en médecine, 1899.) 8vo. Paris, 1899 — Purchased.

MASTERS (Maxwell T.). See *Lowne* (B. Thompson).

MÉRIC (H. de). Dictionary of medical terms, English-French and French-English. Two vols. 8vo. Lond. 1899 — Ditto.

MINOT (Charles Sedgwick). On the solid stage of the large intestine in the chick, with a note on the ganglion coli. [Reprinted from the 'Journal of the Boston Society of Medical Sciences,' vol. iv, pp. 153—164, March, 1900.] — Author.

MONTANA (E.). Les opérations conservatrices de l'ovaire et de la trompe. Résultats éloignés. 8vo. Paris, 1900 — Purchased.

OLIVER (James). On the physico-chemical changes concerned in the production of version of the uterus. [Reprinted from the 'Medical Press and Circular,' November 29th, 1899.]

ORTHMANN (E. G.). Vademecum für histopathologische Untersuchungen in der Gynäkologie. Für Aerzte und Studirende. *illust.*, 8vo. Berl. 1901 — Ditto.

Presented by

Pfannenstiel (J.). Ueber die Vortheile des supra-symphysären Fascienquerschnitts für die gynäkologischen Koeliotomieen, zugleich ein Beitrag zu der Indikationsstellung der Operationswege. ('Volkmann's Sammlung,' neue Folge, Nr. 268.) 8vo. Leipzig, 1900 — Purchased.

Pick (Ludwig). Ueber das elastische Gewebe in der normalen und pathologisch veränderten Gebärmutter. ('Volkmann's Sammlung' klinischer Vorträge, neue Folge, Nr. 283.) — Ditto.

Pincus (Ludwig). Die erste Sammelforschung und Weiteres zur Atmokausis und Zestokausis. ('Volkmann's Sammlung,' neue Folge, Nr. 261, 262.) 8vo. Leipzig, 1899 — Ditto.

Piskaček (L.). Ueber Ausladungen umschriebener Gebärmutterabschnitte als diagnostisches Zeichen im Anfangsstadium der Schwangerschaft. *illust.*, 8vo. Wien u. Leipzig, 1899 — Ditto.

Pryor (W. R.). The treatment of pelvic inflammations through the vagina. *illust.*, 8vo. Lond. and Phila. 1899 — Ditto.

Richardson (Benjamin Ward). Biological experimentation: its functions and limits; including answers to nine questions submitted from the Leigh-Browne Trust. 8vo. Lond. 1896 — The Leigh-Browne Trust.

Robin (Albert) and Paul Dalché. Traitement médical des maladies des femmes. 8vo. Paris, 1900 — Purchased.

Robinski (Severin). Operiren oder Nichtoperiren bei Krebs-Erkrankungen und andere zeitgemässe, insbesondere therapeutische Fragen. 8vo. Berl. 1898 — Author.

Royal College of Surgeons of England. Descriptive Catalogue of the teratological series in the museum. Animal malformations, by B. Thompson Lowne; vegetable malformations, by Maxwell T. Masters. 8vo. Lond. 1893 — Purchased.

Ruge (C.) und J. Veit. Der Krebs der Gebärmutter. *illust.*, 8vo. Stuttgart, 1881 — Ditto.

Schultze (B. S.). Dammschutz. ('Volkmann's Sammlung' klinischer Vorträge, neue Folge, Nr. 278.) 8vo. Leipzig, 1900 — Ditto.

Presented by

Seitz (Ludwig). Ueberzählige und accessorische Ovarien. ('Volkmann's Sammlung' klinischer Vorträge, neue Folge, Nr. 286.)
8vo. Leipzig, 1900 Purchased.

——— (Otto). Ueber primäres Scheidensarkom Erwachsener (Lymphendothelioma). ('Volkmann's Sammlung' klinischer Vorträge, neue Folge, Nr. 280.) 8vo. Leipzig, 1900 Ditto.

Sellheim (Hugo). Topographischer Atlas normalen und pathologischen Anatomie weiblichen Beckens. Sechzig Tafeln mit einem Textheft.
Leipzig, 1900 Ditto.

Smith (Heywood). Practical gynæcology: a handbook of the diseases of women. Second edition, revised and enlarged. *illust.*, sm. 8vo. Lond. 1900 Author.

Stoeckel (W.). Ureterfisteln und Ureterverletzungen.
8vo. Leipzig, 1900 Purchased.

Sturmer (A. J.). Ectopic gestation: a series of eight cases treated by abdominal section. [Reprinted from the 'Indian Medical Gazette,' vol. xxxv, Nos. 1, 2, 3, and 4, 1900.] Author.

Temesváry (Rudolf). Volksbräuche und Aberglauben in der Geburtshilfe und der Pflege des Neugebornen in Ungarn. Ethnographische Studien.
illust., 8vo. Leipzig, 1900 Purchased.

Thompson (Peter). The myology of the pelvic floor: a contribution to human and comparative anatomy.
illust., sm. 4to. Lond. 1899 Author.

Varnier (Henri). La pratique des accouchements. Obstétrique journalière (duplicate copy).
illust., la. 8vo. Paris, 1900 Ditto.

Volkmann's Sammlung klinischer Vorträge, neue Folge:

261, 262. *Pincus*, Die erste Sammelforschung und weiteres zur Atmokausis und Zestokausis.
263. *Cramer*, Zur Mechanik und Physiologie der Nahrungsaufnahme der Neugeborenen.
265. *Bayer*, Ueber Zerreissungen des Nabelstranges und ihre Folgen für den Neugeborenen.
268. *Pfannenstiel*, Ueber die Vortheile des suprasymphysären Fascienquerschnitts für die gynäkologischen Koeliotomieen, zugleich ein Beitrag zu der Indikationsstellung der Operationswege.
269. *Chazan*, Die specifischen Lebenserscheinungen im weiblichen Organismus.

Presented by

VOLKMANN'S Sammlung, *continued:*

274. *Freund,* Die Beziehungen der weiblichen Geschlechtsorgane zu anderen Organen.
275. *Gottschalk,* Zur Aetiologie der Uterusorgane.
277. *von Strauch,* Das Myom in der Fortpflanzungsperiode.
278. *Schultze,* Dammschutz.
280. *Seitz,* Ueber primäres Scheidensarkom Erwachsener (Lymphendothelioma).
283. *Pick,* Ueber das elastische Gewebe in der normalen uud pathologischveränderten Gebärmutter.
286. *Seitz,* Ueberzählige und accessorische Ovarien.

VON STRAUCH (M.). Das Myom in der Fortpflanzungsperiode. ('Volkmann's Sammlung' klinischer Vorträge, neue Folge, Nr. 277.) Purchased.

WILLIAMS (J. Whitbridge). The frequency of contracted pelves in the first thousand women delivered in the Obstetrical Department of the Johns Hopkins Hospital. [Reprinted from 'Obstetrics,' vol. i, Nos. 5 and 6, 1899.] Author.

WILMS (M.). Die Mischgeschwülste.

Heft 1. Die Mischgeschwülste der Niere.
Heft 2. Die Mischgeschwülste der Vagina und der Cervix uteri (traubige Sarkome). Anhang: Mischgeschwülste der Blase und des Vas deferens.

8vo. Leipzig, 1899 and 1900 Purchased.

TRANSACTIONS.

AMERICAN ASSOCIATION OF OBSTETRICIANS AND GYNECOLOGISTS—
Transactions, vol. xii, for 1899. 8vo. Philad. 1900 Association.

AMERICAN GYNECOLOGICAL SOCIETY—
Transactions, vol. xxiv, for 1899.
8vo. Philad. 1899 Society.

CLINICAL SOCIETY OF LONDON—
Transactions, vols. xxxii and xxxiii.
8vo. Lond. 1899, 1900 Ditto.

COLLEGE OF PHYSICIANS OF PHILADELPHIA—
Transactions of the section on gynecology, vol. v, 1899. [Reprinted from the 'American Journal of Obstetrics.'] College.

Presented by

DET KJOBENHAVNSKE MEDICINSKE SELSKABS—
Forhandlinger, 1899–1900.
8vo. Copenhagen, 1900 Society.

MEDICAL (ROYAL) AND CHIRURGICAL SOCIETY—
Transactions, vol. lxxxiii. 8vo. Lond. 1900 Ditto.

MEDICAL SOCIETY OF LONDON—
Transactions, vol. xxiii. 8vo. Lond. 1900 Ditto.

OBSTETRICAL SOCIETY (EDINBURGH)—
Transactions, Session 1896–7, vol. xxii.
8vo. Edin. 1897 Ditto.

——— ——— Session 1899–1900, vol. xxv.
8vo. Edin. 1900 Ditto.

OBSTETRICAL SOCIETY (NEW YORK)—
Transactions, from October, 1898, to October, 1999, with complete index. 8vo. New York, 1899 Ditto.

SOCIÉTÉ DE MÉDECINE DE ROUEN—
Bulletin, 2e série, vol. xii, 37e année, 1898.
8vo. Rouen, 1899 Ditto.

——— ——— 2e série, vol. xiii, 38e année, 1899.
8vo. Rouen, 1900 Ditto.

SOCIÉTÉ DES SCIENCES MÉDICALES DE LYON—
Mémoires et comptes-rendus, tome xxxviii, 1898.
8vo. Lyons, 1899 Ditto.

REPORTS.

AMERICA—HOSPITALS—Boston Lying-in Hospital: the 67th year, for 1899. 8vo. Boston, 1899 Hospital Staff.

——— ——— Medical and Surgical Report of the Presbyterian Hospital in the City of New York, vol. iv, January, 1900, edited by Andrew J. McCosh, M.D., and W. Gilman Thompson, M.D. 8vo. New York, 1900 Ditto.

——— ——— The Society of the New York Hospital. Annual Report for the year 1899.
8vo. New York, 1900 Society.

HOSPITALS—Guy's Hospital Reports, Third Series, vol. xxxix. 8vo. Lond. 1900 Ditto.

		Presented by
Hospitals—St. Bartholomew's Hospital Reports, vol. xxxv.	8vo. Lond. 1899	Hospital Staff.
——— St. Thomas's Hospital Reports, New Series, vol. xxvii.	8vo. Lond. 1898	Ditto.
——— Annual Report of the Government Maternity Hospital, Madras, for the year 1899.	la. 8vo. Madras, 1900	Ditto.
Jahresbericht über die Forthscritte auf dem Gebiete der Geburtshilfe und Gynäkologie, herausgegeben von Richard Frommel, xii Jahrgang, 1898.	8vo. Wiesbaden, 1899	Dr. Frommel.
——— xiii Jahrgang, 1900.	8vo. Wiesbaden, 1900	Ditto.
Jahresbericht der Gesellschaft für Natur- und Heilkunde in Dresden. Sitzungsperiode 1898–9.	8vo. Dresden, 1899	Society

PRINTED BY ADLARD AND SON, BARTHOLOMEW CLOSE, LONDON, E.C.

SERIAL

RG
1
C3
v.42

Obstetrical Society of London
Transactions

GERSTS